

# Mogućnosti uporabe mini dentalnih implantata za retenciju djelomičnih proteza Kennedy klasa I i II

---

**Disha, Visar**

**Doctoral thesis / Disertacija**

**2021**

*Degree Grantor / Ustanova koja je dodijelila akademski / stručni stupanj:* **University of Zagreb, School of Dental Medicine / Sveučilište u Zagrebu, Stomatološki fakultet**

*Permanent link / Trajna poveznica:* <https://urn.nsk.hr/urn:nbn:hr:127:094967>

*Rights / Prava:* [Attribution-NonCommercial 4.0 International](#)/[Imenovanje-Nekomercijalno 4.0 međunarodna](#)

*Download date / Datum preuzimanja:* **2024-04-20**



*Repository / Repozitorij:*

[University of Zagreb School of Dental Medicine Repository](#)





University of Zagreb

School of Dental Medicine

Visar Disha

**Possibilities of using mini dental implants  
for retention of removable partial dentures  
in Kennedy Class I and II**

DOCTORAL DISSERTATION

Zagreb, 2019.



University of Zagreb  
School of Dental Medicine

Visar Disha

**Possibilities of using mini dental implants  
for retention of removable partial dentures  
in Kennedy Class I and II**

DOCTORAL DISSERTATION

Mentors:

Assist. Prof. Sanja Peršić Kiršić, PhD

Assoc. Prof. Ksenija Rener – Sitar, MSc, PhD

Zagreb, 2019.



Sveučilište u Zagrebu

Stomatološki fakultet

Visar Disha

**Mogućnosti uporabe mini dentalnih  
implantata za retenciju djelomičnih proteza  
Kennedy klasa I i II**

DOKTORSKI RAD

Zagreb, 2019.

Rad je ostvaren na Stomatološkom fakultetu Sveučilišta u Zagrebu na Zavodu za Mobilnu protetiku

Naziv, oznaka i voditelj projekta u okviru kojeg je istraživanje obavljeno: Projekt Hrvatske zaklade za znanost “Definiranje mogućnosti uporabe mini dentalnih implantata (MDI) i njihovi rezultati u in vitro i u kliničkim prospektivnim istraživanjima” (“Defining the possibility of using mini dental implants (MDI) and their results in vitro and in clinical prospective studies”) (IP-2014-09-1218), prof.dr.sc. Asja Čelebić

**Lektor hrvatskog jezika:** Marija Gazzari, profesor hrvatskog jezika

**Lektor engleskog jezika:**

**Sastav Povjerenstva za ocjenu doktorskog rada:**

(za svakog člana Povjerenstva naknadno se rukom na za to predviđeno mjesto upisuju ime i prezime, akademsko zvanje i ustanova)

1. Irina Filipović Zore, Full professor
2. Robert Čelić, Associate professor
3. Asja Čelebić, Full professor
4. Davor Illeš, Asistant Professor
5. Renata Poljak-Guberina, Asistant Professor

**Sastav Povjerenstva za obranu doktorskog rada:** (za svakog člana Povjerenstva naknadno se rukom na za to predviđeno

mjesto upisuju ime i prezime, akademsko zvanje i ustanova)

1. Irina Filipović Zore, Full professor
2. Robert Čelić, Associate professor
3. Asja Čelebić, Full professor
4. Davor Illeš, Asistant Professor
5. Renata Poljak-Guberina, Asistant Professor

**Datum obrane rada:** 27.01.2020 (upisuje se naknadno rukom)

Rad sadrži: 123 stranica (upisati broj)

19 tablica (upisati broj)

39 slika (upisati broj)

CD

Rad je vlastito autorsko djelo, koje je u potpunosti samostalno napisano uz naznaku izvora drugih autora i dokumenata korištenih u radu. Osim ako nije drukčije navedeno, sve ilustracije (tablice, slike i dr.) u radu su izvorni doprinos autora poslijediplomskog specijalističkog rada. Autor je odgovoran za pribavljanje dopuštenja za korištenje ilustracija koje nisu njegov izvorni doprinos, kao i za sve eventualne posljedice koje mogu nastati zbog nedopuštenog preuzimanja ilustracija odnosno propusta u navođenju njihovog podrijetla.

## **Acknowledgments**

This doctoral thesis has been a great challenge for me. It would not be possible without the support and guidance that I received from many people.

To commence with, I would like to express my sincere gratitude to my mentor Prof. Sanja Persic for continuous support during my Ph.D. study and related research; for her patience, motivation, and vast knowledge. I was followed everywhere by her guidance, which helped me overcome the obstacles that I encountered during the research and writing of the thesis. In other words, I could not wish for a better advisor and mentor for my study.

Besides my first mentor, I would like to thank my second mentor: Prof. Ksenija Rener-Sitar, for her advice, comments, and encouragement for critical thinking, especially for the part of the study, which involved patient-reported outcome measures. She helped to improve my doctoral thesis from various perspectives.

My sincere thanks also go to Prof Asja Celebic, for enlightening me at first glance of research and who provided me with an opportunity to join her research project. I received a great deal of support and assistance in both research and clinical guidance by Prof. Asja Celebic. Without her extensive support, it would not be possible to perform this research. I am grateful to professor Celebic, as she raised my confidence, and she never left me aside through this journey of my Ph.D. study. I feel very privileged to be associated with a person like her in my life.

Last but not the least, I would like to thank my family, especially my parents Prof. Muhamed Disha and Prof. Emine Disha, for supporting me spiritually and financially throughout my undergraduate and graduate dental studies, as well as through my residency program, and in my life in general.

Thus, I dedicate this doctoral thesis to my father and mother. Thanks for all your encouragement!

Finally, yet importantly, I wish to thank the Croatian Science Foundation for all expenses they covered, including the costs of mini-implants.

## Prošireni sažetak:

**Uvod:** U rezultatima objavljenih kliničkih istraživanja opisano je da djelomične mobilne proteze retinirane na zubnim implantatima standardnih dimenzija (I-RPD) poboljšavaju funkciju žvakanja i zadovoljstvo pacijenata, a također se usporava i resorpcija rezidualnih grebena u distalnim područjima ležišta proteze, u usporedbi s konvencionalnim djelomičnim mobilnim protezama. Međutim, ako pacijent nosi konvencionalnu djelomičnu mobilnu protezu duže vrijeme, često dolazi do atrofije rezidualnih alveolarnih grebena, koji postaju preuski za ugradnju implantata standardne veličine. Takvim pacijentima moguće je bez postupaka augmentacije jedino ugraditi uske implantate. Mini implantati su uski jednodijelni implantati 1,8 do 2,5 mm širine, a standardne dužine, namijenjeni za uske grebene. Prospektivna kratkoročna i dugoročna klinička istraživanja pokazala su kako je ugradnja mini implantata (MDI) za retenciju donje potpune proteze u mandibuli jako dobar terapijski postupak za rješavanje problema potpune bezubosti u bezubih pacijenata s uskim grebenima. No, u dentalnoj literaturi nema dokumentiranih istraživanja o retenciji djelomične mobilne proteze pomoću mini implantata. Nije poznato mogu li se mini implantati koristiti za retenciju djelomične proteze kod pacijenata bez stražnjih zuba, a koji imaju uske grebene.

**Svrha:** Cilj je rada istražiti mogu li se jednodijelni uski implantati (MDI) koristiti za retenciju mobilnih djelomičnih proteza kod pacijenata Kennedy klase I ili II koji nemaju niti jedan stražnji zub u čeljusti (bilateralno ili unilateralno), a čiji promjer alveolarnog grebena u bezubom području iznosi  $\leq 4,5$  mm. Cilj je bio procijeniti neke kliničke parametre: iznos marginalnog gubitka kosti (MGK) na mezijalnim i distalnim stranama MDI-ja tijekom korištenja (dvije godine), postotak uspješnosti i preživljavanja MDI-ja te uspješnost i efekt terapije temeljem podataka iz perspektive pacijenata. Svrha je bila odrediti kako pacijenti doživljavaju estetiku, žvačnu funkciju i kvalitetu života ovisnu o oralnom zdravlju nakon učinjene terapije, kakav je učinak terapije i mijenja li se tijekom praćenja. Svrha je bila i usporediti MGK između mezijalne i distalne strane MDI-ja te između MDI-ja inseriranih na lijevoj i na desnoj strani čeljusti. Željelo se ispitati i utjecaj spola, dobi, čeljusti u koju se MDI-ji ugrađuju te statusa antagonističke čeljusti na iznos MGK-a, zatim procijeniti parametre poput modificiranog plak indeksa (MPI) i modificiranog indeksa krvarenja (MBI) te koji su tehnički problemi s protezom (lom, gubitak retencije, žuljanje, potreba podlaganja i slično) u funkciji tijekom dvije godine.



**Materijal i metode:** Kako bi se postigli ciljevi, prvo su kirurški ugrađeni MDI-ji (bez podizanja mukoperiostalnog režnja) kod pacijenata koji su imali uske grebene i samo prednje prirodne zube. MDI-ji su ugrađeni na mjestima gdje su prije bili očnjaci ili prvi premolari. MDI-ji su opterećeni novim djelomičnim mobilnim protezama rano ili kasno, ovisno o sili očitanoj na moment ključu prilikom ugradnje. Nove djelomične mobilne proteze bile su ojačane metalnim skeletom te su u njih ugrađene matrice (koje u sebi imaju gumeni O-prsten). Pacijenti su praćeni tijekom dvije godine u prospektivnoj kliničkoj studiji. Gubitak marginalne kosti mjeren je na mezijalnoj i distalnoj strani svakog MDI-ja na sukcesivnim standardiziranim intraoralnim rtg snimkama i ortopantomogramima nakon jedne i dvije godine nošenja proteza. Procijenjene su stope preživljavanja i uspjeha MDI-ja. Procijenjeni su modificirani plak indeks (MPI) i modificirani indeks krvarenja (MBI). Mjere ishoda prema procjeni pacijenata (dPROM) zabilježene su korištenjem tri strukturirana upitnika: orofacijalne estetske skale (OES), upitnika za procjenu kvalitete života ovisne o oralnom zdravlju (OHIP-14) i upitnika za procjenu funkcije žvakanja (CFQ). Izračunata je veličina učinka tretmana koja je praćena tijekom dvije godine. Registrirane su i tehničke komplikacije s protezama i s prirodnim pacijentovim zubima (parodontitis, karijes, gubitak zuba, itd.). Statistička analiza uključila je izračun veličine uzorka prije početka istraživanja prema primarnom ishodu: MGK, deskriptivnu statistiku, jednosmjerni Kolmogorov-Smirnov test za testiranje normalnosti distribucije,  $X^2$  test za kategorijalne varijable, zavisne i nezavisne t-testove, jednosmjernu analizu varijance, višefaktorsku analizu varijance, „repeated measurements“ za testiranje važnosti razlike između aritmetičkih sredina više zavisnih uzoraka, a napravljene su i krivulje preživljavanja (life tables).

**Rezultati:** Sudjelovalo je ukupno 84 pacijenata (66 žena i 18 muškaraca, u dobi od 51 do 83 godine) koji su imali Kennedy klasu I (pacijenti bez stražnjih zuba: molara i premolara) i 14 pacijenata Kennedy klase II (11 žena, 3 muškarca, 52-80 godine; 8 MDI-ja ugrađeno je u mandibulu, a 6 u maksilu). Svakom je pacijentu mini implantat (Dentium, Južna Koreja; 2,0 ili 2,5 mm širine; 10, 12 ili 14 mm dužine) ugrađen jedan ili dva zuba distalnije u odnosu na zadnji prednji prirodni zub, za retenciju nove djelomične mobilne proteze. Većini pacijenata Kennedy klase I ugrađeni su MDI-ji u mandibuli (57 pacijenata), dok je 27 pacijenata dobilo MDI-je u maksili. Nakon jedne godine četiri pacijenta Kennedy klase I nisu bila dostupna te je pregledan 81 pacijent. Četiri MDI-ja ispala su ubrzo nakon opterećenja; dva u maksili i dva u mandibuli (kod četiri različita pacijenta). Izgubljeni MDI-ji nisu zamijenjeni novima; žičane kvačice ugrađene su u postojeće proteze. Niti jedan MDI nije izgubljen nakon toga. U

pacijenata Kennedy klase I, na razini implantata (kod 81 pacijenta koji su se odazvali), uspjeh i preživljavanje iznosili su 95,3% nakon prve godine u funkciji. Nakon dvije godine stopa preživljenja iznosila je 93,4%, a stopa uspješnosti 91,8% (kod 61 pacijenta koji su bili dostupni na kontrolnom pregledu). Najčešći stupanj MBI-ja i MPI-ja bio je 1 i prilikom jednogodišnjeg i dvogodišnjeg kontrolnog pregleda. Međutim, oralna higijena značajno se pogoršala tijekom druge godine. Prosječne vrijednosti marginalnog gubitka kosti oko mini implantata u prvoj godini iznosile su  $0,23 \pm 0,35$  mm, a u drugoj godini  $0,12 \pm 0,18$  mm; ukupan iznos MGK-a iznosio je  $0,30 \pm 0,47$  mm nakon dvije godine. Na iznos MGK-a utjecala je samo dob pacijenata (veći iznos MGK-a zabilježen je kod mlađih pacijenata), dok spol, čeljust insercije i status antagonističke čeljusti nisu imali značajan utjecaj. Nije bilo razlika u MGK-u između mezijalne i distalne strane ili između lijevog i desnog MDI-ja. Svi strukturirani upitnici za procjenu podataka iz perspektive pacijenata pokazali su velik učinak terapije. Ti rezultati ostali su nepromijenjeni tijekom dvije godine praćenja za estetiku, žvačnu funkciju i za kvalitetu života ovisnu o oralnom zdravlju. Registrirani su samo manji popravci proteza, a nije bilo lomova. Pacijenti Kennedy klase II pokazali su slične vrijednosti MGK-a kao i pacijenti Kennedy klase I. Kod njih nije zabilježen niti jedan gubitak mini implantata.

**Zaključci:** Temeljem rezultata ovog istraživanja, ugradnja mini implantata za retenciju djelomične mobilne proteze može se preporučiti kao uspješna metoda liječenja kod pacijenata s uskim grebenima. MGK je malen, manji u drugoj godini, a uspješnost i preživljenje MDI-ja velike.

**Ključne riječi:** mini implantati, mobilna djelomična proteza, prospektivna klinička studija, marginalni gubitak kosti, preživljavanje i uspjeh MDI-ja, modificirani plak indeks, modificirani indeks krvarenja, orofacijalna estetika, žvakanje, OHRQoL, tehničke komplikacije proteze.

**Abstract:** Clinical studies of mini-dental implants (MDIs) used for retention of removable partial dentures (RPDs) in patients without posterior teeth have not been reported yet. The aim of this thesis was to prospectively explore whether MDIs can be used for retention of RPDs in Kennedy Class I and Class II patients without posterior teeth with narrow alveolar ridges ( $\leq 4.5$  mm). MDIs were inserted without raising a flap in previous canine or first premolar sites. All studied patients received the new RPDs. The MDIs were early or late loaded. Marginal bone loss (MBL) was measured on the follow-up intraoral radiographs. The MDI survival- and success rates, the Modified Plaque Index (MPI), and the modified Bleeding Index (MBI) were assessed. The dental patient-reported outcome measures (dPROMs) were recorded using: the Orofacial Esthetic Scale (OES), the 14-item Oral Health Impact Profile (OHIP-14), and the Chewing Function Questionnaire (CFQ). All technical complications with RPDs during the observation period have been registered. Statistical analysis comprised sample size calculation, descriptive statistics, Kolmogorov-Smirnov test,  $\chi^2$  test, Student's t-tests, one-way ANOVA, ANCOVA, repeated measures, effect size calculation, and survival curves. A total of 84 Kennedy Class I patients were included (78.6% females; mean age  $66.0 \pm 7.6$  years). Of this, 57 received MDIs in the mandible and 27 in the maxilla. During the first year, four MDIs were lost shortly after loading. Two MDIs were lost in the maxilla, two in the mandible (in four different patients). None of the MDIs was lost afterward. At the implant level (in 81 patients) both, the success and the survival rates were 95.3% after one year. At the 2-year recall, the survival rate was 93.4%, and the success rate 91.8% (assessed in 61 patients). The MBI and MPI medians equaled one; however, oral hygiene worsened significantly during the 2<sup>nd</sup> year. Mean 1<sup>st</sup> year MBL was  $0.23 \pm 0.35$  mm and  $0.12 \pm 0.18$  mm during the 2<sup>nd</sup> year, but it raised to  $0.30 \pm 0.47$  mm after two years. Only age had significant effect on MBL, whereas gender, the target jaw for implant insertion, and the dental status of the antagonistic jaw did not influence the MBI. All dPROMs showed large effect size, which remained unchanged throughout the two years. Kennedy class II patients (11 females, three males, 52-80 years old, 8 MDIs in the mandible, 6 in the maxilla) showed similar rates of MBL as Kennedy Class I patients, and none of the MDIs were lost. Within the limitations of this study, the MDI-RPD was a successful treatment option in Kennedy Class I and II patients, with narrow ridges, at least in the first two years after implant-prosthetic rehabilitation.

**Keywords:** mini-implants, removable partial denture, prospective clinical study, marginal bone level, survival, success, modified plaque index, modified bleeding index, orofacial esthetics, chewing, OHRQoL

## Table of Contents

|  |    |
|--|----|
| 1. INTRODUCTION.....   | 1  |
| 1.1. Tooth loss and bone atrophy.....  | 2  |
| 1.2. Osseointegration.....   | 4  |
| 1.3. Bone quality.....   | 6  |
| 1.4. Dental implant dimensions.....  | 6  |
| 1.5. Mini-dental implants.....   | 7  |
| 1.6. Contraindications for MDI placement.....  | 10 |
| 1.7. MDI Placement protocol.....   | 11 |
| 1.8. Indications for mini-dental implants approved by the ITI Consensus statement..... | 13 |
| 1.9. MDIs and clinical data.....   | 14 |
| 1.10. Implant assisted and/or Implant-retained removable partial dentures.....         | 15 |
| 2. AIMS OF THE STUDY.....  | 19 |
| 3. MATERIALS AND METHODS.....  | 21 |
| 3.1. Sample size.....  | 22 |
| 3.2. Patient selection.....  | 23 |
| 3.2.1. <i>Surgical protocol: MDI insertion</i> .....                                   | 26 |
| 3.3. Prosthodontic protocol: RPD design.....   | 30 |
| 3.4. Clinical parameters of the mini-dental implants.....                              | 31 |
| 3.5. Radiographic parameter assessment.....  | 31 |
| 3.6. Implant success and survival criteria.....  | 33 |
| 3.7. Dental patient-reported outcome measures (dPROMs).....                            | 34 |
| 3.8. Statistical analysis.....   | 37 |
| 4. RESULTS.....  | 39 |
| 4.1 Radiological data on the marginal bone level.....                                  | 40 |
| 4.2 Success and survival rates.....  | 65 |
| 4.3 Dental patient-reported outcome measures (dPROMs): OHRQoL, OES, CFQ.....           | 69 |

|  |     |
|--|-----|
| 4.3.1. <i>The effect size of a treatment</i> .....   | 69  |
| 4.3.2 <i>Changes of Patients' reported outcome measures throughout observation: OES, OHRQoL, and CFQ</i> ..... | 72  |
| 4.4. Prosthodontic maintenance .....   | 76  |
| 5. DISCUSSION .....  | 78  |
| 5.1 Marginal bone loss, success, and survival of MDIs .....  | 82  |
| 5.2. Oral hygiene outcomes.....  | 85  |
| 5.3. Prosthodontic maintenance .....   | 86  |
| 5.4. Patient-reported outcome measures.....  | 86  |
| 5.6. Study limitation .....  | 88  |
| 5.7. Final observations .....  | 89  |
| 6. CONCLUSIONS.....  | 90  |
| 7. REFERENCES.....   | 92  |
| 8. BIOGRAPHY.....  | 108 |

**Abbreviations:**

|               |   |
|---------------|---|
| <b>CD</b>     | complete dentures                       |
| <b>RPD</b>    | removable partial dentures              |
| <b>FPD</b>    | fixed partial denture                   |
| <b>ITI</b>    | international team of implantology      |
| <b>QoL</b>    | quality of life                         |
| <b>SSI</b>    | standard size dental implants           |
| <b>MDI</b>    | mini dental implant                     |
| <b>MPI</b>    | modified plaque index                   |
| <b>MBI</b>    | modified bleeding index                 |
| <b>CBCT</b>   | cone-beam computed tomography           |
| <b>OHRQoL</b> | oral health-related quality of life     |
| <b>dPROM</b>  | dental patient-reported outcome measure |
| <b>MBL</b>    | marginal bone loss                      |
| <b>CFQ</b>    | chewing function questionnaire          |
| <b>OES</b>    | orofacial esthetic scale                |
| <b>SD</b>     | standard deviation                      |
| <b>SE</b>     | standard error                          |

## 1. INTRODUCTION

### ***1.1. Tooth loss and bone atrophy***

In the past, before the invention of dental implants, removable complete dentures (CD) and removable partial dentures (RPDs) had been the only treatment options for complete or partially edentulous individuals. RPDs and CDs still present the only available treatment option for most of the complete or partially edentulous population due to the low cost even though removable dentures may cause many difficulties for patients. The lack of stability and retention is the most critical issue, so many people cannot chew hard or high-fiber food, and sometimes the dentures move when in function, which can cause pain, food impaction, and many other problems in a social context related to removable denture wearing. Most problems occur with the mandibular CD, because of mandibular bone atrophy and the consequent small surface of a denture bearing area, as well as because of active denture surrounding tissues and organs, such as the tongue, cheeks, and lips, which move according to the chewing muscles activity. Even those denture-wearers who can wear maxillary removable dentures without any problem often have difficulties eating with the lower denture (1).

Dental implants and implant-retained overdentures provide better retention than conventional CDs and substantially reduce difficulties associated with oral function. It has been shown that dental implants also significantly reduce the bone loss activity, not only in peri-implant bone, but implants also reduce residual ridge atrophy in distal areas, they minimize denture instability, pain, and sore spots, leading to improved masticatory efficiency (2). Apart from the listed improvements, several investigations have also shown the positive impact of implant support/retention on psychosocial parameters, speech ability, self-esteem, denture satisfaction, and improvement of oral health-related quality of life (OHRQoL) (3,4).

It is predicted that the ratio of partially edentulous patients will increase with aging populations (5). In Germany, most individuals with reduced dentition demand and receive RPDs that are either retained by double crowns, clasps, ball- or other precision attachments (6). The longevity of the remaining teeth and RPDs depends on the number and localization of the abutments, as shown in some studies (7). According to epidemiological studies, the lower is the number of the remaining teeth higher is the incidence of further tooth loss (8). From the clinical point of view, symmetrical support by the abutment teeth is suggested, regardless of the attachment system used (9).



Placement of supplementary implants in strategic positions in partially edentulous patients can ensure a change from critical prosthetic support (e.g., unilateral, linear) to a more favorable support configuration, such as triangular or polygonal (10). Retention and stability of RPDs are better when abutments are positioned in strategically important areas, such as canine and posterior teeth sites in both quadrants of the jaw (11). This treatment strategy protects the remaining teeth from overload and reduces possible rotational movements of the RPD (11). When an incisor, a canine, or first premolar is the terminal tooth/abutment in the quadrant, inserting a distal implant can reduce the need for retentive elements such as clasps. Implant placement also provides better aesthetics and better periodontal stability of the most distal remaining anterior tooth (12).

Natural teeth enable chewing of all kinds of food and normal speech. Moreover, natural teeth provide support to lip and cheek muscles and thus enabling physiological tonus to the facial muscles contributing to facial aesthetics. After tooth loss, morphological and functional changes and disorders in the stomatognathic system occur. Impacts after the loss of some or all teeth vary from patient to patient, depending mainly on how many teeth a person has lost. The changes after tooth/teeth extractions present intraorally and extraorally. In the case of complete loss of teeth, the changes involve the atrophy of residual alveolar bone. Its height and width reduce significantly, especially in the first year after tooth extraction.

Bone resorption in edentulous patients is a chronic, progressive, and irreversible process. One-third of the alveoli is being absorbed within the first three months after tooth extraction, while the remaining two-thirds ossify, and the bone tissue consolidation process ends after four to six months. However, the bone atrophy does not stop, but it progresses either due to the disuse of the tissue or due to overloads and injuries of unstable removable dentures. Bone resorption takes place in horizontal and vertical directions, but the course and direction of the resorption are generally different for the upper and the lower jaw due to different shapes and various locations of the dense compact (cortical) bone.

The direction of bone atrophy of the maxilla versus the mandible differs specifically in the horizontal plane. The maxilla usually shows a higher rate of bone resorption buccally than lingually (bone atrophy starts from the buccal towards the lingual side), due to a thin buccal cortical plate and thick palatal cortical plate. Mandibular bone shows a different resorption pattern, which is directed from the lingual cortical plate towards the buccal plate (which is more abundant in the mandible than in the maxilla). It has also been shown that vertical bone

loss in edentulous persons is four times higher in the mandible than in the maxilla (13). The number of partially edentulous adults is increasing in many populations because of the increased retention of natural teeth in older adults (14, 15). When all posterior teeth are lost, it is challenging to impossible to construct a fixed partial denture on remaining natural teeth with distal extensions. In this context, oral rehabilitation with RPDs was the only conservative treatment to meet functional and esthetic needs until osseointegrated dental implants offer a new possibility to construct an implant-retained fixed partial denture (I-FPD; 16).

Unfortunately, high costs have often placed dental implants out of reach for most of the people in need of them to receive treatment with implant-retained FPD in posterior areas of a jaw. A minimum of four implants is usually recommended (two or more implants need to be inserted in each side of a jaw) for retention of the FPD.

## ***1.2. Osseointegration***

The definition of osseointegration is “the formation of a direct interface between the bone and the implant, without any involvement of soft tissue“ (1).

During the process of osseointegration, migration of osteoblasts and supporting connective tissue occur into the pores on the rough surface of endosteal implants. In other words, this refers to the bone growth onto the surface of the implant without any soft tissue layer being interposed. There is no presence of cartilage, scar tissue, or any fibrillar ligaments between the implant surface and the bone. One can verify this contact microscopically (17).

A titanium piece was utilized during an experiment by Brånemark in 1952 when he studied the blood flow in the rabbit bone. To summarize, at the end of the experiment, when Brånemark tried to remove the titanium piece from the bone, he understood that there was an integration of the bone with that titanium object. Thus, the titanium piece could not be removed. Brånemark named that phenomenon "osseointegration."

For osseointegrated dental implants, several materials have been used, mostly pure titanium. For osseointegration to occur, the connection between the bone and the implant does not need to be 100%. The stability of fixation plays a more critical role than the degree of histological contact. As a conclusion, asymptotically clinical rigid fixation of an implant material is achieved and maintained in the bone, which does not change during functional loading. For

instance, screw-root-form shaped implants achieve increased mechanical stability by the action of the screw against the bone. After implant placement, healing usually lasts for weeks or several months before there is a full integration of the implant into the bone. We can observe the first proof of integration to occur after a few weeks, while a more robust connection is progressively achieved over the next months or years. Implants that possess a screw-root form design, as well as dental implants with parallel walls, result in bone resorption after insertion, followed by interfacial bone remodeling, and bone growth around and over the implant roughened surface.

In its original form, the osseointegration protocol described by Brånemark et al. (18) required a submerged healing period of three to six months, without application of loading forces to the implants. This load-free healing period was considered a condition “sine qua non” to obtain the mineralized bone at the bone-implant interface before the second-stage surgery was performed with abutment and prosthesis placement (19-21). As a consequence, patients had either to wear a removable interim prosthesis either remain edentulous for an extended period before osseointegration could occur; however, this healing period before final prosthesis placement is inconvenient for patients (19,20).

This approach was modified, and the immediate loading of dental implants has been introduced (19,20). Immediate loading allows the immediate restoration of both, aesthetics and function, reducing the number of patient visits and the morbidity associated with a second surgical intervention and facilitating the rehabilitation of the patient, thereby resulting in increased patient satisfaction (19). Osseointegration of immediately loaded implants is similar to that of standard implants (18). However, immediate loading requires high primary stability of an implant.

Early reports, based on histology and subtraction radiography, suggest successful utilization of an auto-advancing threaded implant of Ti<sub>90</sub>Al<sub>6</sub>V<sub>4</sub> alloy with adequate strength to penetrate the bone without a fully prepared receptor site, while at the same time using a minimum diameter to avoid fracture of the surrounding bone. Such a construct of auto-advanced insertion may also diminish implant fractures and provide a stable dental implant, which, when placed in adequate numbers for stress distribution and with immediate loading in the mature bone, may indeed provide interim transitional support, ongoing applications, and ultimately long-term use (22).

Histology demonstrated healthy integrated bone surrounding mini-dental implants (MDIs) that were immediately loaded, four to five months postoperatively. Subtraction radiography of cases with MDIs in immediate function demonstrated bone integration around these implants, including regeneration of previous intraosseous and soft tissue defects after a 3-year elapsed period (23).

### ***1.3. Bone quality***

Except for a bone volume necessary for dental implant placement, bone quality is another essential factor in dental implant treatment planning.

#### ***1.3.1. Classification according to Misch***

Four types of macroscopic bone structures have been described in the classification proposed by Misch and Judy (22), dependent on bone density. The highest bone density or D1 type corresponds to > 1000 Hounsfield units in cone-beam computer tomography (CBCT) scans. The D1 bone is primarily dense cortical bone, with little or no cancellous bone, and it can be found in the anterior region of the mandible. The D2 bone has a dense cortex with dense cancellous, ranging in Hounsfield units from 800 to >1000. Anatomically, it is usually located in the anterior and posterior regions of the mandible and sometimes in the anterior maxilla. The D3 bone has a slender and porous part of the cortical bone with a fine structure of the cancellous bone. The typical localization of this type of bone is in the anterior and sometimes in posterior regions of the maxilla. Type D4 bone is, in most cases, without a cortical plate on the alveolar ridge. A typical region for this type of bone is the posterior part of the maxilla and the tuberosity, and it has the lowest density (< 300 Hounsfield units).

### ***1.4. Dental implant dimensions***

Dental implants can be divided into three implant groups dependent on their dimensions (24). One group comprises dental implants having standard dimensions (>3.5-5.0 mm in diameter and longer than 10 mm). The second group includes implants being shorter and wider (less than 8 mm of length and more than 5 mm of width), and the third group comprises narrow dental implants (10 mm or more long, but less than 3.5 mm in diameter). Dental implants of

standard size (SSI) are used for sites having sufficient bone volume both in length and width. Short and wide implants are aimed for sites of limited bone length, but abundant bone width. Narrow dental implants are recommended for sites where the bone is abundant in length but has limited width, i.e., for the narrow ridges.

Furthermore, narrow dental implants can also be additionally divided into three groups, based on their diameter. The narrowest dental implants are one-piece dental implants, made of Ti<sub>90</sub>Al<sub>6</sub>V<sub>4</sub> alloy. They are manufactured as one-piece implants, so a part of the implant (which is polished) emerges from the bone and mucosal tissue into the oral cavity, while sandblasted and etched threaded roughened surface is submerged into the bone. This type of implant is MDI.

### ***1.5. Mini-dental implants***

Patients have social and psychological problems due to non-restored dentition after tooth loss, e.g., with low self-esteem. Simple activities of daily social life, such as speaking, smiling, laughing, and chewing, are very challenging for edentulous persons. Replacing lost dentition is not only essential to preserve general health but also to preserve the jawbone. Resorbed jaws significantly affect a facial appearance and make the patient look much older. Restored dentition has a significant positive impact on an individual's mental health.

However, removable prosthesis as a method of teeth replacement has many shortages, and this is especially true for the CD. The soft tissue and the underlying alveolar bone under the denture can be easily overloaded or injured, and advanced bone atrophy is one of the consequences of unstable dentures. The vertical dimension of the lower third of the face is therefore reduced, and the mandible rotates in a contra clockwise direction, leading to an aged facial appearance and angular cheilitis (25-26).

Before dental implants existed, dentists often retained longer the remaining mandibular incisors and canines even if they were mobile due to periodontal disease or occlusal trauma to provide patients a temporary period to accept rehabilitation with a CD. Such an RPD was clasp retained until the patient agreed the remaining teeth were extracted and the CD fabricated. Keeping longer mobile teeth due to the severe bone resorption was the only option allowing dentists to postpone a mandibular CD in the past.

In the year 2002, a panel of experts in prosthodontics and dental implantology concluded that restoration of the edentulous mandible with conventional CDs was no longer the first choice of prosthodontic treatment due to undeniable evidence of the superiority of a two-implant overdenture, which should become the first choice of treatment for the edentulous mandible (27). However, many geriatric patients are not optimal candidates for placement of SSI, either due to their extensive ridge resorption and inadequate buccolingual bone width, or due to their financial limitations, chronic diseases, or fear to undergo surgical procedures, which include flap reflection, osteotomy and different modalities of bone augmentation. To avoid excessive surgical interventions, narrow dental implants have been proposed, and MDIs were patented for complete mandibular overdenture retention in the USA (27).

Initially, MDIs had only a machined smooth surface and were used as temporary implants. When SSI had been inserted, MDIs served as temporary implants to retain a denture during the period necessary for surgically submerged SSI to osseointegrate. However, it was challenging to explant some of the temporary implants later. It was also noticed that when their surface was treated (sandblasted and acid-etched), the MDIs osseointegrated completely. In 1998, they were patented by the U.S. Patent Office and approved for long-term use by the FDA.

MDIs have been proposed for CD stabilization and also for crowns or small anterior bridges in sites bearing low chewing forces (28,29). MDIs provide excellent stability and fast healing (28). They are indicated when there is a lack of buccolingual width or when there is insufficient bone support for an SSI placement (29). The survival rate of MDIs is reported to be about 94.2% (30).

The MDIs are one-piece implants, and their head can be in the shape of a ball attachment (Figure 1) or in the shape of a tooth prepared to receive a crown (straight head). The body of the MDI has a tapered form with "V" shaped threads. Such threads design has been used to increase initial contact with the bone, improve primary stability, increase the contact surface of the bone, and to benefit from a good dispersion of forces during the implantation process (31).

A part of the MDI that corresponds to a superstructure in two-piece implants is polished and has the shape of a ball or a square cone (resembling an abutment or a tooth prepared to receive an FPD).




Fig. 1. One-piece mini-dental implants with a rounded head; a. 2.5 mm and 2.0 mm wide; 10 and 12 mm long MDIs; b. MDI with a rounded head in the original package

The MDI with a ball head is used to accept the matrix that is housed in a removable prosthesis. The matrix consists of a metal housing and a rubber O-ring. The attachment actually provides the connection between the prosthesis and the implant, and a rubber ring acts as a stress breaker and prevents direct contact of a denture with an implant, and thus prevents the transfer of the occlusal and lateral forces to the implant body. Since the MDIs have not been in direct contact with the prosthesis, it is possible to transfer occlusal forces to the denture supporting tissue, i.e., to the denture bearing area, not overloading the implant. This allows immediate loading concept in MDIs having excellent primary stability.

There are many brands and designs of MDIs from various manufacturers. The market provides MDIs in diameters of 1.8, 2.1, 2.3, 2.4, 2.5, and 2.9 mm, and in lengths of 8, 10, 11, 12, 13, 14, 15, and 18 mm. The length of the MDI is measured at the part with the treated surface (sandblasted or acid-etched), which has a threaded conical portion, and which is inserted into the bone. After surgical preparation and implant placement, the MDI protrudes into the oral cavity upon insertion and becomes immediately vulnerable to forces from tongue, lips, and cheeks as well as to occlusal and parafunctional forces. However, MDIs have the benefit of obtaining excellent primary stability due to their self-driving threads and its conical form, which allows excellent retention in a cancellous bone during insertion. Therefore, the MDIs are less vulnerable to small forces, so they can be used for immediate loading if placed according to the Sendax Insertion Protocol (drilling up to 2/3 of the implant length with a drill from a set, which is smaller in diameter than the implant). If they do not

provide enough primary stability, they can be splinted without loading, and patients have to wait three months to allow their osseointegration.

The SSI requires a sufficient width of the alveolar ridge, which needs to be over 5.5 mm. Otherwise, bone augmentation procedures are indicated, but they increase the risk for possible side effects and costs and treatment duration (27). Sometimes, even in cases when SSI can be placed, patients prefer MDIs, due to their lower price, the possibility of immediate loadings, and less invasive surgical protocol. Benefits of MDIs include reduced chair time, simplified conventional restorations, and reduced cost to both a patient and a doctor (32). Placement of MDIs rather than SSI can be considered in cases of (i) compromised general health because they require minimally invasive surgery and trauma; (ii) narrow ridges, where grafting or bone regeneration is considered contraindicated or unwanted; (iii) desired immediate loading and function; and (iv) lower financial resources.

### ***1.6. Contraindications for MDI placement***

There are few contraindications for MDI placement, such as psychiatric diseases, chronic facial pain syndrome, history of infected medical endocarditis, i.e., rheumatic fever, which is not necessarily a contraindication (i.e., some cases may be deemed low risk and treatment should be carried out in conjunction with a cardiologist opinion), patients on bisphosphonates, who should not be considered as implant candidates due to risk for development of jaw osteonecrosis (33).

Before placement of MDI in irradiated patients, several determinants should be taken into consideration, such as the field, dose, and type of radiation, i.e., the dose of 5500 cGy can be considered as a cut-off for development of osteoradionecrosis. Nevertheless, the patients ought to be educated about the possible risks and alterations of osseointegration. Therefore, informed consent must be obtained from irradiated patients with the statement of fully understanding mechanisms and risks. The risk for developing osteoradionecrosis is reduced by the placement of implants using flapless technique because there is less manipulation of the periosteum compared to the open-flap placement procedure. Implant placement timing after radiation therapy should also be taken into account and understood well by the surgeon and by the patient. After radiation therapy, a decreased healing capacity is immediate and lifelong and worsens in time (34). When possible, implants are placed prior radiation, but



previous radiation therapy is not an absolute contraindication. Antibiotic use is empirical, and routinely 0.12% chlorhexidine gluconate is also prescribed every day for a period of one to two weeks after successful placement of the implants. There is an increased blood flow to the maxilla compared to the mandible. Thus, the placement of implants in maxillary arch could impose a lower risk for patients to develop osteoradionecrosis when compared to those placed in the mandible.

### ***1.7. MDI Placement protocol***

Before implant placement, the available bone quantity and quality must also be assessed. This can be accomplished by analyzing panoramic radiographs together with clinical observation, or by digital analysis of a CBCT scan. During clinical examination, aside from manual palpation of the bony ridge, the use of bone calipers or other thickness measuring devices is helpful. A calibrated "caliper" instrument can be used to define the thickness of the alveolar ridge. Moreover, valuable information on the mucosa thickness that overlies the alveolar ridge is also essential. The thickness of the oral mucosa can be measured by a graduated periodontal probe. The introduction of a periodontal probe through the mucosal tissue down to the crest of alveolar bone will give better information of tissue height than any other diagnostic test.

Surgical placement of an implant is usually started with incision and retraction of the alveolar mucosal tissue. This exposes a bone surface. When the bone is exposed by mucosal incision and retraction, the procedure is called the open-flap procedure. Another method of implant placement is the "flapless" method, i.e., an implant is inserted without reflecting a mucosal-periosteal flap. However, drilling must be performed through the mucosa and the alveolar bone. The flapless method is less traumatic for the patient than the open-flap one because it elicits less pain, recovery is much faster, and periosteal bone blood supply is preserved, which may be an advantage in more straightforward clinical cases (35).

The MDIs are placed in the alveolar bone by a particular surgical set according to the manufacturer's instructions, and if anatomical features allow, by using a "flapless" technique. It is vital to enable slow drilling through the bone with irrigation (cooling), and of course, careful implant insertion itself, to avoid implant fractures or bone necrosis. During drilling procedure, monitoring of depth of the preparation and angulation of insertion should be done

to ensure a reasonable degree of abutment parallelism for ease of O-ring insertion and removal in a mandibular overdenture.

The primary stability of 30 N/cm is needed to achieve the ability of immediate loadings. According to the fourth ITI Consensus in 2007, the immediate loading is the connection of implants with its prosthodontic superstructure within one week after implantation (36). The possibility of immediate loadings of MDIs with the CD is attributed to the high primary stability that is achieved during MDI insertion. The primary stability of MDIs can be achieved by using smaller diameter drills than is the MDI width (e.g., 1.1-1.3 mm diameter drills for 1.8 or 2.0 mm wide MDIs; 1.5-1.8 mm wide drills for 2.3-2.4 mm wide MDIs; 1.8-2.1 mm wide drills for 2.9 mm wide MDIs). By using this tactic, the self-tapping threads compress and condensate cancellous bone during insertion. The depth of preparation is also crucial for the primary stability of MDIs. In cases of D1 bone quality, or when the tip of the implant is embedded in the lower cortex of the mandible, the whole depth of preparation must be made. Otherwise, the implant may fracture when the force on the ratchet wrench exceeds 45 N/cm. In cases of D2 bone, two-thirds of preparation is necessary, in D3 situation one half, and D4 only one third. By self-tapping and bone condensation, primary stability is achieved.

During drilling and insertion procedure, care must be taken about adjacent tissues, including mandibular canal, mental foramen, inferior border of the mandible, adjacent tooth roots, lingual labial and buccal cortical bone plates, the floor of maxillary sinus or floor of nasal cavity, and posterior wall of maxillary tuberosity. A protocol of insertion is shown in Figure 2.

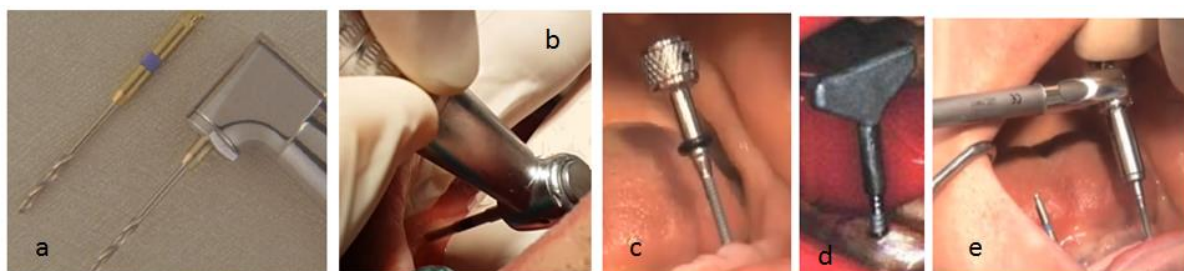


Fig. 2. a. drills, b. drilling procedure with drill cooling, c. finger driver, d. thumb driver, e. ratchet wrench driver; one MDI is not entirely inserted to allow better view for parallelism

The MDIs are driven slowly into the cancellous bone with finger and thumb wrench rotating it in a clockwise direction, obtaining compressive pressure. Implant threads and thinner and shallower bone preparation than the implant width or length allow implant auto-advancement by condensing the bone until it reaches the necessary torque for primary stability. When the torque is too strong for thumb driver, the ratchet wrench is used, and the moment of force is measured by a measuring device, which is a part of the ratchet. Too excessive force might snap the implant in a very dense Type 1 basal cortical bone, typically found in the lower mandibular region, and precaution should be taken, as the implant may fracture. It is better sometimes to unscrew it and to drill the bone a little deeper – i.e., the whole MDI length and then to screw it again. During the final seating of implant by Ratchet wrench approximately seven seconds each quarter of turn should last, and the waiting period between each quarter of turns should be 5 to 10 seconds long or more (allowing the viscoelastic bone to accommodate and expand).

In cases of sharp and thin residual alveolar ridges, the mucosal flap should be opened, and sharp bone tips and edges should be removed before MDI placement in order to assure sufficient bone width. In cases of flabby ridges or an excess of oral mucosal tissue, it should be removed prior to MDI insertion.

The implants should always remain within the periosteum boundaries. Perforation of the buccal or lingual plate can lead to implant failure. Therefore, in cases of very thin residual ridges, a CBCT scan may be necessary. The CBCT scan also offers a possibility to measure bone quality and density (by reading HU units) in each implant site, so we can decide how long the preparation would be to achieve primary stability.

The MDI surface that osseointegrates is rough, and mean roughness is about 150 microns. Some implants, besides having the microroughened surface, they also have an additional nano-roughened surface (20-30 nanometers). Micro and nano-roughness have been achieved by different surface treatments (37).

### ***1.8. Indications for mini-dental implants approved by the ITI Consensus statement***

The MDIs are aimed for alveolar ridges of reduced diameter of bone, but sufficient length. However, MDIs appeared at the dental market considerably later (two decades later) than SSI,

so long-term clinical studies with MDIs are still lacking. Even short-term clinical studies are lacking for some possibilities of MDI placement.

Recently, based on scientific clinical studies, four MDIs with a minimum of 10 mm length, inserted in the interforaminal region, have been approved as an appropriate treatment to support mandibular overdentures in edentulous patients with narrow ridges International Implantology Team (ITI consensus 2014; 38). The MDIs have also been approved by the ITI consensus statement for replacement of a single tooth (or for retention of short FPD) only in sites of reduced chewing forces, i.e., in anterior regions of the mandible and the maxilla. However, as MDIs represent one-piece dental implants, some esthetic shortcomings must be considered when using them in the anterior regions.

Up to date, only above mentioned two indications for MDI utilization had been approved. ITI consists of experts in the fields of Implantology and Implant-Prosthodontics. A panel of experts (i.e., the ITI team) gives recommendations and establishes consensus statements based on the scientific evidence, i.e., on experiments and long-term clinical studies.

However, mini-dental implants can also be used for many other clinical cases, but without the ITI approval, which has not been established due to the fact that there have not been enough scientific short- or long-term studies about their clinical outcomes. The MDIs can be used for retention of a complete maxillary denture (6 MDIs are recommended by the manufacturer), for retention of an FPD together with prepared natural teeth, as additional support in long-span FPDs, and to retain an RPD. The MDIs can even be used for retention of FPDs in some specific cases in posterior regions, or for retention of a single artificial tooth in cases of reduced mesiodistal space. However, there are some drawbacks to the use of MDIs, as their mechanical properties, although manufactured of grade five titanium dental alloy, which has superior properties than pure titanium, favor deformation, and/or implant fracture due to their small diameter (39). Therefore, all safety measures should be taken into consideration when planning the MDI retained denture.

### ***1.9. MDIs and clinical data***

In dental literature review, it is evident that all patient-related data, such as reports on quality of life (QoL), satisfaction, chewing ability, bite force, EMG activity, comfort, and retention have a positive outcome; the MDI removable prostheses improves patients' social status,

overall satisfaction, chewing and speaking ability, as well as QoL (40,41,42). The success rates of conventional standard size dental implants range from 96 to 100% (43). The MDIs in almost all studies with mandibular CDs showed similar success rates (>94%). The exceptions were studies in which MDIs were used to support a maxillary CD, when considerably lower success rates have been reported (53.8% to 90%), especially for maxillary CDs without full palatal coverage (44). Most studies evaluated mandibular overdentures supported by four MDIs, although mandibular overdentures supported by only 3 or 2 MDIs have also been reported as successful treatment options in short-term studies or within small patient groups (45,46). Only a few studies reported about FPDs retained by MDIs or by a combination of MDIs and prepared natural teeth (47,48).

Marginal bone loss analysis was performed in several studies for a maximum of 5 years follow-up (49-52). Most studies showed marginal bone loss values below 1.5 mm (49,51). Regarding different retention systems, the splinting of two MDIs with a prefabricated bar was associated with lower marginal bone loss (0.92 mm) than the non-splinted ball system with 2 MDIs (1.43 mm of marginal bone loss); however, without significant difference ( $P = 0.116$ ) (53).

Only one study reported the use of MDIs for retention of RPDs (54). The authors described how they aimed to randomize a clinical trial and how they intend to follow-up patients for 3 years who will receive 2 MDIs distally from the last remaining tooth on each side (a total of 4 MDIs will be inserted) in long-saddle Kennedy Class I patients, but the respective study has not been completed yet.

#### ***1.10. Implant assisted and/or Implant-retained removable partial dentures***

Osseointegrated implants of standard dimensions can be incorporated into RPD designs in an effort to overcome adverse effects of dislodging forces upon an RPD and adverse effects of strain and rotational forces to abutment teeth. Most design systems include SSIs in previous molar sites (55,56).

Implant assisted RPDs require healing abutments on distal implants as vertical stops, providing only support to an RPD, thus disabling denture saddle subsidence in posterior alveolar ridge sites (57,58; Fig. 3). With less denture subsidence, abutment teeth will bear less

unwanted rotational forces and will stay longer in function in the mouth without damage to their periodontal tissue.

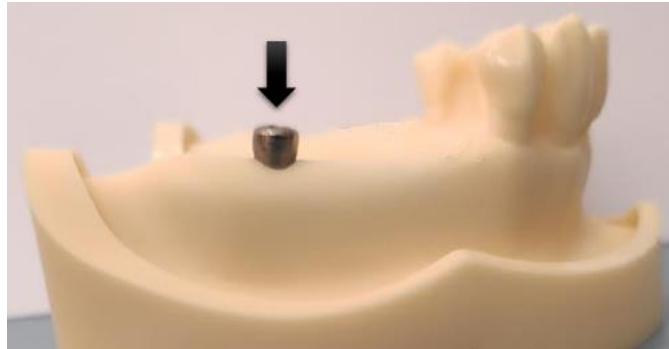


Fig. 3. Healing abutments for implant-assisted removable partial dentures; arrow shows a healing abutment

Dental implants can also be used for RPD retention. Implant-retained RPDs have abutments with an attachment system for retention of a RPD (Figure 4; 55-59), thus providing both support and retention to an RPD. It was reported in the dental literature that patients were more satisfied with implant-retained RPDs than with implant-assisted RPDs (60), but there was also a higher rate of late implant failure and more maintenance issues (60,61) in patients having abutments serving as an attachment for an RPD.

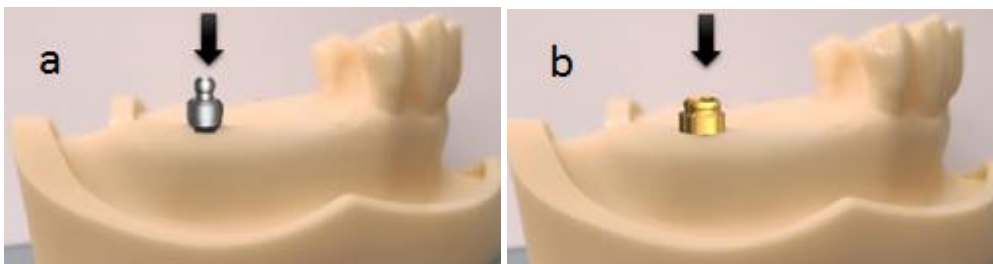


Fig. 4. a. Ball attachments for an implant-retained removable partial denture, b. locator attachment for an implant-retained removable partial denture

Dental implants can be combined with an RPD in several ways. They can be used with a healing abutment to provide only support to prostheses (62,63), and they can also be used with precision attachment screwed into the implant body representing an abutment, in cases

where extra retention is needed to support an RPD (64-69). Alternatively, dental implants of standard sizes can be used as abutments for the FPDs, or as abutments in double crown retained RPDs (70,75).

Many of the problems associated with conventional RPD wearing can be overcome with the placement of one or more strategically positioned dental implants that allow the construction of implant-assisted RPDs (76) or implant-retained RPD (77,78).

In implant-assisted RPD, healing abutments alone on distal implants serve as vertical stops and provide support only. Implant assisted (supported) RPD is a space-sensitive treatment (79). Inter-occlusal space must be carefully assessed prior to surgery. Insufficient bulk of acrylic resin over implant healing abutments may lead to reduced strength and a need for frequent repairs of a prosthesis. Design principles for an implant-assisted RPD should be consistent with those of a conventional RPD. The RPD should be well reinforced with metal around the location of the implant healing abutments or attachments. This prevents complications like a fracture of an acrylic resin around the implant attachment housing.

The RPDs with posterior distal extension saddles are prone to vertical, horizontal, and torque forces, which may jeopardize the stability and retention of the prosthesis, as well as the longevity of the patient's natural teeth (80). With the posterior support of the distal extension RPDs, a reduction of denture subsidence is present, resulting in improved performance of the prosthesis as well as maintaining the residual alveolar bone in an optimal state of health.

The chief goal of placing an implant under the posterior (i.e., mostly molar) sites of the distal extension denture base is to stabilize the RPD in a vertical direction. Distal implants effectively convert a Kennedy Class I or II denture to a Kennedy Class III denture. Therefore, implant-supported RPD is cheaper (because fewer implants are needed) and more stable, and may, therefore, be a better option for patients with limited financial resources than implant-supported FPD (65,67).

Benefits of implant assisted RPDs versus conventional RPDs are, as follows: enhanced retention, support, stability, improved aesthetics with elimination of retentive clasps in cases when attachment systems are used as implant abutments, preservation of remaining residual ridge by better distribution of forces and removal of damaging leverage to natural abutment teeth, improved comfort and confidence to patients, mental and emotional benefit to the patient by conserving natural teeth that can't be used as abutments, an increase in masticatory

efficiency, a futuristic treatment plan where implant placement may be staged, and the RPD can be used as an interim option and later with a placement of additional dental implants, transferred into an FPD.

In implant-retained RPDs, attachment systems allow not only enhanced denture stability but also improved RPD retention eliciting higher patient satisfaction, plus additionally higher rates of late implant failures and more maintenance, especially in those cases with the flabby oral mucosa, which allows an RPD more movements over the denture bearing area.

In some anatomical situations, the proximity to the maxillary sinus, or the inferior alveolar nerve, or financial restraints may prevent the placement of the SSIs. Although a patient can benefit from SSIs for better retention and stability of an RPD, such cases don't present usual treatment options, due to the fact that patients usually prefer an FPD (when it is possible to construct it), or they do not have enough bone volume to place SSIs. Such patients typically do not have enough bone length posteriorly due to mandibular canal, or they do not have enough bone volume, as they have narrow residual alveolar ridges.

The incorporation of the implant-supported RPD in prosthodontics offers improvements related to patient satisfaction and masticatory capacity compared to the conventional RPD (81). However, medical contraindications and the lack of ideal bone height and width needed for implant placement limit this therapeutic option (82). When additional surgery necessary for rehabilitation with an implant-supported FPD is not a possible option, an implant-retained RPD, also called a partial overdenture, can be proposed as a reliable treatment for partial edentulism. The implant-retained RPD may cause some discomfort due to the presence of a major metallic connector, and it will require periodic maintenance of the attachment retainers. However, this treatment option is a cost-effective one (82).

The objective of implant-retained RPD treatment is to place the implants in strategic positions that provide at least vertical stabilization of the partial denture by avoiding rotations (83).

Implants placed distally (ideally in the area of the second molar) would effectively change Kennedy Class I or II cases to Class III situations (84), which have a better biomechanical outcome. Therefore, fewer implants can preserve the long-term status of remaining teeth by this biomechanical improvement (85). Implants placed in the posterior regions might necessitate further augmentation procedures such as a sinus floor elevation and vertical and horizontal ridge augmentation (86).



## 2. AIMS OF THE STUDY

Clinical outcomes of slim MDIs in RPD wearers have not been reported yet or prospectively and longitudinally studied.

Therefore, it was the aim of this study:

1. To manufacture MDI retained RPDs in patients with severely reduced dentition (a linear support Kennedy Class I or II) with narrow alveolar ridges (buccal-lingual diameter < 4.5 mm).
2. To prospectively follow-up such patients in a clinical trial for at least two years, and:
  - to measure marginal bone level changes at implant sites on successive radiographs and to compare mesial and distal MDIs sites, as well as marginal bone loss in MDIs, inserted in the left and the right side of the respective jaw;
  - to compare the rate of mini-implant marginal bone loss dependent on gender, the target jaw for implant insertion, the dental status of the antagonistic jaw, and age;
  - to assess MDI survival and success rates;
  - to assess modified plaque (MPI) and modified bleeding indices (MBI) around the MDIs;
  - to assess technical complications with dentures, retention system or MDIs;
  - to assess complications with natural patient teeth (periodontal, caries, tooth loss, etc.);
  - and to measure patient-centered outcomes: satisfaction with orofacial esthetics, chewing function, and OHRQoL concept.
3. To monitor the dental patient-reported outcome measures (dPROMs), to calculate the effect size of treatment and monitor the function of the MDIs and RPDs over the first two years.

### 3. MATERIALS AND METHODS

A total of 84 patients having Kennedy Class I dental status with no posterior molar or premolar teeth participated in the study. Also, an additional 14 Kennedy Class II patients were included. This prospective clinical study was performed between January 2016 and July 2019 at the School of Dental Medicine, University of Zagreb, Croatia, with the approval of the Institution's Ethical Committee. Four patients were treated at the Private Dental Office in Pristina, adhering to the same treatment and rehabilitation protocol.

All participants were fully informed of the risks and benefits of participation in the study. A detailed explanation of the treatment protocol was provided to each participant before recruitment. All patients signed and approved the written informed consent. The cost of MDIs was covered by the Research Grant of the Croatian Science Foundation No. 1218 entitled: "Defining possibility of clinical performance of mini dental implants (MDIs) and their outcomes in in-vitro and in-vivo clinical prospective studies" (in Croatian language: „Definiranje mogućnosti uporabe mini dentalnih implantata (MDI) i njihovi rezultati u in vitro i u kliničkim prospektivnim istraživanjima“).

### ***3.1. Sample size***

The primary outcome of the study was to assess peri-implant marginal bone levels of the MDIs inserted in the Kennedy Class I patients for retention and support of free-end saddle RPDs. Primary outcomes were also MDI success and survival rates. Other outcomes of the study were the dPROMs scores, such as Oral Health Impact Profile with 14 items (OHIP-14), Orofacial Esthetic Scale (OES) and self-reported chewing function, assessment of MPI, MBI, and evaluation of prosthodontic complications.

The sample size calculation was based on the primary outcomes of this study, i.e., the marginal bone loss. However, in patients receiving free-end bilateral RPDs retained by two MDIs inserted in the previous canine or the first premolar sites could not be made based on earlier reports because of a lack of similar studies in the dental literature. Therefore, the sample size calculation was made based on the data reported for mean mini-implant marginal bone loss in mandibular overdentures retained by two or four MDIs (87,88).

The sample size calculation (with Type I error probability set at 0.05 and power at 80%) showed that a minimum of 12 patients should be included for assessment of mini-implant marginal bone loss and another 12 for comparison of mini-implant marginal bone loss between the maxilla and the mandible. Assuming that the drop-out rate can reach up to 30%, the minimum number of subjects was determined at 30 patients. Additionally, to compare differences between gender, another 30 patients were included, so a total number was determined to be 60 participants.

### ***3.2. Patient selection***

A convenient sample of 84 consecutive patients seeking removable prosthodontic rehabilitation participated in the study. A thorough clinical and radiological examination (panoramic radiographs and/or CBCTs) and measurements of mandibular height/width in the interforaminal region were made prior to MDI insertion. The patients recruited in the study represented a cohort of patients who met general and local inclusion criteria. The general inclusion and exclusion criteria are listed in Table 1.

The general exclusion criteria comprised patients who were or had: uncontrolled systemic disease, bleeding disorder, class III or IV, unable to understand treatment sequence and procedures due to psychiatric conditions or dementia, under i.v. injection bisphosphonate medication, a history of radiotherapy of head and neck region, alcoholism abuse, drug abuse, heavy smokers ( $\geq 20$  cigarettes per day), not able to maintain oral hygiene or clean prosthesis due to dyskinetic diseases, and negative opinion about dental implants and removable prostheses.

The local exclusion criteria comprised patients who had: premolar or molar posterior teeth left in the jaw, parafunctional habits (bruxism), bone labio-lingual width  $\geq 4.5$  mm and bone height  $\leq 12$  mm (from alveolar crest to inferior border of the mandible or the floor of the nasal cavity or maxillary sinus), and keratinized mucosa overlying alveolar ridge equal or more than four millimeters or a flabby ridge.

The keratinized thickness of oral mucosa was measured by pressing a graduated probe with a blunt end (Periodontal probe WHO with Ball Tip, Standard handle # 30, Jakobi Dental GmbH, Germany; Fig 5a), in the perpendicular direction towards the crest of the alveolar bone.

Table 1. General and local inclusion and exclusion criteria

| <b>General Inclusion or Exclusion Criteria</b>  |  |
|---|--|
| <b>Inclusion Criteria</b>   | <b>Exclusion Criteria</b>  |
| No contra-indication for minor oral surgery (ASA $\leq$ 2)  | Unhealthy, uncontrolled systemic disease, bleeding disorder, ASA class III   |
| No psychosis, dementia, or other psychiatric disorders  | Unable to understand treatment sequence and procedures due to mental illness or dementia   |
| No intravenous injection of bisphosphonates   | Intravenous-injection of bisphosphonate medication   |
| No uncontrolled bleeding disorders  | Poor attitude toward implants and prostheses   |
| No past radiotherapy of the mandibular or cervical regions  | Previous radiation of the head and neck region   |
| No smoking or smoking less than 20 cigarettes per day   | Alcoholism abuse, drug abuse and heavy smoking ( $\geq$ 20 cigarettes per day)   |
| The right attitude for denture insertion and understanding of treatment procedures, able to maintain hygiene  | Unable to maintain oral hygiene or to clean prosthesis due to dyskinetic diseases  |
| Willing to attend treatment follow-ups  |  |
| <b>Local Inclusion or Exclusion Criteria</b>  |  |
| Long span Kennedy class I edentulism with all posterior teeth missing   | Patients having some remaining posterior teeth   |
| No parafunctional habits  | Parafunctional habits  |
| Bone labio-lingual width $\leq$ 4.5 mm, height $>$ 12 mm from the alveolar crest to the inferior border of the mandible or the floor of the nasal cavity or maxillary sinus | Bone labio-lingual width $\geq$ 4.5 mm, height $\leq$ 12 mm from the alveolar crest to the inferior border of the mandible or the floor of the nasal cavity or maxillary sinus |
| Healthy soft tissue and underlying bone at the implant site, keratinized mucosa $\leq$ 4 mm   | Abundant soft tissue, keratinized mucosa $\geq$ 4 mm or flabby ridge   |

In cases when the thickness was approximately 3 mm or more, the patient received local anesthetics (Ubistesin forte 4%, or Mepivastesin 3%, 3M, Germany) and the periodontal probe with a sharp end (Periodontal probe WHO with Sharp Tip, Standard handle # 30, Jakobi Dental GmbH, Germany; Fig. 5 b) was punched through the mucosa until it reached the bone. The exact thickness of the mucosal tissue was then determined (Fig 5 c).

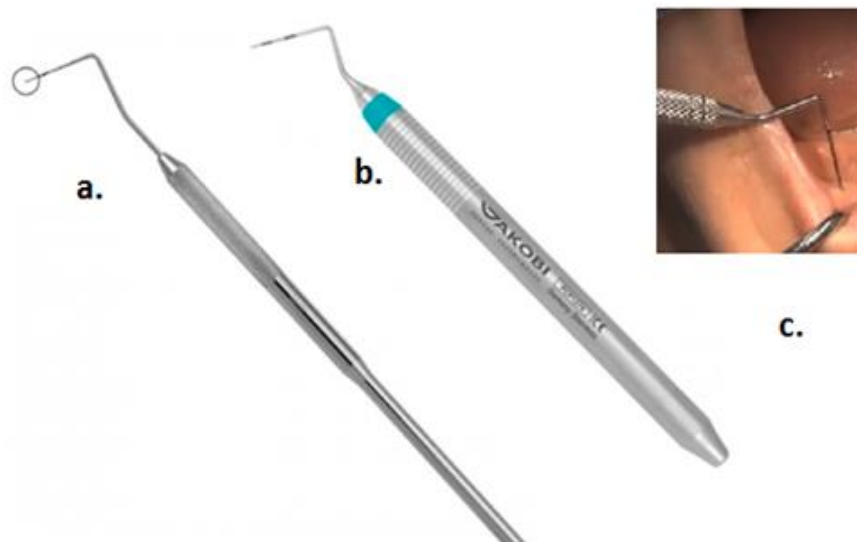


Fig. 5 a, b, and c. a. = periodontal probe with a ball tip; b. = periodontal probe with a sharp tip; c. Sharp tip probe measurement of mucosal thickness

All patients recruited in the study were previous clasp-retained RPD wearers. Inclusion criteria comprised the local conditions: all premolar and posterior molar teeth missing, alveolar bone labio-lingual width ranging from  $\geq 2.5$  mm to  $\leq 4.5$  mm, bone height  $> 12$  mm, and mucosa overlying alveolar ridge is less than 4 mm thick.

To be included, patients had to have a minimum of three to a maximum of six remaining anterior teeth in the mandible or the maxilla with the exception when only both canines remained. Patients who had both canines and no posterior or other anterior teeth were also included in the study.

The cost of MDIs was covered by the research grant (Croatian Science Foundation, grant No. 1218). The cost of new RPDs was covered by health insurance. The study flow chart is presented in Figure 6.

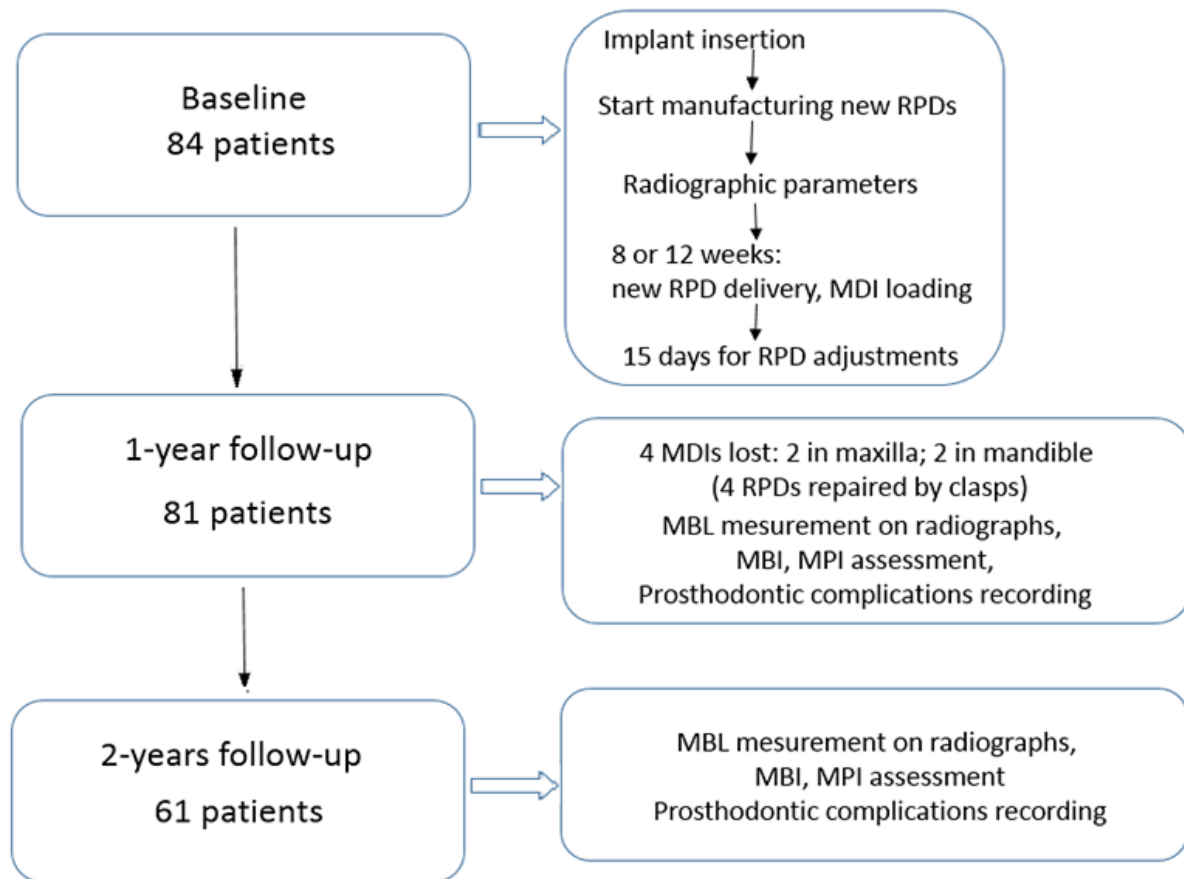


Fig. 6. The flow diagram of included patients and the follow-up examinations

At baseline, 84 patients were included, but three of them were not accessible for the follow-up visits. So, 81 patients were examined at the 1-year follow-up. Only 61 patients were clinically examined at the 2-year follow-up. Five of them were not accessible, and 15 patients promised to come after the three telephone calls but eventually did not show up at the scheduled date.

### 3.2.1. Surgical protocol: MDI insertion

All patients were clinically examined thoroughly with a detailed analysis of preoperative panoramic radiographs and/or CBCT scans. The patients took antibiotics pills one hour before the surgical intervention of MDIs' insertion, i.e., 2 g of Amoxicillin or 600 mg of Clindamycin,

All surgical procedures were performed by residents under the supervision of one experienced oral surgeon and one experienced prosthodontist. The MDIs were inserted without raising a



mucosal flap (flapless surgery). The MDIs used in the study were ball type (rounded head), manufactured by Dentium, South Korea; the width of MDIs was 2.0 mm or 2.5 mm; the length was 10 mm, 12 mm, or 14 mm. The MDI dimensions were chosen after the measurement of the available bone. The 2 mm wide MDIs were chosen when the alveolar bone width ranged from  $\geq 2.5$  mm to  $\leq 3.5$  mm. The 2.5 mm wide MDIs were chosen when alveolar bone width ranged from  $\geq 3.5$  mm to  $\leq 4.5$  mm. Patients who had an alveolar bone width of  $\geq 4.5$  mm were not included in this study because they could receive a narrow size or two-piece SSIs. All MDIs in this study were at least 10 mm long or longer (12 mm or 14 mm, respectively). The length of MDIs was chosen also upon the available bone. The tip of an implant had to end before reaching the low border mandibular cortex or prior the cortical nasal bone (or cortical bone of a maxillary sinus) in the maxilla.

All MDIs were inserted using the calibrated burs and a physiodispenser (W&H Implantmed, GmbH, Austria) with a saline solution for external drill cooling (Fig. 7 a-d.).

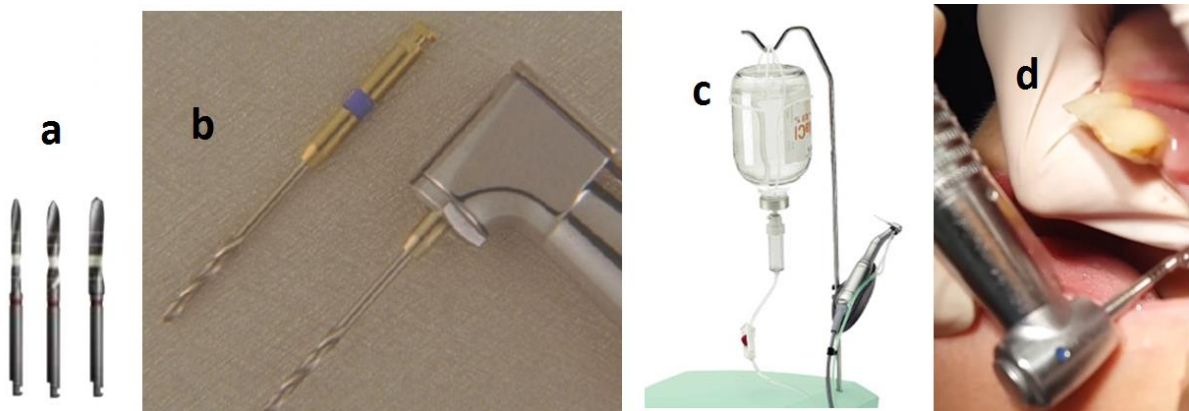


Fig.7 a.-d. a. and b. = calibrated burs, c.= physio dispenser, d. preparation for MDI insertion

All patients received local anesthesia (Ubistesine forte 4% or Mepivastesin 3%, 3M, Germany). The pilot drill was used to perforate the cortical plate of the alveolar ridge (Fig. 17 a and b). The bone was prepared to a depth of one-half of the implant length in cases of predicted low bone density, or to the extent of two-thirds of implant length in instances where a denser bone was present.

The drill diameter was always smaller than the MDI width; it was 1.3 - 1.5 mm wide for the 2.0 mm wide MDIs (1.5 mm wide for denser bone) and 1.8 - 2.1 mm wide for the 2.5 mm

wide MDIs (2.1 mm wide for denser bone). Each MDI was inserted into the prepared hole and rotated in a clockwise direction, exerting a downward pressure (self-tapping insertion technique), using the implant carrier (finger driver), then the thumb wrench, and finally the torque wrench (ratchet wrench; Fig. 8 a-d).

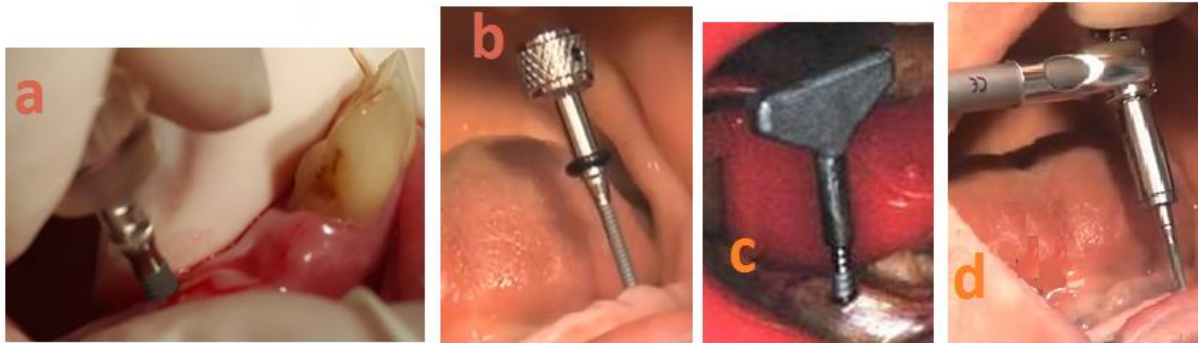


Fig. 8a-d. Insertion protocol: a and b.= MDI carrier (finger driver), c.= thumb wrench, d.= ratchet (torque) wrench

When the insertion torque was  $\geq 30$  Ncm, the MDIs were early loaded (6-8 weeks), and when the insertion torque was lower in any of the two inserted MDIs, they were late loaded, i.e., after the three months.

The MDIs were placed in previous sites of the first premolars or canines, just one or two tooth length posteriorly from the last distal anterior remaining tooth (Fig. 9 a and e; Fig. 10 a, b).

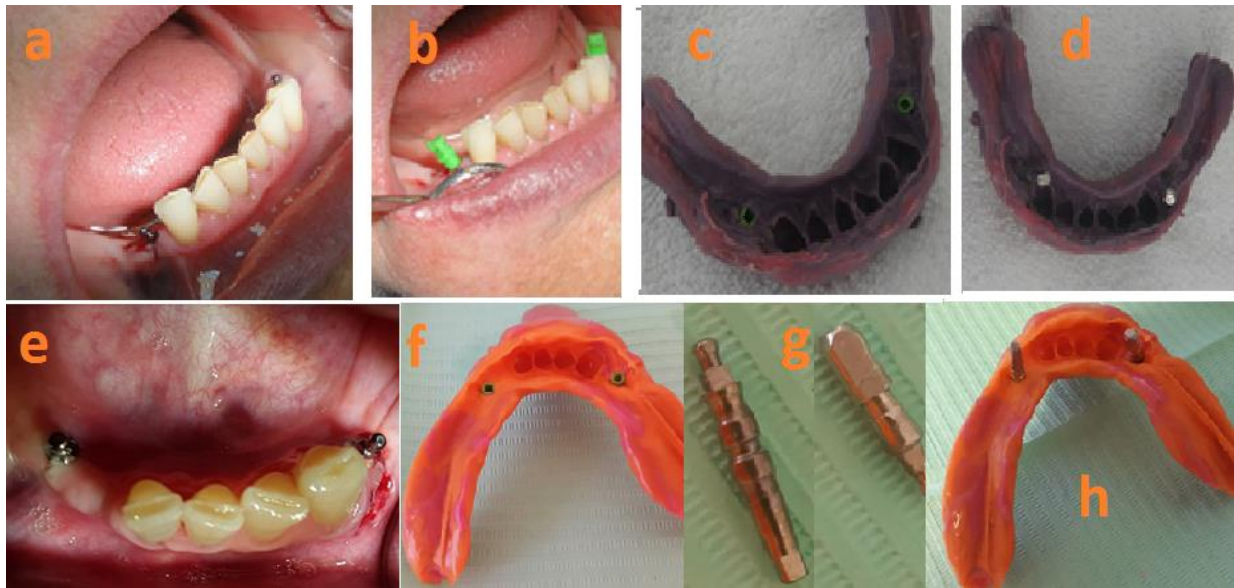


Fig. 9a-h. a. and e. Insertion sites of MDIs for retention of removable partial denture; b.= transfer caps mounted on MDIs, c. and f. = transfer caps picked-up in individual impressions, g.= laboratory analogs, f. and h. = laboratory analogs mounted in transfer caps on individual impressions

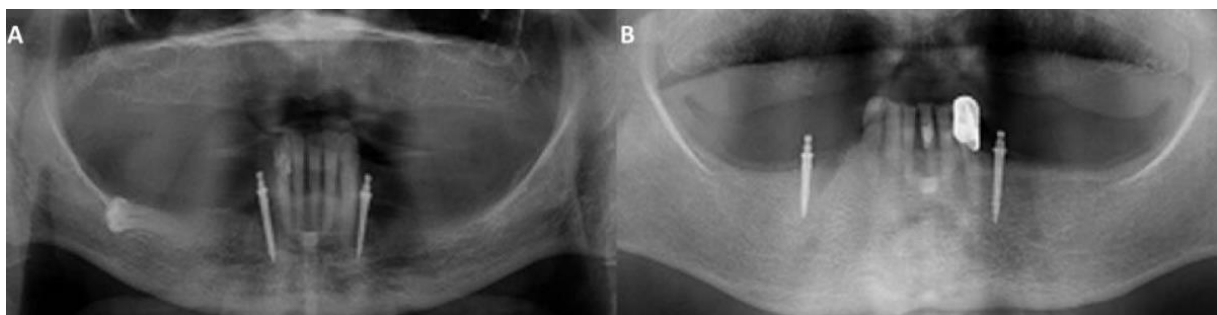


Fig. 10a and b. Panoramic radiograph of the patient with impacted third molar (A) and missing abutment teeth in posterior mandible rehabilitated with an MDI to support RPD. MDIs are inserted at either adjacent (A) or one tooth width posteriorly to the last remaining tooth (B)

All MDIs were inserted with the aim of retaining an RPD instead of clasps. In patients who had only remaining incisor teeth in the mouth, MDIs were placed in previous canine sites, except in cases of recent canine extraction or insufficient bone volume at that site (Fig. 9 e). In that case, the MDIs were inserted in previous first premolar sites. When one or two

remaining canines were present the MDIs were inserted in the first premolar sites. Two holes (one hole on each side) were drilled in the old existing RPDs in order not to transfer any pressure to the inserted MDIs.

After the MDIs' insertion, the patients were advised to use an antiseptic mouth rinse (i.e., chlorhexidine gluconate 0.12%) for five days, to take analgesics (non-steroid anti-inflammatory drugs) if necessary up to 5 days, and ice packs from the outside for 24 hours. Patients were instructed in detail on how to maintain oral hygiene, together with advice to avoid hot food or hot beverages for the first two days after MDI insertion.

### ***3.3. Prosthodontic protocol: RPD design***

All RPDs were made by prosthodontic residents under the supervision of one experienced specialist. The RPDs were reinforced with the Co-Cr framework to prevent denture fractures (Fig. 11 a.). All RPDs had lingual plate major connectors and raised cingulum at the remaining anterior teeth (Fig. 11 b).

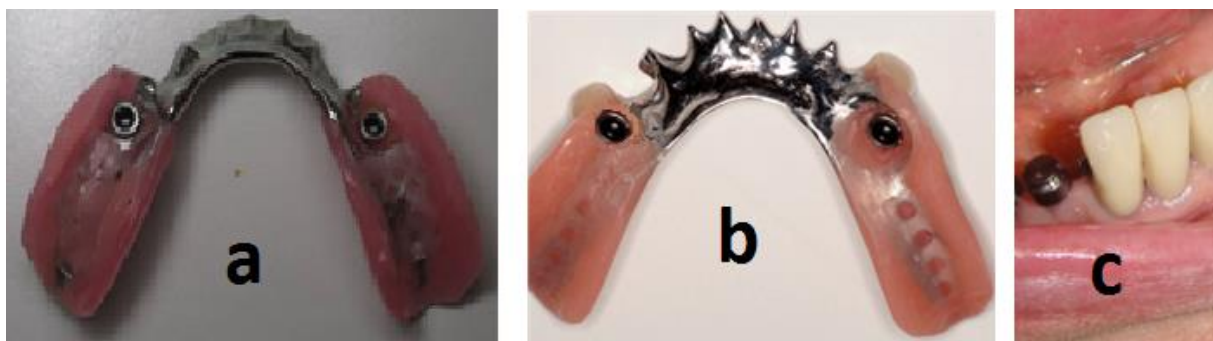


Fig. 11 a-c. a.= Removable partial dentures were reinforced with CoCrMo framework, b.= CoCrMo framework had lingual plate major connectors, and raised cingulum, c.= metal housings (matrices) were attached on the MDI ball head before RPD processing

Individual impressions in custom-made trays were obtained. Borders were obtained from each patient by impression compound (ISO Functional Stick, GC, Tokyo, Japan) used to create borders, and an individual impression was taken by a medium viscosity silicone (Dimension™ VPS Impression Material, 3M ESPE, Seefeld, Germany). Before obtaining the

impression, the transfer caps were attached to each MDI (Fig. 9 b). Laboratory analogs (Fig. 9 g) were inserted into the transfer caps, picked-up in the individual impression (Figs. 9 c, d and f, and h), and laboratory casts were poured in hard stone. Matrices (metal housings with O-rings) were attached to the MDI analogs prior to RPD manufacture (Fig. 11 c). During manufacture, O-rings were temporarily removed from the metal housings and returned after manufacture. After new RPD delivery, denture occlusion and sore spots were adjusted throughout the first 15 days.

### ***3.4. Clinical parameters of the mini-dental implants***

Clinical parameters assessed in the study included the MPI and the MBI assessments (scores ranged from 0-3). The MPI was assessed according to Mombelli et al. (89): 0 = no plaque detected, 1 = plaque only recognized by running a probe across the surface supragingival, 2 = plaque can be seen with unaided vision, 3 = abundance of soft matter. Peri-implant soft tissue was assessed using the MBI (90) with ranking from 0 to 3: 0 = no bleeding, 1 = pinpoint bleeding, 2 = linear bleeding, 3 = profuse bleeding.

Any problems with MDIs after RPD deliveries (pain, exudate, mobility), including the loss of MDIs, were also recorded.

### ***3.5. Radiographic parameter assessment***

The mini-implant marginal bone loss was analyzed at the mesial and the distal sites of each MDI (Fig. 12) on digital intraoral radiographs obtained using the long-cone paralleling technique (Minray Soredex Intraoral, Tuusula, Finland, 70kV, 0.16 mAs).

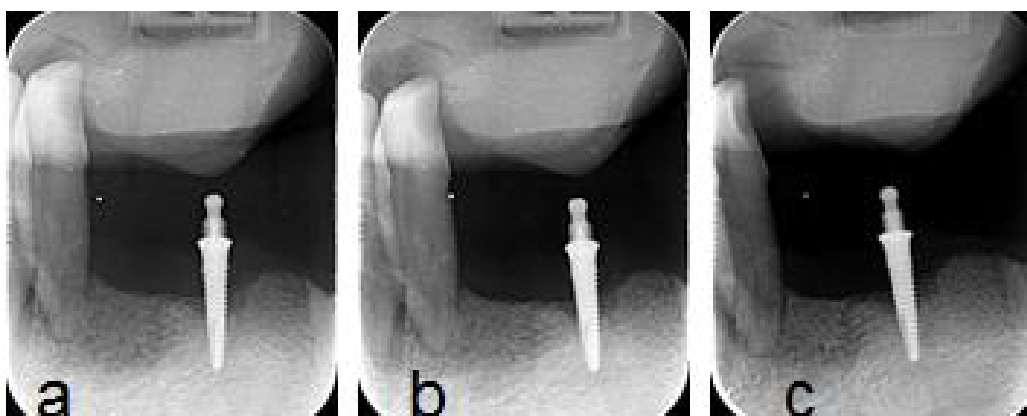


Fig. 12. Marginal bone loss at mesial and distal site of each MDI, a. after insertion, b. after one year, c. after two years



A film holder (X-ray holder, Super-Bite®, Kerr USA, Orange, CA) with customized silicone index for each patient was used for reproducible projections (Figure 13 a,b).

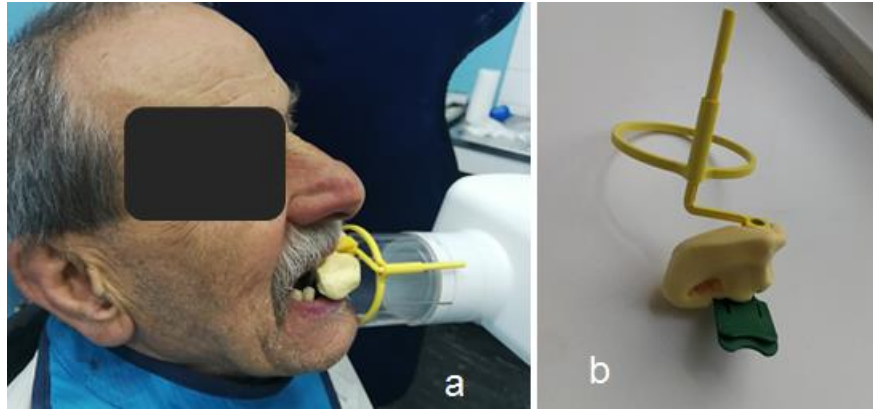


Fig. 13a. Long-cone paralleling technique, b. Film holder with customized silicone index

Peri-implant marginal bone loss was analyzed using the software Scanora™ software 5.1. (Soredex, Tuusula, Finland) at the 10 x zoom-in. Magnification error was corrected using the formula: Corrected crestal bone level = [measured crestal bone level × actual implant length)/measured implant length], as reported by Yoo RH et al. (91).

The bone level in contact with the roughened MDI surface after implant placement was considered the baseline data, except in those cases when MDIs were submerged during insertion (Fig. 14 a-d).




Fig. 14a. Mini-implant surface in the first contact with the bone after surgery was the baseline for measurement of bone level changes; b. No bone level changes after one year; c. Cervical polished surface slightly submerged into bone, marginal bone loss was measured from the first thread in contact with the bone (marked with arrows), d. 1-year bone loss at mesial and distal sides along the polished submerged surface was considered as bone remodeling and not bone loss; therefore although there was a small amount of bone loss along the polished surface it was considered as no bone loss (bone remodeling)

In the submerged MDIs, bone loss until it reached the roughened threaded surface was considered as bone remodeling (Fig 14 c and d). In the submerged MDIs, bone loss was measured from the first bone contact with the roughened treaded surface towards the MDI tip. All radiographic assessments were performed by a single trained researcher.

### ***3.6. Implant success and survival criteria***

Implant success and survival rates were assessed at the 1-year and the 2-year follow-up examinations. Implant survival was evaluated based on implant failure and was defined as a loss or removal of an implant for any reason. However, implants being still in site, but having sizeable continuous radiolucency  $>2$  mm were attributed to the survival group, not the success

group. Implant success was defined based on the success criteria described by Buser et al. (92).

The MDI was considered as successful when patients had no pain or history of pain, no foreign body sensation, and/or dysesthesia, when there was no recurrent peri-implant infection with suppuration, without implant mobility, or continuous radiolucency around the implant, and when the implant could be accounted possible for restoration.

### ***3.7. Dental patient-reported outcome measures (dPROMs)***

The dPROMs utilized in this study included self-assessments of OHRQoL, OE, and self-reported chewing function (CF). The Croatian language version of the OHIP-14 questionnaire (93, 94) or the Albanian language version of the OHIP-14 questionnaire was used for assessment of OHRQoL.

The Croatian language version or Albanian language version of the Chewing Function Questionnaire (CFQ; 95,96) was used for the assessment of a self-reported chewing function.

The Croatian language version or Albanian language version of the Orofacial Esthetic Scale (OES; 97,98) was used to assess self-reported orofacial esthetics.

For each of the OHIP14 items, patients were asked how frequently they had experienced the impact during the last week (99).

The five categories of choice per item in the OHIP-14 questionnaire were “never,” “rarely,” “occasionally,” “often,” and “very often”; (Likert scale ranged from 0 to 4). Zero indicated an absence of problems, while higher scores indicated more impaired oral health (Table 2 MM). The OHIP summary score was calculated by summarizing all item scores of the OHIP-14 questionnaire.

When completing the CFQ, patients were asked about their difficulties while chewing different foods during the last week. The CFQ answers were graded on the Likert scale from 0 to 4 (0 = absence of problems, up to 4 = the most significant problem or inability to chew particular food). The summary scores were calculated by summing the answers.

For both questionnaires, summary scores were used for statistical analysis. Summary scores for the OHIP-14 questionnaire ranged from zero to 56, and summary scores for the CFQ ranged from zero to 40 (Table 2).



The Croatian version of the Orofacial Esthetic Scale or the Albanian version of the OES included eight items of the patient's self-perceived orofacial esthetics. Assessments were made on a Likert scale ranging from 1 to 5 (1=completely unsatisfied; 5=completely satisfied; the summary scores ranged from 8 to 40, the higher summary scores indicated greater satisfaction with orofacial aesthetics) (Table 2).

The questionnaires were completed on several occasions: the first time before treatment, the second time one month after treatment (when all adjustments of new RPDs had been finished), the third time at the 1-year follow-up examination, and the fourth time at the 2-year follow-up examination.

Table 2. A brief overview of questionnaires used in the study with their summary score ranges and questions (items)

| Orofacial Esthetics Scale  | Oral Health Impact Profile  | Chewing Function Questionnaire (CFO)                                  |
|--|---|---|
| How do you assess the appearance of... during the last 7 days                      | Have you had (problems or feelings that) ... because of problems with teeth, mouth, dentures? | Have you had any difficulty chewing foods such as ... (or similar)?   |
| 1. The lower third of your face  | 1. Pronouncing words  | 1. Apple, pear, raw carrots   |
| 2. Your profile appearance of the lower third of your face                         | 2. Sense of taste worsened  | 2. Bacon, firm meat   |
| 3. Your mouth (smile, lips, visible teeth)   | 3. Painful aching (mouth, teeth)  | 3. Biscuits, crackers   |
| 4. Your dental arches  | 4. Uncomfortable to eat any foods   | 4. Fresh bread, doughnut  |
| 5. Assess the shape of your teeth  | 5. Been self-conscious  | 5. Nuts, pecan, almonds, peanuts, macadamia                           |
| 6. Assess the color of your teeth  | 6. Felt tense   | 6. Lettuce, raw cabbage   |
| 7. Your gums or artificial gums  | 7. Diet has been unsatisfactory   | 7. Biting different foods, incision                                   |
| 8. Assess the overall appearance of your lower third of the face, mouth, and teeth | 8. Interrupt meals  | 8. Chewing gum  |
|  | 9. Difficult to relax   | 9. Have you felt insecure when chewing                                |
|  | 10. Feel a bit embarrassed  | 10. Have you noticed food catching on your teeth or tooth replacement |
|  | 11. Irritable with people   |   |
|  | 12. Difficulty doing usual jobs   |   |
|  | 13. Life, in general, less satisfying   |   |
|  | 14. Totally unable to function  |   |
| Score range 1-5  | Score range 0-4   | Score range 0-4   |

### ***3.7.1. Prosthodontic maintenance***

Mechanical complications regarding the RPDs and/or attachments were recorded during the course of the trial and included: denture fractures, denture relining, loosening of metal housings, O-ring replacement, artificial tooth detachment, etc. Additional denture adjustments later than a period of the first 15 days after an RPD delivery were also recorded. All patients were advised to contact the dental office immediately if they notice any problems with dentures or MDIs.

### ***3.8. Statistical analysis***

The mean values of mini-implant marginal bone loss were calculated. The marginal bone loss during the 2<sup>nd</sup> year was computed by subtracting the marginal bone loss after one year from the marginal bone loss after two years. The mean marginal bone loss values were compared between the mesial and the distal sites of both the left and the right MDI by paired-sample t-test. Left-right differences were also examined, as well as the differences between the marginal bone loss in the first and the second year (paired t-test).

Additionally, mini-implant marginal bone loss differences between the maxilla and the mandible and between genders were compared by the independent-sample t-test. One-way ANOVA was used to test the significance of the marginal bone loss differences dependent on the status of an antagonistic jaw (complete denture, removable partial denture, or natural teeth/fixed partial denture).

The general linear model (ANCOVA) was used to analyze the effects of age (as a continuous variable - covariate) and two factors: gender and jaw of insertion (as independent factors) on the rate of the marginal bone loss after one year and after two years in function. The general linear model (ANCOVA) was also used to test the effects of three factors: gender, the jaw of insertion, and antagonistic jaw (as independent factors) and age as a covariate on the dependent variable – mean marginal bone loss after the 1<sup>st</sup> and after the 2<sup>nd</sup> year.  $\chi^2$  test was used to compare the periodontal indices MPI and MBI at the one-year and the 2-year follow-up examination. The survival curves were used for survival and success reports.

For the dPROMs utilized in this study, effect sizes of treatment were calculated, separately for the OHRQoL (OHIP-14), OES, and the CFQ. The standardized effect size was calculated for

all three questionnaires, according to Allen et al. (104), as follows: mean (score before treatment – score after treatment) / standard deviation of the score before treatment. According to Cohen, the effect size of 0.20 is considered small, 0.50 moderate, and 0.80 large (105).

To monitor and compare dPROM score changes (i.e., OES, OHIP-14, and CFQ) over the observation period (15 to 30 days after treatment, 1-year follow-up, and 2-year follow-up examination) repeated measures were used for comparison. Statistical analyses were performed using standard statistical software (SPSS for Windows, version 20).

## 4. RESULTS

A total of 84 patients having Kennedy Class I were included at the baseline (66 females and 18 males) and each patient received two MDIs, one or two tooth length distally from the posterior remaining anterior tooth and a new RPD. Most of the patients received treatment in the mandible (57 patients), while 27 patients received treatment in the maxilla. At the baseline, mean patients' age was  $66 \pm 7.6$  years (age ranged from 51 to 83 years). Patients were divided into three age groups ( $\leq 60$  years – 19 patients; 61-70 years – 45 patients;  $\geq 71$  years – 20 patients).

At the one-year follow-up stage, 81 patients responded: 55 patients had MDIs inserted in the mandible, and 26 in the maxilla; 63 patients were females, 18 were males; 18 patients were  $< 60$  years old, 44 were in age 61-70 years, and 19 were older than 70 years; 34 of the patients had CDs as antagonistic teeth, 33 patients had RPDs, and 16 patients had natural teeth (NT) or fixed partial dentures (FPD). At the 2-year follow-up, only 61 of the recruited patients responded: 45 were females, and 16 males; 37 patients had MDIs inserted in the mandible, 24 in the maxilla; 12 patients were  $< 60$  years old, 32 were 61-70 years old, and 17 were older than 70 years.

During the first year, four MDIs failed, two in the maxilla, and two in the mandible (in 4 different patients). The MDIs were lost soon after loading. The lost MDIs were not replaced; the wire clasps were inserted into the existing RPDs. None of the MDIs were lost afterward.

Fourteen Kennedy Class II patients were also recruited in the study (11 females, three males, 52-80 years, 8 MDIs were inserted in the mandible, 6 in the maxilla,  $65 \pm 7.1$  years old). All patients were available at the one-year and two-year follow-up examinations.

#### ***4.1 Radiological data on the marginal bone level***

Values of marginal bone loss MBL of MDIs used for retention of RPDs in Kennedy Class I patients are presented in Table 3, separately for the mesial and the distal sites of the left and the right MDI, and individually for the left and the right MDI during the 1<sup>st</sup> and the 2<sup>nd</sup> year in function, as well as for the mean mini-implant marginal bone loss at the 2-year observation stage. The mean values of both MDIs are also presented for the same observation period (as there were no left side-right side differences). One-sample Kolmogorov-Smirnov test revealed that the measure for mini-implant marginal bone loss was a continuous variable, which had a

normal distribution ( $p>0.05$ ), and for this reason parametric statistic tests were applied in the subsequent statistical analyses.

Table 3. Mean marginal bone loss (MBL) of mini-dental implants (MDIs) used for retention of removable partial dentures in Kennedy Class I patients without posterior teeth;  $\bar{x}$ =mean value (arithmetic mean), SD=standard deviation; N=number of patients

| Mean MBL                                       | Variable           | N  | Minimum | Maximum | X (mm)      | SD   |
|--|--------------------|----|---------|---------|-------------|------|
| <b>MBL during the 1<sup>st</sup> year</b>      | Left MDI, mesially | 79 | 0.00    | 1.50    | <b>0.21</b> | 0.38 |
|  | Left MDI distally  | 79 | 0.00    | 1.80    | <b>0.26</b> | 0.43 |
|  | Right MDI mesially | 79 | 0.00    | 1.50    | <b>0.20</b> | 0.42 |
|  | Right MDI distally | 79 | 0.00    | 1.50    | <b>0.24</b> | 0.45 |
| <b>MBL during the 2<sup>nd</sup> year</b>      | Left MDI mesially  | 59 | 0.00    | 1.00    | <b>0.16</b> | 0.25 |
|  | Left MDI distally  | 59 | 0.00    | 0.80    | <b>0.13</b> | 0.21 |
|  | Right MDI mesially | 57 | 0.00    | 1.20    | <b>0.09</b> | 0.25 |
|  | Right MDI distally | 57 | 0.00    | 1.10    | <b>0.11</b> | 0.25 |
| <b>MBL after 2 years</b>                       | Left MDI mesially  | 61 | 0.00    | 2.50    | <b>0.36</b> | 0.56 |
|  | Left MDI distally  | 61 | 0.00    | 2.30    | <b>0.34</b> | 0.50 |
|  | Right MDI mesially | 59 | 0.00    | 2.00    | <b>0.28</b> | 0.55 |
|  | Right MDI distally | 59 | 0.00    | 1.90    | <b>0.34</b> | 0.55 |
| <b>MBL during the 1<sup>st</sup> year</b>      | Left MDI           | 79 | 0.00    | 1.65    | <b>0.24</b> | 0.38 |
|  | Right MDI          | 79 | 0.00    | 1.90    | <b>0.23</b> | 0.45 |
| <b>MBL during the 2<sup>nd</sup> year</b>      | Left MDI           | 59 | 0.00    | 0.80    | <b>0.15</b> | 0.23 |
|  | Right MDI          | 57 | 0.00    | 1.15    | <b>0.10</b> | 0.24 |
| <b>MBL after 2 years</b>                       | Left MDI           | 59 | 0.00    | 2.40    | <b>0.34</b> | 0.53 |
|  | Right MDI          | 57 | 0.00    | 1.80    | <b>0.25</b> | 0.45 |
| <b>Mean MBL during the 1<sup>st</sup> year</b> | -                  | 77 | 0.00    | 1.55    | <b>0.23</b> | 0.35 |
| <b>Mean during the 2<sup>nd</sup> year</b>     |                    | 57 | 0.00    | 0.63    | <b>0.12</b> | 0.18 |
| <b>Mean MBL after two years</b>                |                    | 57 | 0.00    | 2.10    | <b>0.30</b> | 0.47 |

Figure 15 shows arithmetic means of marginal bone loss (MBL) with standard deviations during the 1<sup>st</sup> year of removable partial dentures (RPD)wearing supported by MDIs.

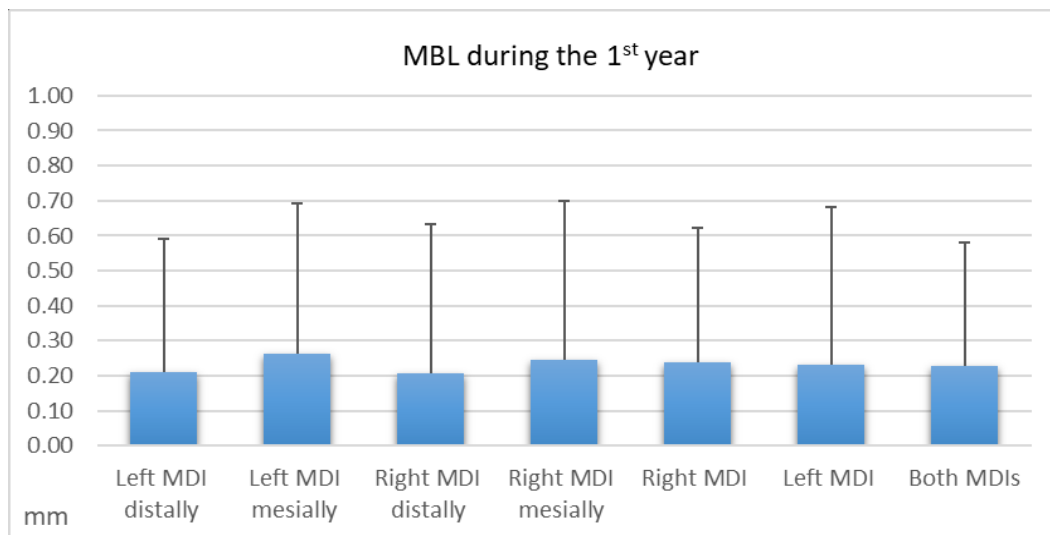


Fig. 15. The marginal bone loss around mini dental implants (MDIs) with **standard deviations** during the 1<sup>st</sup> year of RPD wearing

Figures 16 shows mean values of marginal bone loss (MBL) with standard deviations, separately for the mesial and the distal mini dental implants (MDI) sites and individually for the left and the right as well as MBL during the 2<sup>nd</sup> year of RPD wearing.

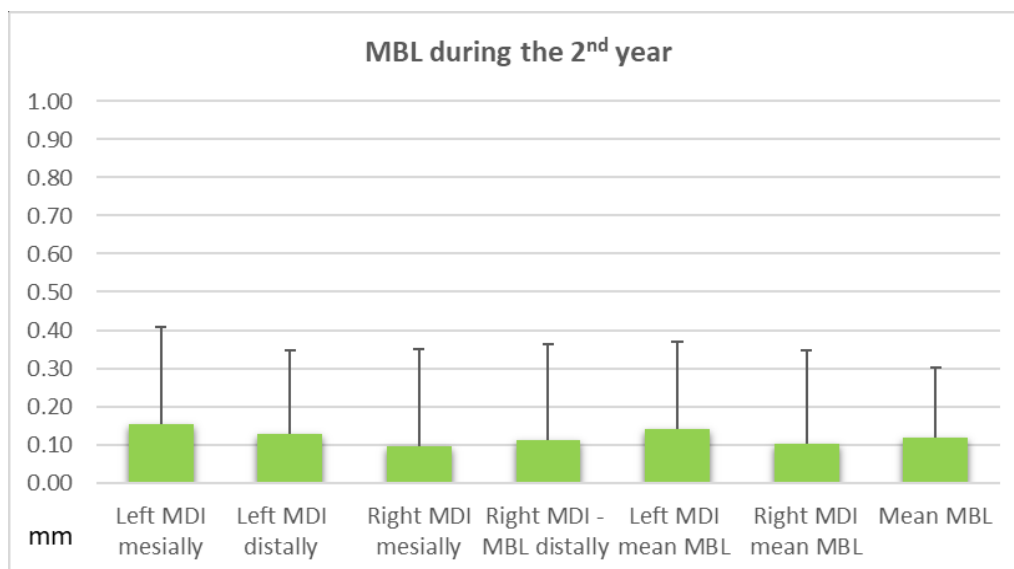


Fig. 16. MBL with **standard deviations** during the 2<sup>nd</sup> year of RPD wearing



Figures 17 shows means of mini-implant marginal bone loss (MBL) with standard deviations recorded at the 2-year observation stage.

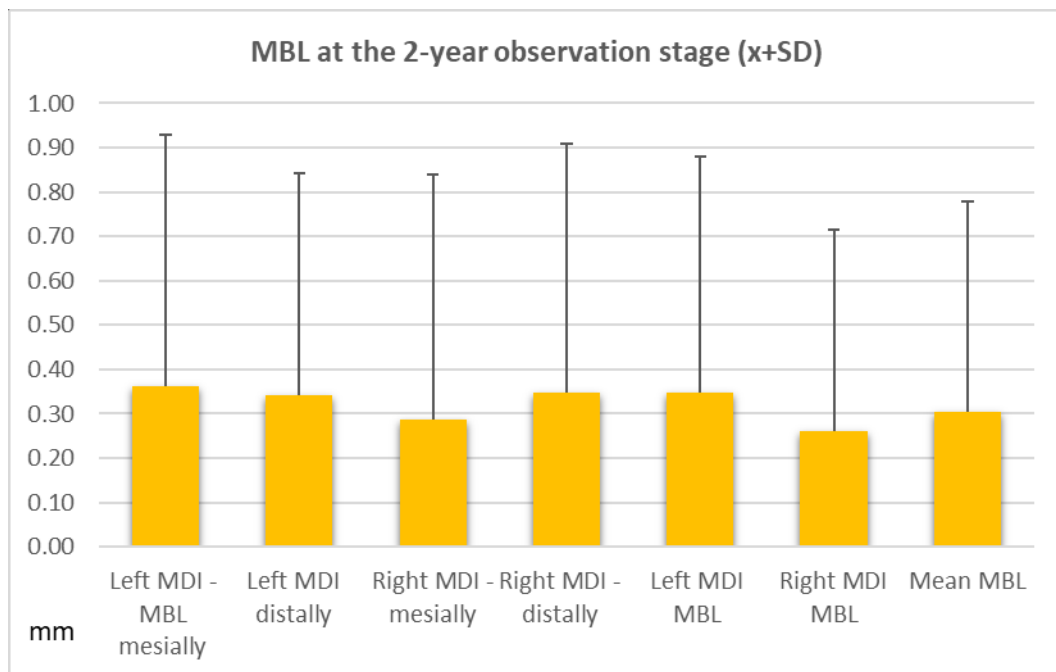


Fig. 17. Mini-implant marginal bone loss with standard deviations at the 2-year observation stage

There were no statistically significant differences between the mesial and the distal mini-implant sites, neither during the first or the second year of RPD wearing (MDI loading) ( $p > 0.05$ , related sample t-test). There was also no significant difference at the two-year observation stage ( $p > 0.05$ , related sample t-test).

Table 4. Significance of the difference between mean values of marginal bone loss (MBL) on the mesial and the distal implant site; N = number. x= mean value. SD = standard deviation. SE = standard error t= t value. DF= degree of Freedom. p= significance (p-value); NS= not significant

| Variable   | x           | N  | SD   | SE   | t      | df | p       |
|--|-------------|----|------|------|--------|----|---------|
| <b>Left MDI – mesially during the 1<sup>st</sup>-year :</b>      | <b>0.21</b> | 79 | 0.38 | 0.04 | -1.751 | 78 | .084 NS |
| <b>Left MDI - distally during the 1<sup>st</sup>-year</b>        | <b>0.26</b> | 79 | 0.43 | 0.05 |        |    |         |
| <b>Left MDI - mesially during the 2nd year :</b>                 | <b>0.15</b> | 59 | 0.25 | 0.03 | 1.509  | 56 | .137 NS |
| <b>Left MDI - distally during the 2nd year</b>                   | <b>0.13</b> | 59 | 0.22 | 0.03 |        |    |         |
| <b>Right MDI - mesially during the 1<sup>st</sup>-year :</b>     | <b>0.20</b> | 79 | 0.42 | 0.05 | -1.797 | 78 | .076 NS |
| <b>Right MDI - distally during the 1<sup>st</sup>-year</b>       | <b>0.24</b> | 79 | 0.45 | 0.05 |        |    |         |
| <b>Right MDI - mesially during the 2nd year :</b>                | <b>0.09</b> | 57 | 0.26 | 0.03 | -.894  | 54 | .375 NS |
| <b>Right MDI - distally during the 2nd year</b>                  | <b>0.11</b> | 57 | 0.25 | 0.03 |        |    |         |
| <b>Left MDI - mesially - at the 2-year observation stage:</b>    | <b>0.36</b> | 61 | 0.57 | 0.07 | .683   | 58 | .497 NS |
| <b>Left MDI – distally-at the 2-year observation stage</b>       | <b>0.34</b> | 61 | 0.50 | 0.07 |        |    |         |
| <b>Right MDI-MBL mesially - at the 2-year observation stage:</b> | <b>0.28</b> | 59 | 0.55 | 0.07 | -1.772 | 56 | .082 NS |
| <b>Right MDI - distally at the 2-year observation stage</b>      | <b>0.34</b> | 59 | 0.56 | 0.07 |        |    |         |

Figure 18 shows mean values of mini-implant marginal bone loss with standard deviations of the mesial and the distal mini-implant sites during the first and the second year of loading, as well as means at the two-year observation stage. No significant differences were observed (Table 4;  $p>0.05$ , paired sample Student's t-test).

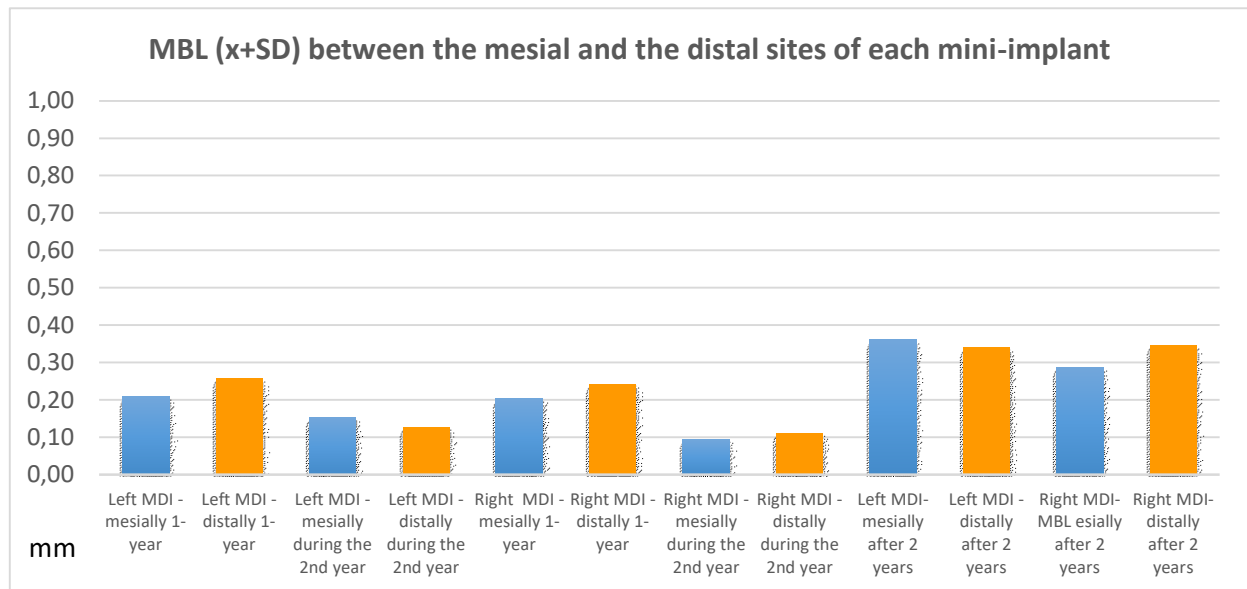


Fig. 18. Mean mini-implant marginal bone loss with standard deviations at the mesial and the distal MDI sites

Since there were no significant differences between the mesial and the distal MDI sites, means were computed for the MDI on the right side and the left-side MDIs, presented in Table 5, together with standard deviations and the significance of the differences between the left and the right side. There were no significant differences in mini-implant marginal bone loss between the left and the right side ( $P>0.05$ , related sample Student's t-test).

Table 5. Mean values and significance of the differences between the left and the right mini dental implants (MDIs); N = number of patients; x= mean value. SD = standard deviation. t= t value. DF= degree of Freedom. p= significance (p value); NS= not significant

| Variable                                       | x    | N  | SD   | t    | DF | p       |
|--|------|----|------|------|----|---------|
| Left MDI: MBL during the 1st year              | 0.25 | 77 | 0.39 | 1.02 | 76 | 0.31 NS |
| Right MDI: MBL during the 1st year             | 0.20 | 77 | 0.40 |      |    |         |
| Left MDI: MBL during the 2nd year              | 0.14 | 57 | 0.22 | 1.09 | 56 | 0.28 NS |
| Right MDI: MBL during the 2nd year             | 0.10 | 57 | 0.24 |      |    |         |
| Left MDI: MBL at the 2-year observation stage  | 0.34 | 57 | 0.55 | 1.83 | 56 | 0.58 NS |
| Right MDI: MBL at the 2-year observation stage | 0.25 | 57 | 0.58 |      |    |         |

Figure 19 shows the mean values of mini-implant marginal bone loss with **standard deviations** for the right-side MDIs.

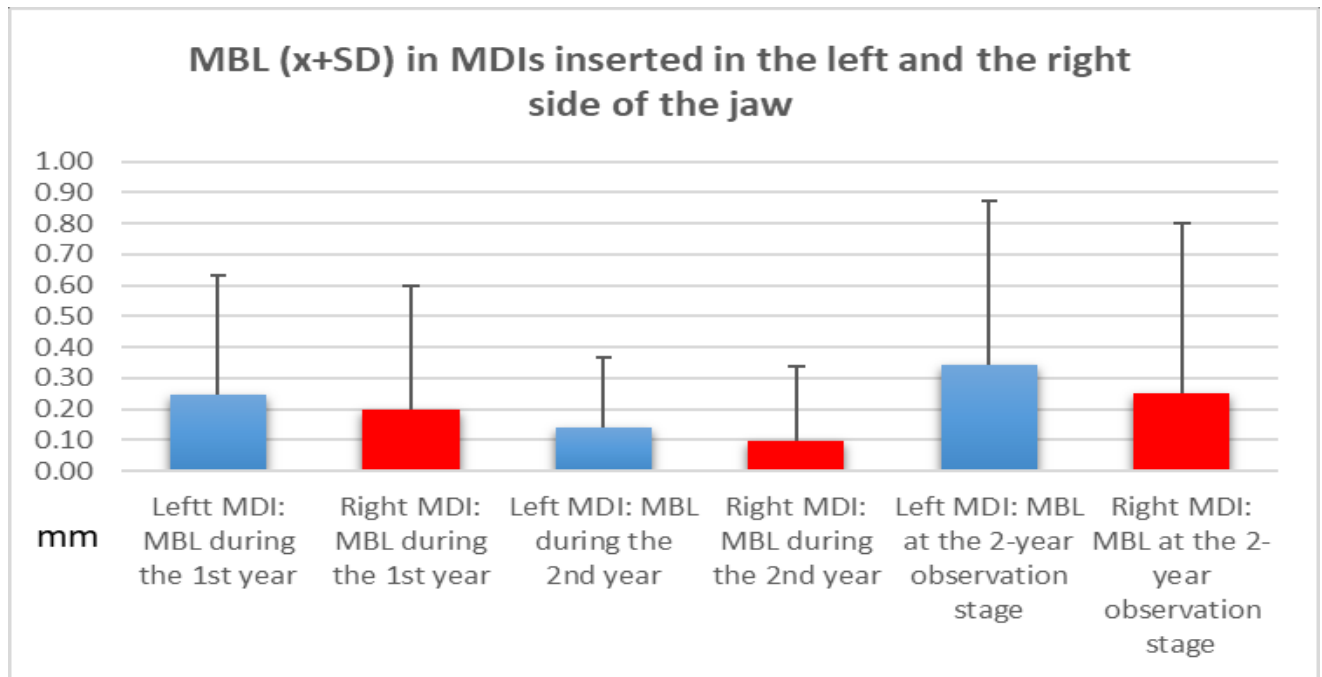


Fig. 19. Mean mini-implant marginal bone loss (MBL) with **standard deviations** in the right and the left mini-implants

The mean mini-implant marginal bone loss values on the left and the right side of the jaw and the significance of the differences of the mean marginal bone loss between the first and the second year of RPD wearing (MDI loading) for the left- and the right-side inserted MDIs are presented in table 6. Although the rate of mini-implant marginal bone loss in the second year was lower than in the first year, there were no statistically significant differences ( $p>0.05$ ), neither for the left-side MDIs nor for the right-side MDIs (related sample t-test) in the rate of marginal bone loss (table 6).

Table 6. Significance of the difference for mean marginal bone loss (MBL) between the 1<sup>st</sup> and the 2<sup>nd</sup> year of loading; N = number. x= mean value. SD = standard deviation. SE = standard error. t= t value. DF= degree of Freedom. p= significance (p-value); NS= not significant

|                         | x    | N  | SD   | SE   | t    | df | p       |
|-------------------------|------|----|------|------|------|----|---------|
| <b>Left MDI</b>         |      |    |      |      |      |    |         |
| <b>MBL 1st year :</b>   | 0.21 | 57 | 0.38 | 0.05 |      |    |         |
| <b>MBL the 2nd year</b> | 0.14 | 57 | 0.23 | 0.03 | 1.48 | 56 | 0.14 NS |
| <b>Right MDI</b>        |      |    |      |      |      |    |         |
| <b>MBL 1st year :</b>   | 0.16 | 57 | 0.33 | 0.04 | 1.14 | 54 | 0.26 NS |
| <b>MBL 2nd year</b>     | 0.10 | 57 | 0.25 | 0.03 |      |    |         |

The mean mini-implant marginal bone loss on the left and the right side of the jaw in the 1<sup>st</sup> and the 2<sup>nd</sup> year of RPD wearing (loading) are shown in Figure 20 ( $\bar{x} \pm SD$ ).

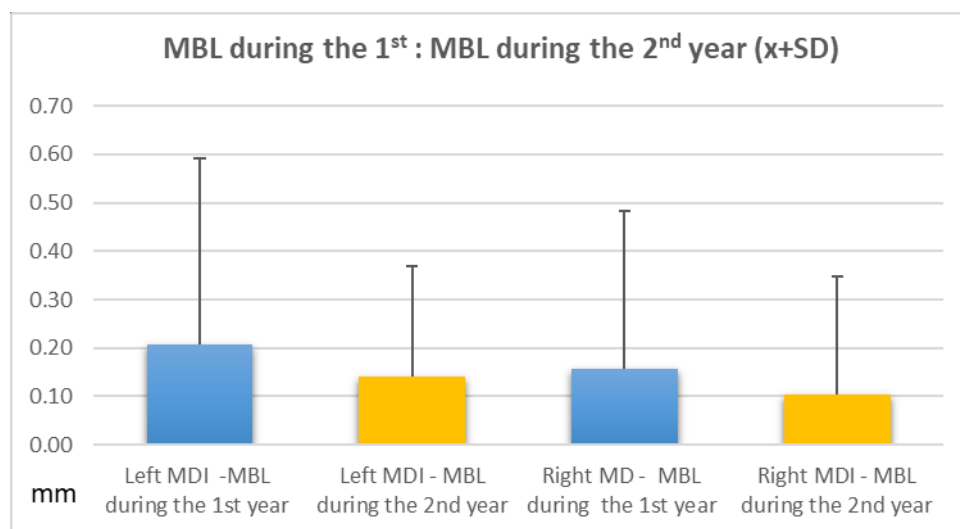


Fig. 20. Mean mini-implant marginal bone loss ( $\bar{x} \pm SD$ ) for the left and the right MDIs during the 1<sup>st</sup> and during the 2<sup>nd</sup> year in function

As there were no significant differences ( $p>0.05$ ) between the left- and the right-side MDIs, the mean value of the marginal bone loss was computed and presented in Table 7.

Mean marginal bone loss is presented for the period during the 1<sup>st</sup> year of MDI loading as well as for the period during the 2<sup>nd</sup> year of MDI loading (RPD wearing). Although the rate of marginal bone loss was higher during the 1<sup>st</sup> year, there was no statistically significant difference of marginal bone loss between the 1<sup>st</sup> and the 2<sup>nd</sup> year of loading ( $p>0.05$ . paired t-test).

Mean values of marginal bone loss in the 1<sup>st</sup> and the 2<sup>nd</sup> year are also presented graphically in Figure 21 ( $\bar{x} \pm SD$ ).

Table 7. Significance of the difference of mean marginal bone loss (MBL) between the 1<sup>st</sup> and the 2<sup>nd</sup> year of loading; N = number,  $\bar{x}$  = mean value, SD = standard deviation, t = t value. DF = degree of Freedom, p = significance (p-value); NS = not significant

| Variable               | X (mm) | N  | SD   | SE   | t     | df | p        |
|------------------------|--------|----|------|------|-------|----|----------|
| Mean MBL<br>1st year : | 0.18   | 57 | 0.93 | 0.04 | 1.901 | 56 | 0.062 NS |
| Mean MBL<br>2nd year   | 0.12   | 57 | 0.18 | 0.02 |       |    |          |

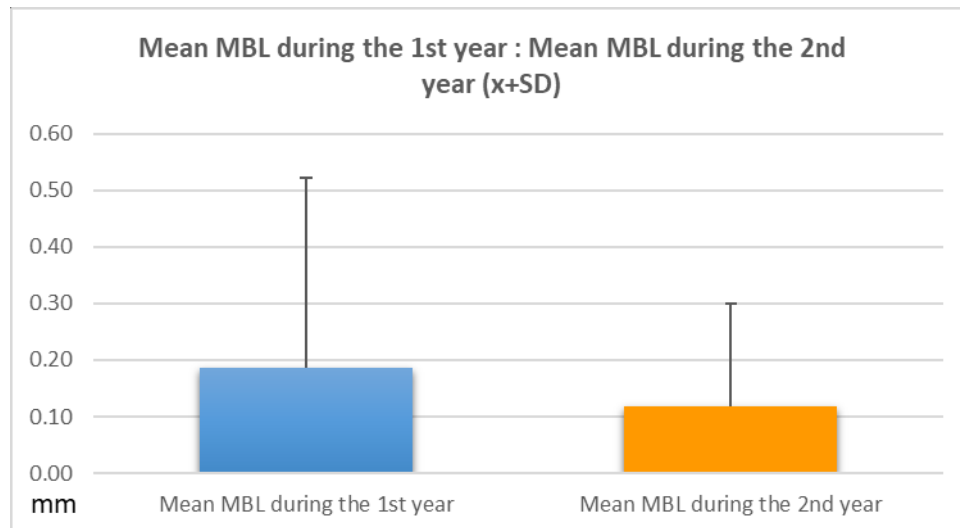


Fig. 21. Mean mini-implant marginal bone loss (x+SD) during the 1<sup>st</sup> and the 2<sup>nd</sup> year

Figure 22 presents graphically mean values of mini-implant marginal bone loss during the 1<sup>st</sup> year of loading, during the 2<sup>nd</sup> year of loading, as well as at the 2-year observation stage.

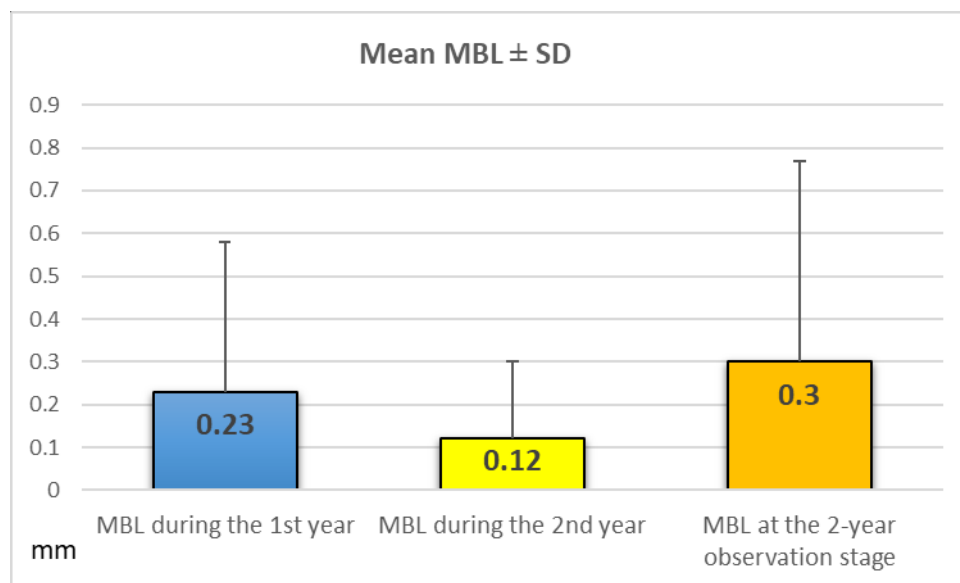


Fig. 22. Mean mini-implant marginal bone loss of mini-implants in Kennedy Class I RPD wearers



Mean values of mini-implant marginal bone loss dependent on the jaw of insertion (maxilla vs. mandible) with a significance of the difference between the jaws are presented in Table 8. Independent sample t-test showed that there were no significant differences between the mandible and the maxilla, nor during the 1<sup>st</sup> and the 2<sup>nd</sup> year of loading, neither the entire 2-year period of observation.

Table 8. Mean marginal bone loss (MBL) dependent on the jaw of insertion (**Maxilla vs. Mandible**) with significance of the difference between the mean values; N = number of patients, x= arithmetic mean, SD = standard deviation, SE = standard error, t= t value, DF= degree of Freedom, p= significance (p-value); NS= not significant

| Variable  | Jaw of insertion | N         | x           | SD          | SE          | t             | DF        | p              |
|---|------------------|-----------|-------------|-------------|-------------|---------------|-----------|----------------|
| <b>Mini-implant marginal bone loss during the 1<sup>st</sup> year</b> | <b>Mandible</b>  | <b>53</b> | <b>0.22</b> | <b>0.32</b> | <b>0.04</b> | <b>-.111</b>  | <b>75</b> | <b>.912 NS</b> |
|   | <b>Maxilla</b>   | <b>24</b> | <b>0.23</b> | <b>0.42</b> | <b>0.09</b> |               |           |                |
| <b>MBL during the 2<sup>nd</sup> year</b>                             | <b>Mandible</b>  | <b>35</b> | <b>0.10</b> | <b>0.14</b> | <b>0.03</b> | <b>-1.064</b> | <b>55</b> | <b>.292 NS</b> |
|   | <b>Maxilla</b>   | <b>22</b> | <b>0.15</b> | <b>0.23</b> | <b>0.05</b> |               |           |                |
| <b>Mean MBL at the 2-year observation stage</b>                       | <b>Mandible</b>  | <b>35</b> | <b>0.26</b> | <b>0.34</b> | <b>0.06</b> | <b>-.924</b>  | <b>55</b> | <b>.360 NS</b> |
|   | <b>Maxilla</b>   | <b>22</b> | <b>0.37</b> | <b>0.63</b> | <b>0.13</b> |               |           |                |
| <b>Left MDI: mean MBL during the 1<sup>st</sup> year</b>              | <b>Mandible</b>  | <b>53</b> | <b>0.24</b> | <b>0.34</b> | <b>0.05</b> | <b>-.013</b>  | <b>77</b> | <b>.990 NS</b> |
|   | <b>Maxilla</b>   | <b>26</b> | <b>0.24</b> | <b>0.48</b> | <b>0.09</b> |               |           |                |
| <b>Right MDI: mean MBL during the 1<sup>st</sup> year</b>             | <b>Mandible</b>  | <b>55</b> | <b>0.24</b> | <b>0.46</b> | <b>0.06</b> | <b>.298</b>   | <b>77</b> | <b>.766 NS</b> |
|   | <b>Maxilla</b>   | <b>24</b> | <b>0.21</b> | <b>0.42</b> | <b>0.09</b> |               |           |                |
| <b>Left MDI: mean MBL during the 2<sup>nd</sup> year</b>              | <b>Mandible</b>  | <b>35</b> | <b>0.15</b> | <b>0.23</b> | <b>0.04</b> | <b>-.024</b>  | <b>57</b> | <b>.981 NS</b> |
|   | <b>Maxilla</b>   | <b>24</b> | <b>0.15</b> | <b>0.24</b> | <b>0.05</b> |               |           |                |
| <b>Right MDI: mean MBL during the 2<sup>nd</sup> year</b>             | <b>Mandible</b>  | <b>35</b> | <b>0.06</b> | <b>0.13</b> | <b>0.02</b> | <b>-1.683</b> | <b>55</b> | <b>.098 NS</b> |
|   | <b>Maxilla</b>   | <b>22</b> | <b>0.16</b> | <b>0.35</b> | <b>0.07</b> |               |           |                |
| <b>Left MDI: mean MBL 2-years observation stage</b>                   | <b>Mandible</b>  | <b>35</b> | <b>0.30</b> | <b>0.39</b> | <b>0.07</b> | <b>-.797</b>  | <b>57</b> | <b>.429 NS</b> |
|   | <b>Maxilla</b>   | <b>24</b> | <b>0.41</b> | <b>0.69</b> | <b>0.14</b> |               |           |                |
| <b>Right MDI: mean MBL 2-year observation stage</b>                   | <b>Mandible</b>  | <b>35</b> | <b>0.22</b> | <b>0.35</b> | <b>0.06</b> | <b>-1.015</b> | <b>55</b> | <b>.314 NS</b> |
|   | <b>Maxilla</b>   | <b>22</b> | <b>0.33</b> | <b>0.59</b> | <b>0.12</b> |               |           |                |

Figure 23 shows mean mini-implant marginal bone loss values (with standard deviations) in mini-implants in Kennedy Class I RPD wearers in the mandible and the maxilla during the 1<sup>st</sup>, the 2<sup>nd</sup> year, and during the entire 2-year period of loading.

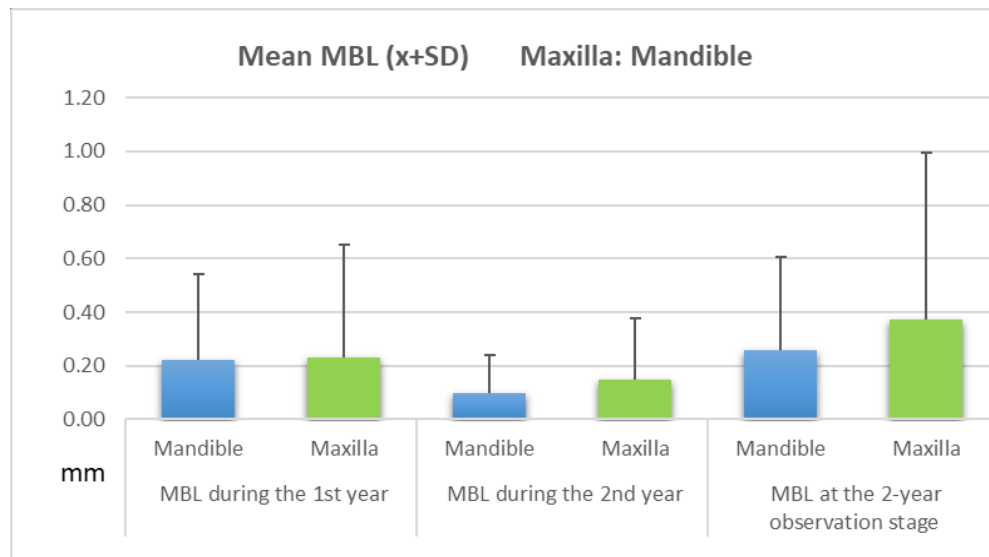


Fig. 23. Mean mini-implant marginal bone loss values with SDs observed in MDIs in Kennedy Class I RPD wearers inserted in the mandible and the maxilla

Mean MDIs mini-implant marginal bone loss in Kennedy Class I RPD wearers dependent on the status of the antagonistic jaw (CD=complete dentures. RPD=removable partial dentures. FPD= fixed partial denture) is presented in Table 9.

Table 9. Mean marginal bone loss (MBL) of mini-implant (MDI) in Kennedy Class I removable partial dentures (RPD) wearers dependent on the status of the antagonistic jaw (CD=complete dentures. RPD=removable partial dentures. FPD= fixed partial denture); N = number of patients, x= mean value, SD = standard deviation, SE = standard error

| Variable                            |                      | N  | x (mm)      | SD   | SE   | Minimum | Maximum |
|-------------------------------------|----------------------|----|-------------|------|------|---------|---------|
| <b>Mean MBL after 1 year</b>        | CD                   | 28 | <b>0.17</b> | 0.21 | 0.04 | 0.00    | 0.55    |
|                                     | RPD                  | 33 | <b>0.23</b> | 0.39 | 0.07 | 0.00    | 1.55    |
|                                     | Natural teeth or FPD | 16 | <b>0.32</b> | 0.45 | 0.11 | 0.00    | 1.40    |
|                                     | Total                | 77 | <b>0.22</b> | 0.35 | 0.04 | 0.00    | 1.55    |
| <b>Mean MBL during the 2nd year</b> | CD                   | 18 | <b>0.09</b> | 0.14 | 0.04 | 0.00    | 0.40    |
|                                     | RPD                  | 29 | <b>0.17</b> | 0.21 | 0.04 | 0.00    | 0.63    |
|                                     | Natural teeth or FPD | 10 | <b>0.02</b> | 0.04 | 0.01 | 0.00    | 0.10    |
|                                     | Total                | 55 | <b>0.12</b> | 0.18 | 0.02 | 0.00    | 0.63    |
| <b>Mean MBL after 2 years</b>       | CD                   | 18 | <b>0.18</b> | 0.26 | 0.07 | 0.00    | 0.78    |
|                                     | RPD                  | 29 | <b>0.40</b> | 0.60 | 0.11 | 0.00    | 2.10    |
|                                     | Natural teeth or FPD | 10 | <b>0.19</b> | 0.24 | 0.08 | 0.00    | 0.63    |
|                                     | Total                | 57 | <b>0.30</b> | 0.47 | 0.06 | 0.00    | 2.10    |

The significance of the differences in mean values of mini-implant marginal bone loss dependent on the status of the antagonistic jaw is presented in Table 10 (One-way ANOVA). There were no significant differences in mean mini-implant marginal bone loss dependent on the dental status of the antagonistic jaws, nor during the 1<sup>st</sup> and the 2<sup>nd</sup> year of RPD wearing (MDI loading), neither during the overall 2-year period ( $P>0.05$ ; one-way ANOVA).

Table 10. Significance of the differences (One-Way ANOVA) dependent on the status of the antagonistic jaw; df = degree of freedom. F= F value. p= p-value

| <i>Variable</i>                            |                | <i>Sum of Squares</i> | <i>df</i> | <i>Mean Square</i> | <i>F</i> | <i>Sig. (p)</i> |
|--|----------------|-----------------------|-----------|--------------------|----------|-----------------|
| <b><i>Mean MBL after 1 year</i></b>        | Between Groups | 0.247                 | 2         | .124               | 1.01     | .370 NS         |
|  | Within Groups  | 9.081                 | 74        | .123               |          |                 |
|  | Total          | 9.329                 | 76        |                    |          |                 |
| <b><i>Mean MBL during the 2nd year</i></b> | Between Groups | 0.184                 | 2         | .092               | 2.95     | .061 NS         |
|  | Within Groups  | 1.618                 | 54        | .031               |          |                 |
|  | Total          | 1.802                 | 56        |                    |          |                 |
| <b><i>Mean MBL after 2 years</i></b>       | Between Groups | 0.592                 | 2         | .360               | 1.32     | .195 NS         |
|  | Within Groups  | 11.616                | 54        | .213               |          |                 |
|  | Total          | 12.208                | 56        |                    |          |                 |

Figure 24 ( $\bar{x} \pm SD$ ) presents graphically mean values of the amount of mini-implant marginal bone loss dependent on the dental status of the antagonistic jaw.

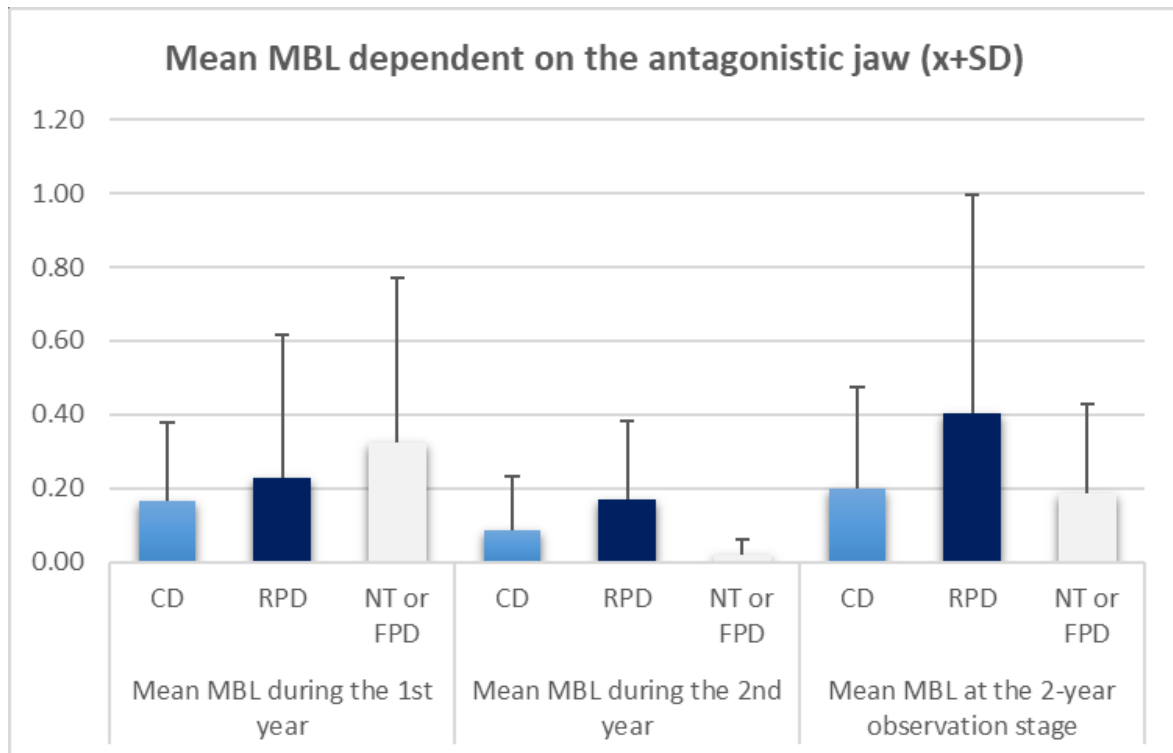


Fig. 24. Mean mini-implant marginal bone loss values with standard deviations in Kennedy Class I RPD wearers dependent on the status of the antagonistic jaws

Mean mini-implant marginal bone loss in Kennedy Class I RPD wearers dependent on the **age group** of patients (<60 years, 61-70 years and > 70 years) is presented in Table 11.

Table 11. Mean marginal bone loss (MBL) in different age groups; N = number. x= mean value. SD = standard deviation. SE = standard error

| Variable  | Age group | N  | X (mm)      | SD   | SE   | Minimum | Maximum |
|---|-----------|----|-------------|------|------|---------|---------|
| <b>Mean MBL during the 1<sup>st</sup> year</b>  | <60       | 16 | <b>0.34</b> | 0.19 | 0.05 | 0.00    | 0.63    |
|   | 61-70     | 42 | <b>0.25</b> | 0.43 | 0.07 | 0.00    | 1.55    |
|   | >70       | 19 | <b>0.07</b> | 0.15 | 0.03 | 0.00    | 0.45    |
|   | Total     | 77 | <b>0.22</b> | 0.35 | 0.04 | 0.00    | 1.55    |
| <b>Mean MBL during the 2<sup>nd</sup> year</b>  | <60       | 10 | <b>0.18</b> | 0.24 | 0.08 | 0.00    | 0.63    |
|   | 61-70     | 30 | <b>0.13</b> | 0.18 | 0.03 | 0.00    | 0.58    |
|   | >70       | 17 | <b>0.06</b> | 0.13 | 0.03 | 0.00    | 0.40    |
|   | Total     | 55 | <b>0.12</b> | 0.18 | 0.02 | 0.00    | 0.63    |
| <b>Mean MBL at the 2-year observation stage</b> | <60       | 10 | <b>0.49</b> | 0.32 | 0.10 | 0.10    | 1.00    |
|   | 61-70     | 30 | <b>0.36</b> | 0.60 | 0.11 | 0.00    | 2.10    |
|   | >70       | 17 | <b>0.08</b> | 0.14 | 0.03 | 0.00    | 0.40    |
|   | Total     | 55 | <b>0.30</b> | 0.48 | 0.06 | 0.00    | 2.10    |

The significance of the differences in mean values of mini-implant marginal bone loss dependence on the age group is presented in Table 12 (One-way ANOVA). Although the rate of marginal bone loss was higher in younger patients (Table 11), there were no significant differences in mean marginal bone loss depending on the age group, nor during the 1<sup>st</sup> and the 2<sup>nd</sup> year of RPD wearing, neither during the overall period ( $P>0.05$ ; one-way ANOVA. Table 12). However, the mean marginal bone loss in younger patients almost reached the level of significance during the first year and the overall 2-year period of observation (Table 12;  $p=0.052$ ).

Table 12. Significance of the differences (One-Way ANOVA) between different age groups

F= f value; df=degree of freedom. p=p value

| Variable  |                | Sum of Squares | df | Mean Square | F     | Sig. (p) |
|---|----------------|----------------|----|-------------|-------|----------|
| <b>Mean MBL during the 1<sup>st</sup> year</b>  | Between Groups | 0.713          | 2  | .356        | 3.074 | .052 NS  |
|   | Within Groups  | 8.576          | 74 | .116        |       |          |
|   | Total          | 9.289          | 76 |             |       |          |
| <b>Mean MBL during the 2<sup>nd</sup> year</b>  | Between Groups | 0.104          | 2  | .052        | 1.669 | .198 NS  |
|   | Within Groups  | 1.688          | 52 | .031        |       |          |
|   | Total          | 1.793          | 54 |             |       |          |
| <b>Mean MBL at the 2-year observation stage</b> | Between Groups | 1.277          | 2  | .639        | 3.148 | .051 NS  |
|   | Within Groups  | 10.956         | 54 | .203        |       |          |
|   | Total          | 12.234         | 56 |             |       |          |

Figure 25 ( $\bar{x} \pm SD$ ) shows a graphical presentation of mean values of mini-implant marginal bone loss depending on the age group of the patients.



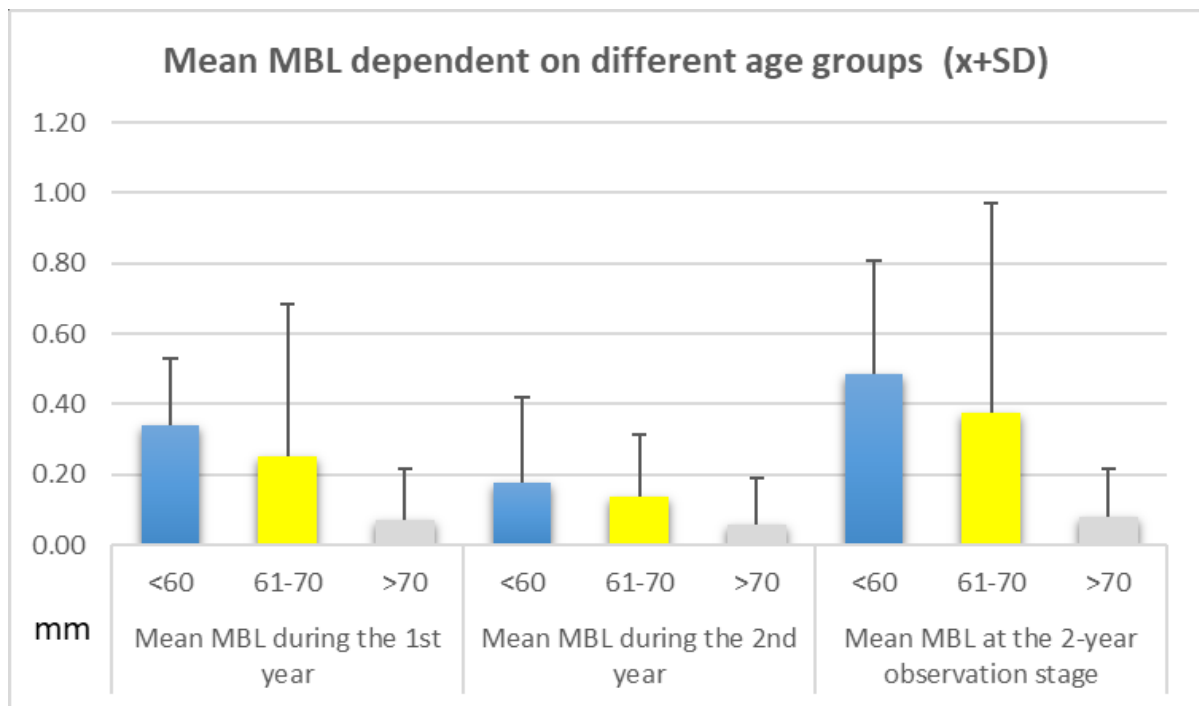


Fig. 25. Mean mini-implant marginal bone loss values with standard deviations in Kennedy Class I RPD wearers in different age groups

The mean mini-implant marginal bone loss values in different gender and the significance of the differences (tested by the Independent t-test) between the mean values are presented in Table 13.

Table 13. Mean marginal bone loss (MBL) in female and male patients with significance of the difference between gender; N = number. x= mean value. SD = standard deviation. SE = standard error. t= t value. DF= degree of Freedom. p= significance (p value); NS= not significant

| Variable  | Gender | N  | x           | SD   | SE   | t    | df | p       |
|---|--------|----|-------------|------|------|------|----|---------|
| <b>Mean MBL during the 1<sup>st</sup> year</b>  | Female | 61 | <b>0.26</b> | 0.37 | 0.05 | 1.76 | 75 | 0.08 NS |
|   | Male   | 16 | <b>0.08</b> | 0.20 | 0.05 |      |    |         |
| <b>Mean MBL during the 2<sup>nd</sup> year</b>  | Female | 45 | <b>0.13</b> | 0.20 | 0.03 | 1.11 | 57 | 0.27 NS |
|   | Male   | 16 | <b>0.06</b> | 0.09 | 0.03 |      |    |         |
| <b>Mean MBL at the 2-year observation stage</b> | Female | 45 | <b>0.33</b> | 0.50 | 0.07 | 0.96 | 57 | 0.34 NS |
|   | Male   | 16 | <b>0.17</b> | 0.32 | 0.10 |      |    |         |

Graphical presentation of mean mini-implant MBL values and standard deviations ( $x \pm SD$ ) in male and female patients are presented in Fig. 26. Although females had higher rates of mini-implant MBL, it was not statistically significant ( $p > 0.05$ ; Table 13).

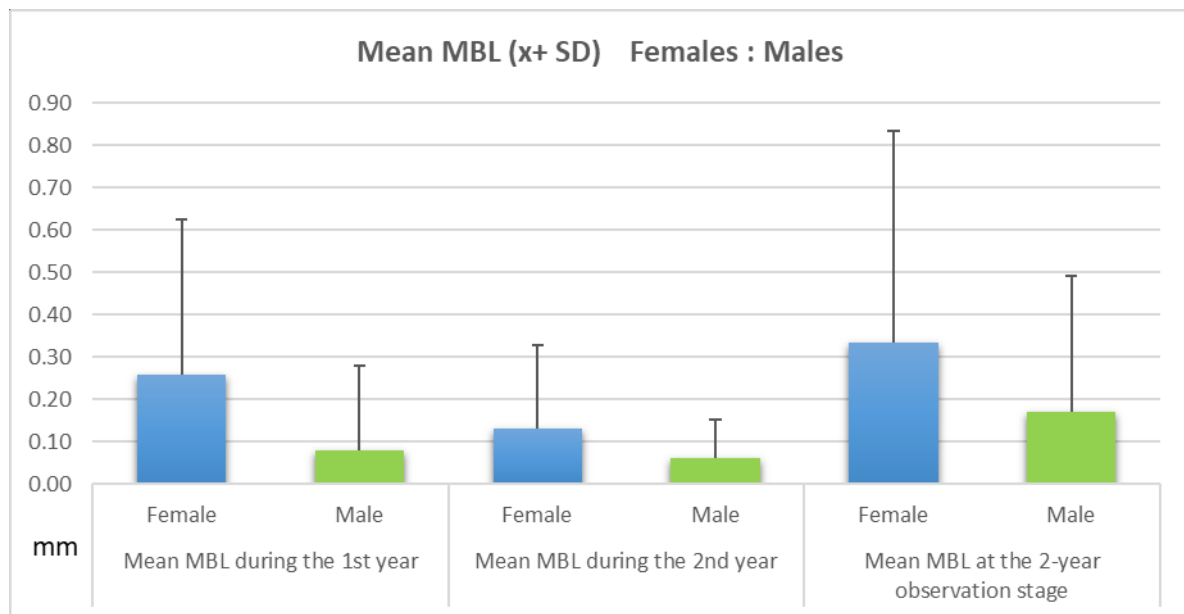


Fig. 26. Mean mini-implant marginal bone loss values with standard deviations in Kennedy Class I RPD wearers in different gender

To obtain the combined effect of different factors that might influence the rate of mini-implant marginal bone loss in mini-implants, it was decided to analyze the impact of two independent factors: gender and jaw of insertion and effect of age as a continuous variable, i.e., a covariate. Therefore, multivariate analysis (the general linear model was performed, i.e., ANCOVA analysis). Dependent continuous variables were mini-implant marginal bone loss at the 1-year observation stage and mini-implant marginal bone loss at the 2-year observation stage. Factors were: Gender and Jaw of insertion (categorical factors) and Age of patients (continuous variable, entered into the model as a covariate). The results of the ANCOVA are presented in Table 14.

Table 14. General linear model: effects of age (as a continuous variable - covariate). and gender and jaw of insertion (as independent factors) on mean marginal bone loss (MBL) after one year and after two years in function; df=degree of freedom; p=p value

### Tests of Between-Subjects Effects

| Source          | Dependent Variable | Type III Sum of Squares | df | Mean Square | F value | Sig. (p) |
|-----------------|--------------------|-------------------------|----|-------------|---------|----------|
| Corrected Model | MBL 1-year         | 1.188 <sup>a</sup>      | 4  | .297        | 3.120   | .022 *   |
|                 | MBL 2-years        | 2.191 <sup>b</sup>      | 4  | .548        | 2.836   | .033 *   |
| Intercept       | MBL 1-year         | 1.077                   | 1  | 1.077       | 11.321  | .001 **  |
|                 | MBL 2-years        | 1.884                   | 1  | 1.884       | 9.757   | .003 **  |
| Age             | MBL 1-year         | .883                    | 1  | .883        | 9.285   | .004 **  |
|                 | MBL 2-years        | 1.462                   | 1  | 1.462       | 7.571   | .008 **  |
| Gender          | MBL 1-year         | .001                    | 1  | .001        | .009    | .925 NS  |
|                 | MBL 2-years        | .027                    | 1  | .027        | .140    | .710 NS  |
| Jaw             | MBL 1-year         | .036                    | 1  | .036        | .382    | .539 NS  |
|                 | MBL 2-years        | .030                    | 1  | .030        | .154    | .697 NS  |
| Gender * Jaw    | MBL 1-year         | .523                    | 1  | .523        | 5.496   | .023 *   |
|                 | MBL 2-years        | .921                    | 1  | .921        | 4.769   | .034 *   |
| Error           | MBL 1-year         | 4.948                   | 52 | .095        |         |          |
|                 | MBL 2-years        | 10.042                  | 52 | .193        |         |          |
| Total           | MBL 1-year         | 8.006                   | 57 |             |         |          |
|                 | MBL 2-years        | 17.304                  | 57 |             |         |          |
| Corrected Total | MBL 1-year         | 6.135                   | 56 |             |         |          |
|                 | MBL 2-years        | 12.234                  | 56 |             |         |          |

a. R Squared = .194 (Adjusted R Squared = .132)

b. R Squared = .179 (Adjusted R Squared = .116)

The effects were similar in both dependent variables: the 1-year mini-implant marginal bone loss and the 2-year marginal bone loss. Gender and jaw of insertion showed no significant impact on the rate of marginal bone loss (nor for the 1<sup>st</sup> year, neither for the 2<sup>nd</sup> year of loading;  $p>0.05$ ), while age, as a continuous variable (covariate), showed significant effect on the amount of the 1- year and the 2-year mini-implant marginal bone loss (younger patients had a higher marginal bone loss than older patients.  $p<0.01$ . Table 14).

To obtain jointed effect of all 3 independent factors that might influence the rate of mini-implant mini-implant marginal bone loss, it was decided to analyze the impact of all three factors: gender (female, male), jaw of insertion (mandible, maxilla), and antagonistic jaw, (CD or RPD, natural teeth or FPD) and an effect of age as a continuous variable: covariate. Therefore, multivariate analysis (the general linear model was performed. i.e., ANCOVA analysis). Dependent continuous variables were mini-implant marginal bone loss at the 1-year observation stage and mini-implant marginal bone loss at the 2-year observation stage. The three factors were: Gender, Jaw of insertion, and Antagonistic jaw (categorical factors). Age was a continuous variable (a covariate). The results of the ANCOVA are presented in Table 15.

The effects of three factors (gender, the jaw of insertion, and the dental status of the antagonistic jaw) were almost similar on both observed dependent variables: the 1-year mini-implant marginal bone loss and the 2-year mini-implant mini-implant marginal bone loss. Gender, jaw of insertion, and antagonistic jaw showed no significant effects on the rate of marginal bone loss (nor for the 1<sup>st</sup> year, neither for the 2<sup>nd</sup> year of loading;  $p>0.05$ ), while age as a continuous variable (covariate) showed significant effect on the amount of the 1- year ( $p=0.01$ ) and the 2-year mini-implant marginal bone loss ( $p<0.05$ ; Table 15).

Table 15. General linear model: effects of age (continuous variable - covariate), and gender, the jaw of insertion, and antagonistic jaw (independent factors) on mean marginal bone loss (MBL) after one year and after two years in function; df=degree of freedom; p=p value

### Tests of Between-Subjects Effects

| Source                          | Dependent Variable | Type III Sum of Squares | df | Mean Square | F     | Sig.    |
|---------------------------------|--------------------|-------------------------|----|-------------|-------|---------|
| Corrected Model                 | MBL 1 year         | 1.370 <sup>a</sup>      | 9  | .152        | 1.502 | .175 NS |
|                                 | MBL 2 years        | 2.838 <sup>b</sup>      | 9  | .315        | 1.577 | .150 NS |
| Intercept                       | MBL 1 year         | .851                    | 1  | .851        | 8.392 | .006 ** |
|                                 | MBL 2 years        | 1.489                   | 1  | 1.489       | 7.451 | .009 ** |
| Age                             | MBL 1 year         | .722                    | 1  | .722        | 7.122 | .010 ** |
|                                 | MBL 2 years        | 1.222                   | 1  | 1.222       | 6.112 | .017 *  |
| Gender                          | MBL 1 year         | .029                    | 1  | .029        | .290  | .593 NS |
|                                 | MBL 2 years        | .064                    | 1  | .064        | .320  | .574 NS |
| Jaw                             | MBL 1 year         | .001                    | 1  | .001        | .013  | .908 NS |
|                                 | MBL 2 years        | .002                    | 1  | .002        | .011  | .918 NS |
| Antagonistic jaw                | MBL 1 year         | .065                    | 2  | .032        | .320  | .728 NS |
|                                 | MBL 2 years        | .420                    | 2  | .210        | 1.051 | .358 NS |
| Gender * Jaw                    | MBL 1 year         | .215                    | 1  | .215        | 2.120 | .152 NS |
|                                 | MBL 2 years        | .271                    | 1  | .271        | 1.353 | .251 NS |
| Gender * Antagonistic jaw       | MBL 1 year         | .034                    | 1  | .034        | .338  | .564 NS |
|                                 | MBL 2 years        | .025                    | 1  | .025        | .126  | .724 NS |
| Jaw * Antagonistic jaw          | MBL 1 year         | .031                    | 2  | .016        | .155  | .857 NS |
|                                 | MBL 2 years        | .094                    | 2  | .047        | .235  | .792 NS |
| Gender * Jaw * Antagonistic jaw | MBL 1 year         | .000                    | 0  | .           | .     | .       |
|                                 | MBL 2 years        | .000                    | 0  | .           | .     | .       |
| Error                           | MBL 1 year         | 4.765                   | 47 | .101        |       |         |
|                                 | MBL 2 years        | 9.395                   | 47 | .200        |       |         |
| Total                           | MBL 1 year         | 8.006                   | 57 |             |       |         |
|                                 | MBL 2 years        | 17.304                  | 57 |             |       |         |
| Corrected Total                 | MBL 1 year         | 6.135                   | 56 |             |       |         |
|                                 | MBL 2 years        | 12.234                  | 56 |             |       |         |

a. R Squared = .223 (Adjusted R Squared = .075)

b. R Squared = .232 (Adjusted R Squared = .085)

#### ***4.2 Success and survival rates***

Survival rate (in 81 patients who responded) after the first year was 97.5% at the implant level (162 MDIs were inserted). A total of four MDIs were lost soon after loading; one mini-implant was lost in each of four different patients; two MDIs were lost in the mandible, and two MDIs were lost in the maxilla. None of the remaining MDIs had mini-implant marginal bone loss > than 2 mm, so the success rate was the same (97.5%) as the survival rate at the 1-year follow-up.

In the next year (2-years of mini-implants in function), no more MDIs were lost (observed in 61 patients who responded when recalled). In the respective 61 patients, both the survival and the success rates were 96.7% for the first year of function (at the implant level). After the 2-years in the function, the survival rate at the implant level was 96.7%, and the success rate at the implant level was 95.9% (61 patients. 122 implants).

At the patient level at the 1-year follow-up examination (81 patients) both, the success and the survival rates were 95.3%. For the 61 patients (who responded to the 2-year recall), the success and the survival rates were 93.4% at the patient level after the first year. After two years, the survival rate at the patient level was 93.4%, and the success rate at the patient level was 91.8% (61 patients). The median success and the survival times were 24 months for both, the mini-implant and the patient levels, respectively. Graphical presentation of the survival and the success rates at the implant level is shown in the survival plot in Figure 27a and 27b. Survival and the success rates at the patient level are shown in the survival plot in Figure 27c and 27d.

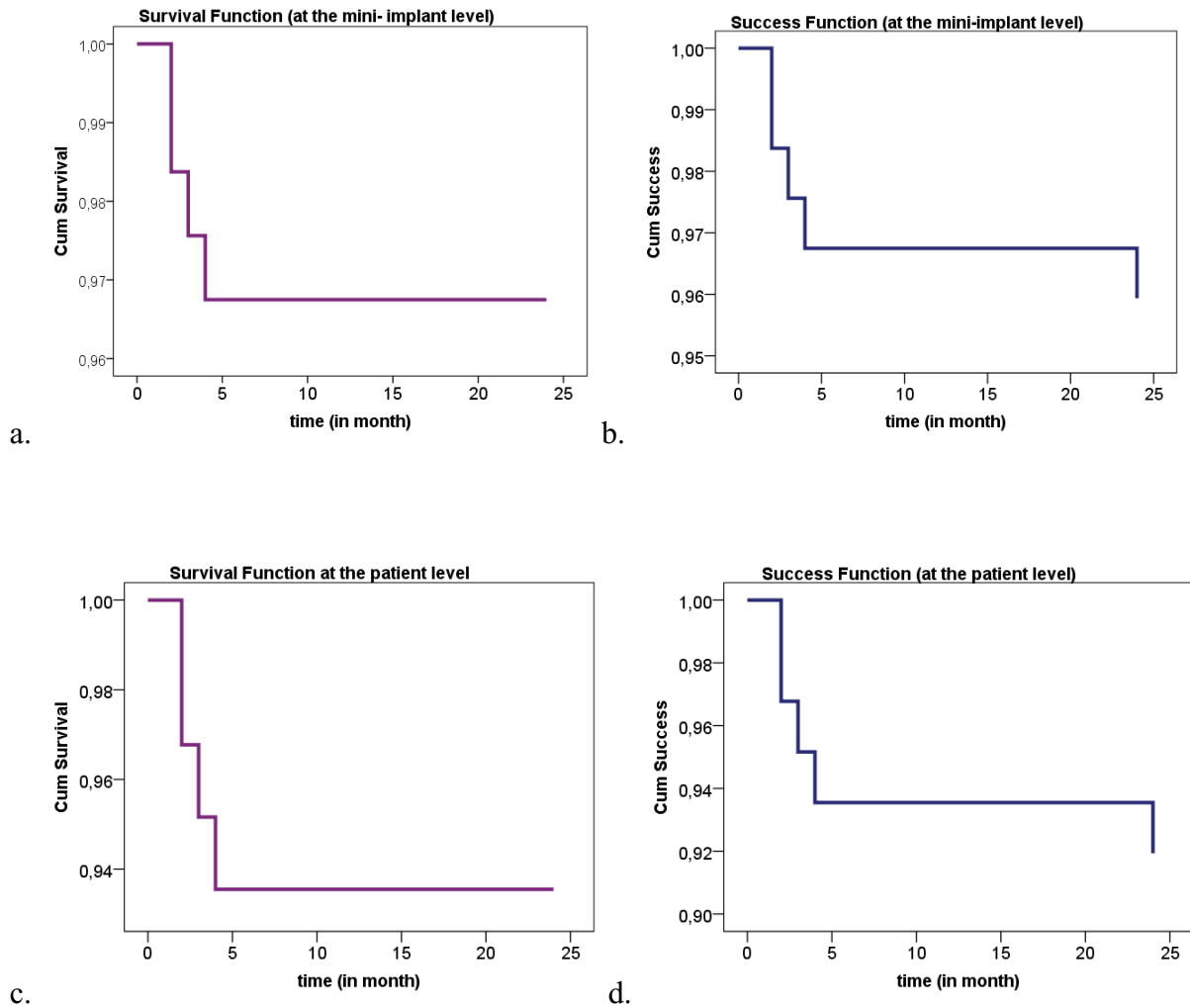


Fig. 27a-d. Survival (a) and success function (b) at the mini-implant level over the observation period of 24 months (2 years), and survival (c) and success plots (d) at the patient level over the 24-month observation

#### 4.2 Clinical assessment (Modified plaque and Modified Bleeding Index)

The MPI observed at the 1-year follow-up examination is shown in Figure 28. The MPI noted at the 2-year follow-up examination is shown in Figure 29.  $\chi^2$  non-parametric test for categorical variables showed a statistically significant difference in the degree of plaque index between the two observation periods ( $\chi^2 = 75.3$ ,  $df=6$ ,  $p<0.001$ ), as patients had more plaque at the 2-year observation stage, compared to the 1<sup>st</sup> year.

The MBI observed at the 1-year follow-up examination is shown in Figure 30, and the MBI observed at the 2-year follow-up examination is shown in Figure 31. There was a statistically



significant difference at the 95% probability level ( $p < 0.05$ ) in the degree of bleeding index between the 1<sup>st</sup> and the 2<sup>nd</sup> year ( $\chi^2 = 11.26$ ;  $df=4$ ,  $p=0.022$ ). A higher degree of bleeding on probing was recorded at the 2-year examination.

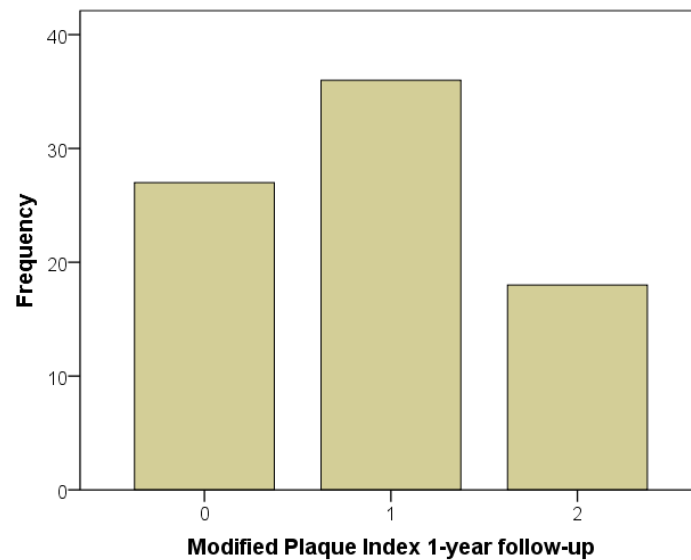


Fig. 28. Modified plaque index observed at the 1-year follow-up examination

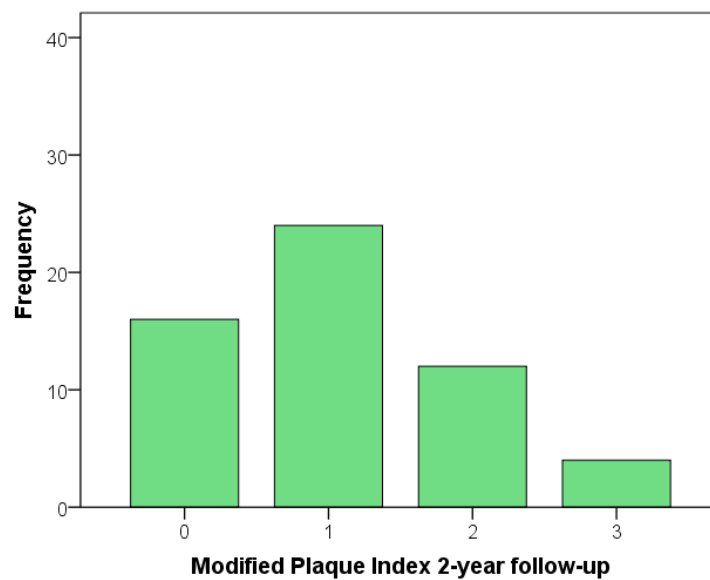


Fig. 29. Modified plaque index observed at the 2-year follow-up examination

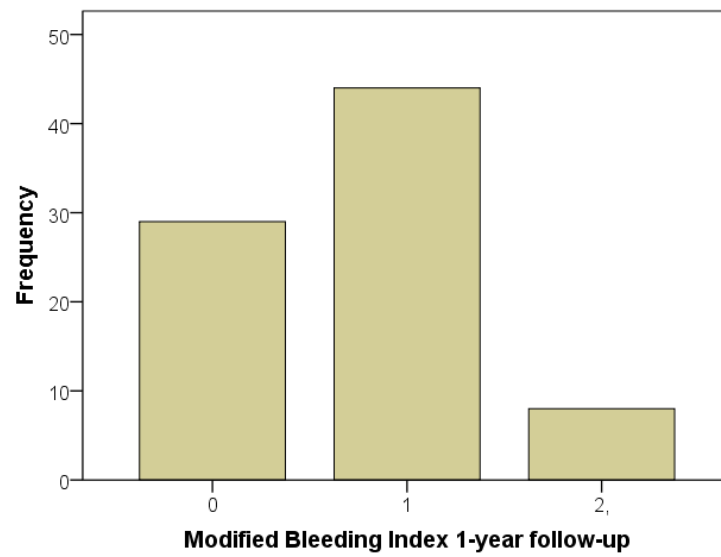


Fig. 30. Modified bleeding index observed at the 1-year follow-up examination

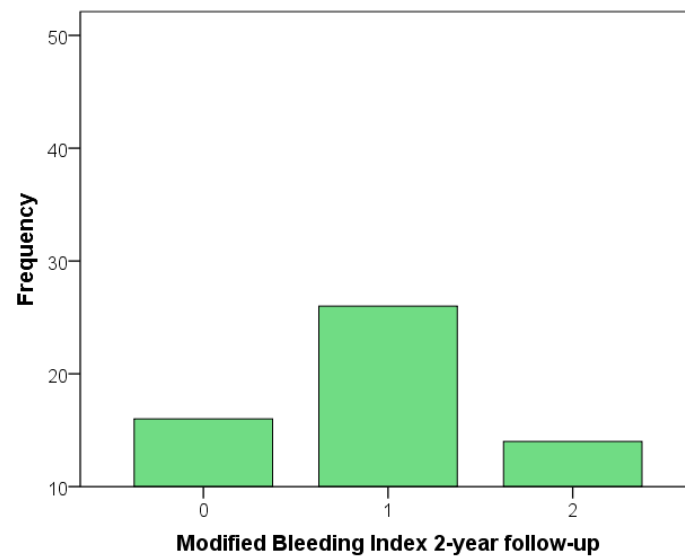


Fig. 31. Modified bleeding index observed at the 2-year follow-up examination

### 4.3 Dental patient-reported outcome measures (dPROMs): OHRQoL, OES, CFQ

#### 4.3.1. The effect size of a treatment

Summary scores of the questionnaires used for assessment of patient-centered outcome measures before and after the treatment, i.e., OES, the OHIP-14, and the CFQ are presented in Table 16.

Table 16. Summary scores of the Orofacial esthetic Scale (OES), the Oral Health Impact Profile (OHIP-14), and the Chewing Function Questionnaire (CFQ) before and after treatment and significance of the differences; N=number of Patients; SD=standard deviation. SE=standard error. t=t value. df=degree of freedom. p=p-value

| Variable |                  | Mean Summary Score | N  | SD   | SE   | t       | df | p         |
|----------|------------------|--------------------|----|------|------|---------|----|-----------|
| OES      | Before treatment | 18.09              | 84 | 6.80 | 0.76 | - 18.75 | 83 | <0.001 ** |
|          | After treatment  | 36.81              | 84 | 3.80 | 0.42 |         |    |           |
| OHIP-14  | Before treatment | 30.52              | 84 | 9.59 | 1.07 | 15.08   | 83 | <0.001 ** |
|          | After treatment  | 12.65              | 84 | 7.16 | 0.80 |         |    |           |
| CFQ      | Before treatment | 28.59              | 84 | 6.71 | 0.75 | 15.37   | 83 | <0.001 ** |
|          | After treatment  | 12.86              | 84 | 7.49 | 0.83 |         |    |           |

Arithmetic means of the summary scores of the OES with SDs before and after treatment are also shown graphically (Fig. 32). Summary scores increased after treatment (15 days after

new RPD was loaded, and all adjustments finished) and were almost double than before treatment and statistically significant ( $p < 0.01$ ). A higher score of the OES represented more satisfaction.

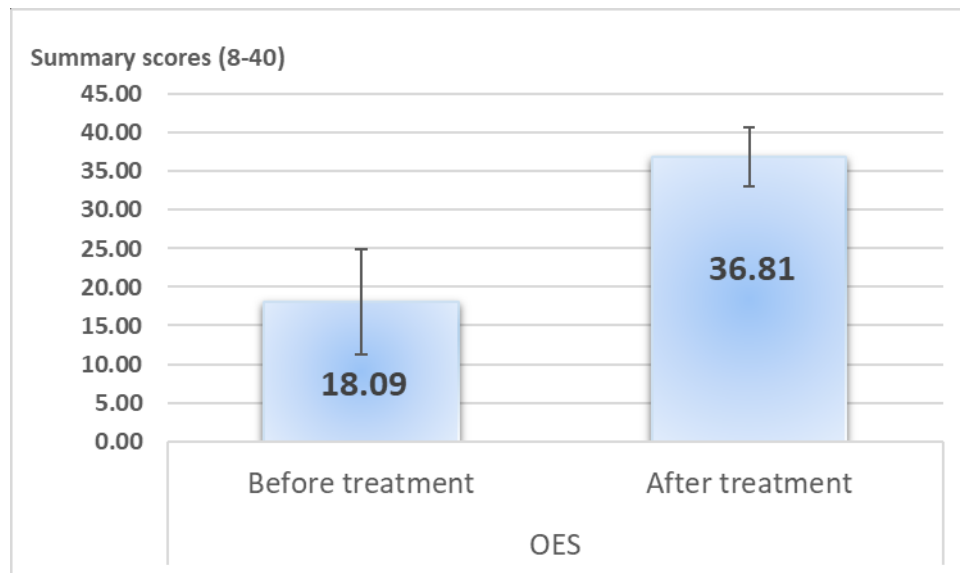


Fig. 32. Arithmetic means of the summary scores of the Orofacial esthetic Scale (OES) with standard deviations before and after treatment

The standardized effect size was calculated, and the treatment effect size was 2.75. According to Cohen (106), the effect size was large ( $> 0.8$ ).

Arithmetic means of the summary scores with SDs of the short form of the OHIP, consisting of 14 questions (OHIP-14), are shown graphically in Figure 33. Mean Summary scores dropped down significantly after the treatment, representing better self-reported oral health in patients who received MDI-RPD therapy ( $p < 0.01$ ). The standardized effect size for the OHIP was 1.86, also representing the large effect size (106).

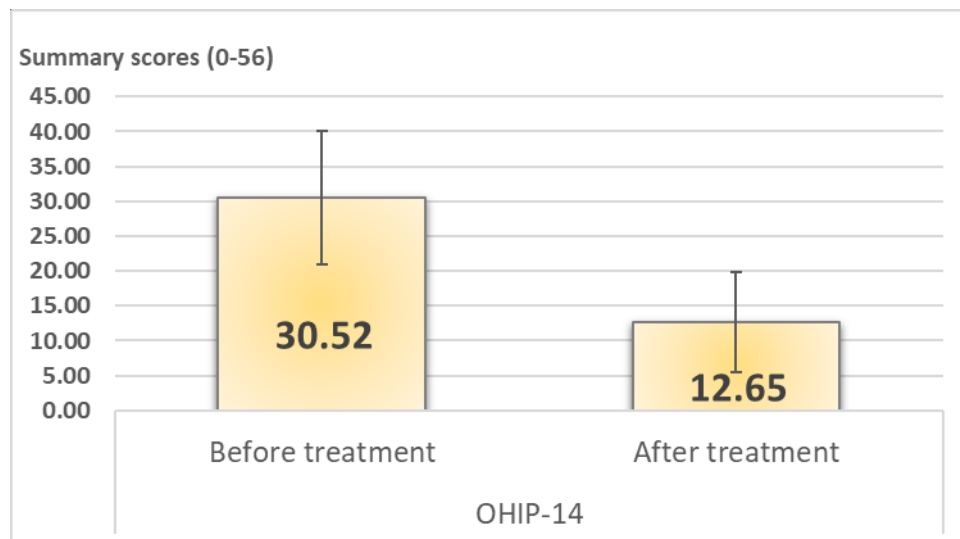


Fig. 33. Arithmetic means of the summary scores of the short form of Oral Health Impact Profile (OHIP-14) with standard deviations before and after treatment

Arithmetic means of the summary scores with SDs of the CFQ, consisting of 10 questions, are shown graphically in Figure 34. Mean summary scores dropped down significantly after the treatment, representing fewer difficulties while chewing after the treatment ( $p < 0.01$ ). The standardized effect size for the CFQ was 2.34, representing the large effect size (105).

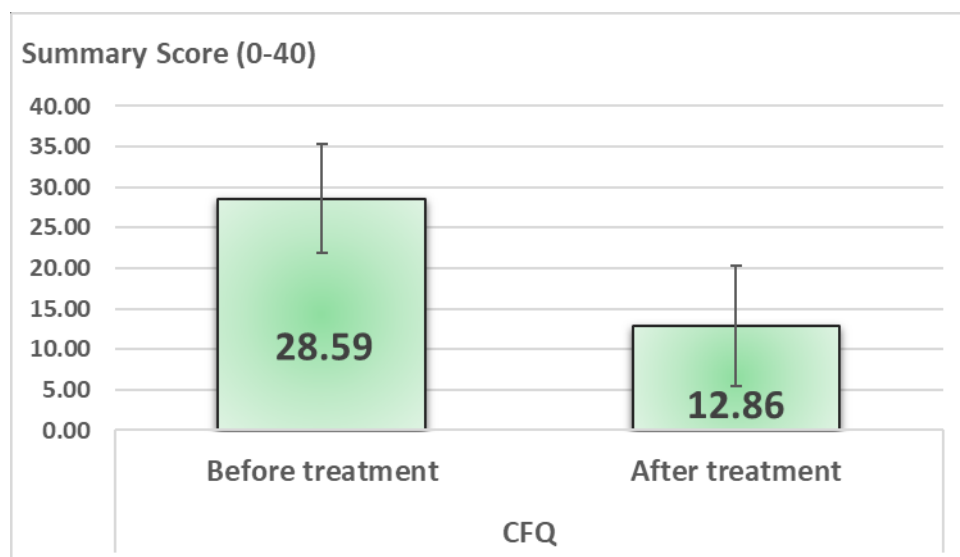


Fig. 34. Arithmetic means of the summary scores of the Chewing Function Questionnaire (CFQ) with standard deviations before and after treatment

#### ***4.3.2 Changes of Patients' reported outcome measures throughout observation: OES, OHRQoL, and CFQ***

The three dPROMs score changes were assessed over the observation period of 2 years in this study, i.e., for the OES, the OHIP-14, and the CFQ. Descriptive statistics of the OES summary scores after the treatment (baseline data) and at the 1-year and the 2-year follow-up examinations are presented in Table 17 together with the significance of the differences (within-subject effect) obtained by the repeated measures test. There were no significant differences in OES summary scores between those obtained immediately after the treatment and those gathered at the 1-year, or the 2-year follow-up examinations. Graphical presentation of the OES summary scores after treatment, at the 1-year, as well as at the 2-year observation stages are shown in Figure 35.

Table 17. Descriptive statistics of the Orofacial esthetic Scale (OES) over the observation period and the significance of the differences between the three periods of observation (x= mean value. SD= standard deviation. n=number. F=F value. df=degree of freedom. p= p-value

#### **Descriptive Statistics**

| OES                                 | X            | SD   | N  | F     | Error<br>df | Hypothesis<br>df | Sig. (p)       |
|-------------------------------------|--------------|------|----|-------|-------------|------------------|----------------|
| After treatment                     | <b>36.50</b> | 4.04 | 61 | 0.354 | 2           | 58               | <b>.703 NS</b> |
| <b>1-year</b> follow-up examination | <b>36.40</b> | 3.51 | 61 |       |             |                  |                |
| <b>2-year</b> follow-up examination | <b>36.38</b> | 3.54 | 61 |       |             |                  |                |

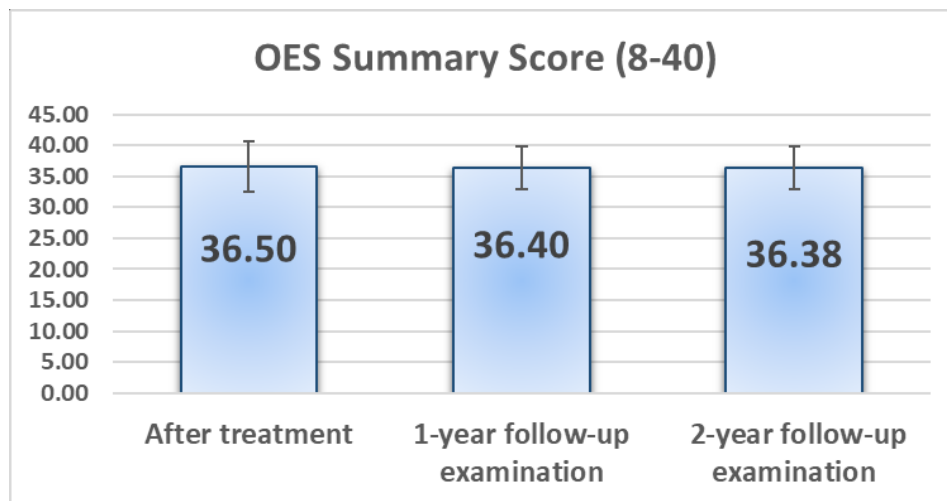


Fig. 35. Descriptive statistics ( $x \pm SD$ ) of the OES over the observation period

Descriptive statistics of the OHIP-14 summary scores after the treatment (baseline data), at the 1-year, and at the 2-year follow-up examinations are presented in Table 18, together with the significance of the differences (within-subject effect; the repeated measures test). There were no statistically significant differences between the three observed periods ( $p > 0.05$ , Table 18).

Table 18. Descriptive statistics of the OHIP-14 over the observation period and the significance of the differences between the three periods of observation ( $x$ = mean value. SD= standard deviation. n=number. F=F value. df=degree of freedom. p=p-value

### Descriptive Statistics

| OHIP-14                             | x     | SD   | N  | F    | Error df | Hypothesis df | Sig. (p) |
|-------------------------------------|-------|------|----|------|----------|---------------|----------|
| After treatment                     | 12.43 | 7.11 | 61 | .285 | 2        | 58            | .753 NS  |
| <b>1-year</b> follow-up examination | 12.64 | 6.67 | 61 |      |          |               |          |
| <b>2-year</b> follow-up examination | 12.60 | 6.39 | 61 |      |          |               |          |

Graphical presentation of the OHIP-14 summary scores after treatment, at the 1-year observation stage, as well as at the 2-year observation is obtained in Figure 36.

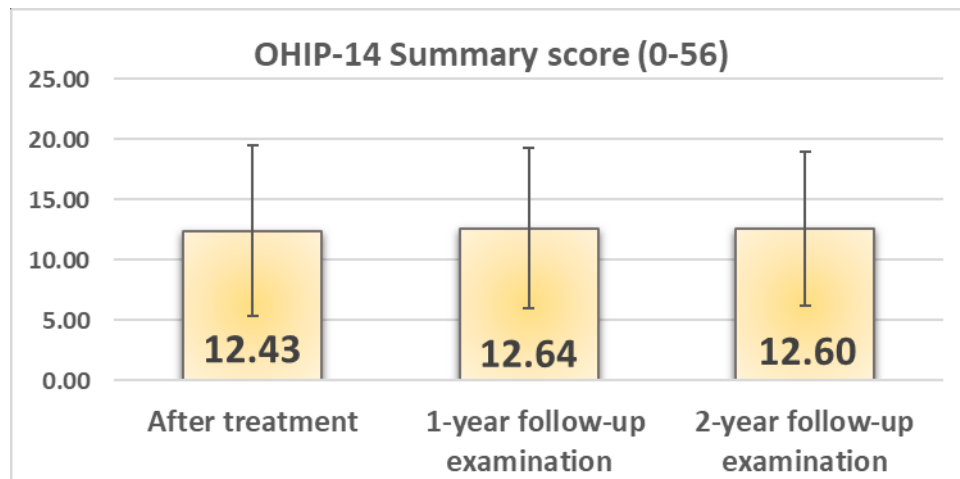


Fig. 36. Descriptive statistics ( $\bar{x} \pm SD$ ) of the OHIP-14 over the observation period

Descriptive statistics of the CFQ summary scores after the treatment (baseline data) and of the summary scores at the 1-year and the 2-year follow-up examinations are presented in Table 19, together with the significance of the differences (within-subject effect; repeated measurement test). There were no statistically significant differences between the three observation periods for the CFQ summary scores ( $p > 0.05$ , Table 19).

Graphical presentation of the OHIP-14 summary scores obtained after treatment, at the 1-year observation stage, as well as at the 2-year observation stage, is shown in Figure 37.



Table 19. Descriptive statistics of the chewing function questionnaire (CFQ) over the observation period and the significance of the differences between the three periods of observation (x= mean value. SD= standard deviation. n=number. F=F value. df=degree of freedom. p= p-value

### Descriptive Statistics

| OHIP-14                             | x     | SD   | N  | F     | Error df | Hypothesis df | Sig. (p)       |
|-------------------------------------|-------|------|----|-------|----------|---------------|----------------|
| After treatment                     | 12.60 | 7.23 | 61 | 1.676 | 2        | 58            | <b>.196 NS</b> |
| <b>1-year</b> follow-up examination | 12.53 | 7.03 | 61 |       |          |               |                |
| <b>2-year</b> follow-up examination | 12.78 | 6.62 | 61 |       |          |               |                |

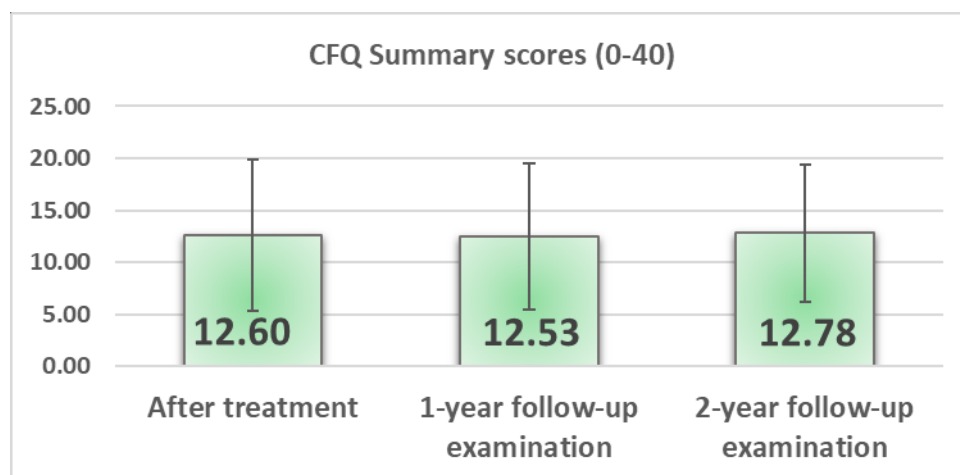


Fig. 37. Descriptive statistics ( $x \pm SD$ ) of the CFQ over the observation period

#### ***4.4. Prosthodontic maintenance***

None of the RPD, supported by MDIs, fractured during the 2-year observation period. Four dentures were repaired due to loss of four MDIs (one per patient) because wire clasps were added for denture retention (instead of O-ring housings) in patients who lost MDIs. Wire clasps were used for retention of respective RPDs and were placed to the adjacent tooth (most distally position anterior tooth near the lost MDI). That happened immediately after MDIs were lost (soon after loading). One denture was relined during the first year (8 months), and four dentures were relined during the second year (18-24 months).

Two metal housings were loosened (one in each patient) and were re-attached by a self-curing resin in the second year (18 months. and 20 months. respectively). Only one O-ring was replaced in the first year because the patient has lost it (at 12-month follow-up), and 28 O-ring replacements were registered in the second year in 12 patients (at the 24 month follow-up). Two artificial tooth de-attached (one tooth per a denture), and were repaired. That event occurred in the second year (20 and 22 months, respectively). One of the remaining natural teeth was lost (due to caries and mobility), and it was replaced in the respective denture by the artificial acrylic tooth in the second year (21 months).

#### **4.5. Kennedy Class II patients – Mini-implant marginal bone loss, Survival, and Success**

Only 14 Kennedy Class II patients were recruited (11 females, three males, 52-80 years, eight MDIs were inserted in the mandible, six in the maxilla, mean age  $65 \pm 7.1$  years). Patients with unilateral posterior tooth loss wanted to receive implant-retained FPDs in most cases. Recruited patients represented those who had narrow ridges and who did not wish to undergo bone augmentation procedure and/or sinus lift.

All patients with Kennedy Class II were available at the one-year and two-year follow-up examinations. Because of a small number of patients in this cohort group, the only descriptive statistic is provided. Graphical presentation of mini-implant marginal bone loss levels together with standard deviation is shown in Figure 38. The paired t-test showed no significant differences between the mesial and the distal MDI sides ( $p < 0.05$ ).

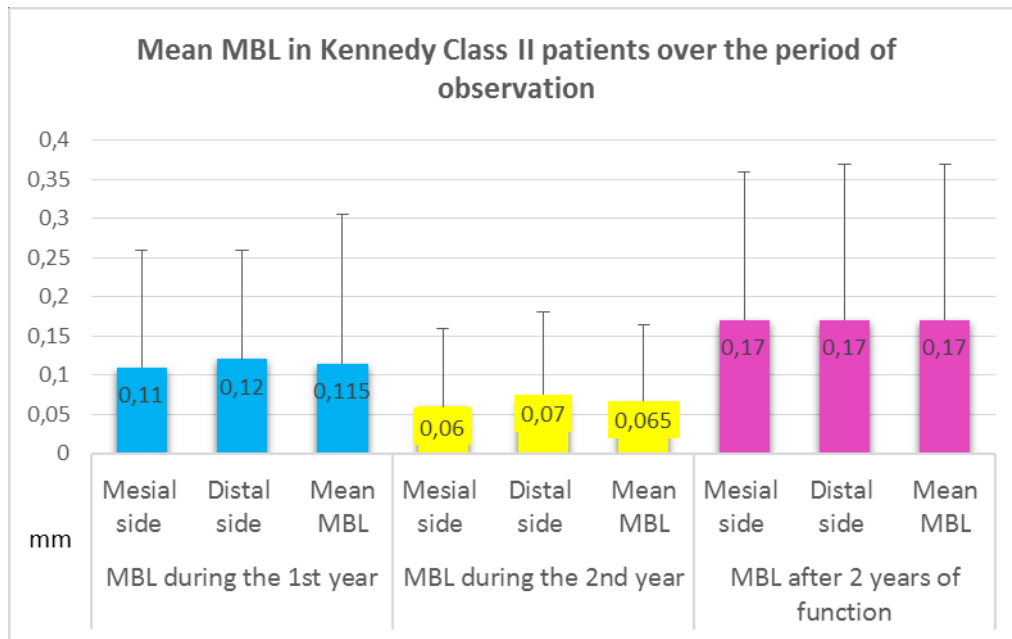


Fig. 38. Descriptive statistics ( $\bar{x} \pm SD$ ): mean mini-implant marginal bone loss values during the 1<sup>st</sup>, the 2<sup>nd</sup> year and the overall 2-year observation period of observation

None of the MDIs was lost, representing 100% survival rates at the 1-year and the 2-year observation period. None of the MDIs showed substantial peri-implant bone loss, no clinical problems were observed, no suppuration or MDI mobility, or pain, representing the 100% success rate, both at the 1-year, as well as at the 2-year observation period.

## 5. DISCUSSION

Within the limitations of this 2-year follow-up study, it can be concluded that MDIs inserted in previous canine or first premolar sites (for retention of a free-end saddle RPD) in Kennedy Class I patients showed excellent clinical and radiological outcomes, comparable to those of MDI supported mandibular overdentures. Only patient age influenced the rate of peri-implant marginal bone changes (more pronounced in younger patients), while gender, the jaw of insertion, and the dental status of the antagonistic jaw did not.

The dPROMs, such as the OES, the OHIP-14, and the CFQ, showed a large effect size for the treatment. Summary scores remained almost unchanged throughout the two years of observation, revealing excellent self-reported oral health with this treatment modality of the bilateral edentulous situation when all posterior teeth are missing.

Partially edentulous patients without posterior abutment teeth can be treated with implant-retained FPDs, RPDs, with implant-retained RPDs, or they can be left without any treatment in some specific cases following the principles of shortened dental arches (SDA). However, for the SDA concept, at least 20 remaining teeth are recommended to be present in both jaws with premolars and canines maintaining a stable vertical dimension of occlusion (102-107).

For a prosthodontic rehabilitation with implant-retained FPD, a patient must have sufficient alveolar bone volume for implant placement, must not have any of the medical conditions that preclude implant insertion, must have a positive attitude towards oral surgical intervention, and must have an economic status that does not prevent unavoidable expenses of oral implants. In patients with lower financial possibilities, or in those who have insufficient bone volume at some sites of their edentulous alveolar ridges, an implant-retained RPD can be made by inserting implants either in molar sites or more anteriorly in premolar sites to offer better retention, support, and stability to RPDs than the clasps. The SDA can be left as a treatment modality (without intervention) only in those cases when remaining patients' posterior teeth offer a stable vertical dimension of occlusion and when there are no posterior teeth without antagonistic support in an antagonistic jaw.

Conventional RPD can be made with clasps or with precision attachments for esthetic retention; however, when planning precision attachments, at least two patient's remaining teeth must be prepared for crowns, which incorporate a female or a male precision attachment part. A lot of knowledge, contemporary and conventional treatment techniques, and planning are required for successful restorations of dentition with RPDs.

In our study, we investigated whether MDI retained RPDs in patients with a bilateral free-ending situation (Kennedy Class I) without any of the remaining posterior teeth can be a successful treatment option. A clinical prospective cohort study was designed in which several clinical and radiographic parameters regarding MDIs were assessed and followed-up over two years. The consecutive patients who fulfilled the general and local inclusion criteria were recruited. All patients were administered a single dose of antibiotics one hour prior to MDI surgery because most of the patients were older. Moreover, one study reported lower early implant failure rate with a single dose of antibiotics compared to when no antibiotics were used (108).

At the 1-year follow-up, only three patients out of 84 dropped-out. One of them died, and two moved to another city. However, at the 2-year follow-up, 25% of the patients examined in the first year did not respond. Another patient died, and 19 patients did not respond although they were contacted by telephone (three times) and a post-card. Twelve of them answered a phone call and explained that they had no problems with dentures, so they would not come to a dental office. They were not included in the 2-year follow-up, as they were not examined, and their radiographic data at the 2-year examination were missing.

In this study, patients with sufficient bone posteriorly for SSI placement were excluded because they could receive standard size oral implants. All patients involved in this study had narrow alveolar ridges probably because all of them were previous conventional clasp-retained free-end saddle RPD wearers for at least four years. Therefore, MDIs were inserted in the previous first premolar or canine sites. All MDIs were placed anteriorly from the opening of the mental nerve in the mandible or bellow and anteriorly of the sinus floor in the maxilla still maintaining Kennedy type I classification. However, previous linear denture support (without MDIs) was converted into a more favorable polygonal denture support by insertion of mini-implants (Fig. 39 a-c).

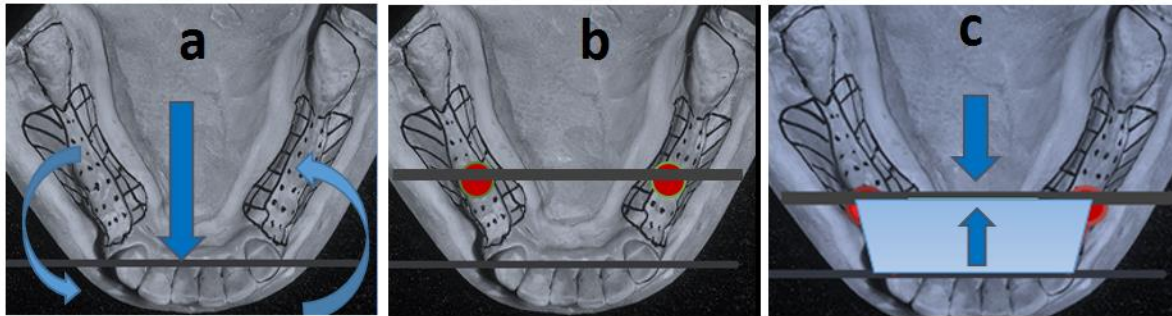


Fig. 39 a-c. Linear removable partial denture support (a) was converted into the polygonal RPD support (c) by inserting mini-implants posteriorly from the last remaining anterior natural tooth (b)

Although it has been mostly recommended to insert SSIs in previous molar sites to reduce displacement of a free-end saddle RPD on mucosal tissues under loads (109,110), SSIs placed in previous first premolar sites presented better relief with regard to the most distal remaining anterior patient's tooth (111). Jensen et al. (112,113) showed excellent clinical results of standard-sized implants placed in previous first premolar sites for an RPD retention. The results of this study with MDIs inserted in the first premolar or canine sites are in agreement with the study findings by Jensen et al. (112,113).

None of the MDIs was lost during surgical insertion. There is little information in the dental literature on how to prepare implant beds for MDIs. The manufacturers recommend the preparation of one- to two-thirds of MDI length with narrower drills (with the addition of the height of mucosal tissue). Kanazawa et al. recommend penetrating one-third to one-half of the implant height into bone and, by using a thumb wrench and a ratchet, the implant is self-driven into bone, i.e., it acts as a self-tapping screw (114).

However, preparation length is dependent on bone density, and longer preparation is needed in a denser mandibular bone than in the maxilla. Following the manufacturer's instructions for insertion, all mini-implants were inserted without problems in this study. None of the MDIs fractured during insertion because all MDIs ended before reaching dense bone of the lower border of the mandible or the nasal cavity (or maxillary sinus) in the maxilla.

### ***5.1 Marginal bone loss, success, and survival of MDIs***

The clinical and radiographic findings of this study during the 2-year follow-up period showed excellent clinical behavior of MDIs, indicating that a method of inserting two mini-implants for retention of an RPD can be a successful treatment method. The success rates obtained for MDIs in this study were not different from patients who received mandibular MDI retained overdentures (39-43). The success and survival rates obtained in this 2-year study are similar or even better than those reported by Threeburuth et al., who placed one-piece implants at molar sites for an RPD retention and support (119). Threeburuth et al. inserted one-piece implants that were 3 mm wide in previous first molar sites for RPD retention utilizing the equator attachment system and reported 93.3% of success over one year. The MDIs in this study had a smaller diameter (2.0 or 2.5 mm), and O-ring matrices represented a more resilient attachment system than the equator attachment system. The new ITI consensus statement about MDIs dating from the last year lists only one-piece implants 1.8 to 2.5 mm wide into the mini-dental implant group. According to that, 3 mm wide one-piece implants used by Threeburuth et al. do not belong to the mini-implant grouping.

Implant inclination is also an essential factor influencing stress and tension around implants. It has been reported that strains were higher in inclined implants (120). We, therefore, tried to insert two MDIs parallel to each other and parallel to the long axes of patients' natural remaining teeth as much as it was possible. Metal housings with an O-ring attachment system accommodate up to  $\pm 15$  degrees of tilting angles to the pathway of the long implant axis in both directions, a total of 30 degrees.

Attachment height can also influence the bending moment of the implant. The height of the stud attachments in implant overdentures had a marked effect on the lateral force on both implants and denture displacement (121). Therefore, the height of the attachment should be carefully considered. A high-profile attachment causes a more significant bending moment than a low-profile attachment (121). A low profile and resilient-type attachment was selected in this study. Only 5.8 mm of polished MDI surface is supposed to be above the bone-to-implant contact (interface). The ratio of the MDI polished part, and its roughened surface in the bone was at least 0.5: 1 (10 mm long MDIs) in favor of the mini-implant part inserted into the bone. In longer MDIs (12 or 14 mm long), the ratio was even smaller.



It was reported in one “in vitro” study that during unilateral loading conditions, the terminal implant on the non-loading side played a crucial role in resisting the bending forces (122). Therefore, we compared mini-implant marginal bone loss on mesial and distal sides, and marginal bone loss of MDIs inserted in the left and the right side of a jaw. No significant differences between the mesial and the distal MDI sides and between the left and right side MDIs, as observed in this study, indicate that the remaining teeth and the RPD design stabilized the removable denture, so there were no movements that could elicit excessive mini-implant marginal bone loss in any of the two MDIs. It is also possible that patients chewed food bilaterally and did not have a preferred chewing side, so there were no differences in marginal bone loss. Moreover, compensatory mechanisms related to the adaptive response of bone to increased dynamic mechanical loadings are not present in “in vitro” studies. Maxillary dentures had full palatal coverage in the patients of this study, so maxillary RPDs were stabilized as much as possible.

Commonly, the highest mini-implant marginal bone loss occurs in the first year after implant placement, and after that, marginal bone mostly remains stable (52,123,124). Moreneburg & Pröchel (125) reported 0.5 mm of bone loss in the 1<sup>st</sup> year (SD 0.4) and another 0.2 millimeters in the 2<sup>nd</sup> year, and no significant bone loss in further years. In line with that, we may anticipate good prognosis for MDIs in the RPD wearers in this study, as the rate of mini-implant marginal bone loss in this study was lower for the 1<sup>st</sup>, as well as for the 2<sup>nd</sup> year, and it was lower in the 2<sup>nd</sup> year than in the 1<sup>st</sup> year. Small amounts of mini-implant marginal bone loss revealed in this study may also be attributed to good stabilization of an RPD by major connector resting on the raised cingulum of anterior teeth.

Only four MDIs were lost soon after loading; they were probably not fully osseointegrated (due to narrow ridges and possible cortex perforation). Therefore, their loss can be considered as a consequence of surgical complications. The errors of preparation are inherent to flapless insertion, as highlighted by Enkling et al. (126). They reported 100% survival and success rates after the open-flap MDI insertion. However, MDI loss in this study may also have been caused by other factors, such as post-surgical infections, insufficient bone quality, overload, and/or micro-movements during healing. Similar to our results, Moraschini et al. reported that most of implants were lost soon after loading (127).

None of the MDIs was lost afterward. Success and survival rates reported in this study were similar to the reports of other authors who used 4 MDIs to support complete mandibular

dentures (39-42,47,49,52,88,120,128-135), although one should have in mind that different studies used slightly different criteria to list an implant into the success category (92,136-140). Therefore, it is difficult to perform a correct comparison.

This study showed no significant difference in the mini-implant marginal bone loss between the maxilla and the mandible. However, Elsayad et al. (44) reported a more significant amount of mini-implant marginal bone loss and lower success rates when MDIs were supporting complete maxillary overdentures, especially with U shaped palatal coverage. The reason for the difference of these study results compared to that of Elsayad et al. (44) could be due to better stabilization of RPDs in our patients than of CD in the study of Elsayad et al. Presence of some of the remaining natural anterior teeth in RPD patients in this study helped to stabilize RPD against lateral and rotational movements. Moreover, MDI insertion in this study transferred linear support into a more favorable polygonal support for an RPD. Only denture subsidence in the posterior region was possible with new support, which was mostly compensated by a resilient attachment system (o-rings).

The amount of mini-implant marginal bone loss in this study was lower than the amount reported by Jofre et al. (53). They used two mini-implants for retention of complete mandibular overdentures. They reported a mean mini-implant marginal bone loss of 1.4 mm in the first year of loading and lower survival rates (90.4%) than it was recorded in this study. They used only two unsplinted MDIs for mandibular overdenture retention. However, two MDI used for retention and support of RPDs in this study probably received less favorable forces and strains from removable denture movements due to remaining patients anterior teeth, raised cingulum, and major connector design, which helped to stabilize a denture, and due to polygonal RPD support. Prevention of rotational and other unfavorable denture movements obviously led only to small amounts of marginal bone loss around the MDIs.

However, small quantities of marginal bone loss in this study may also be attributed to slight differences in mini-implant marginal bone loss measurement compared to some other clinical trials. Some studies measured mini-implant marginal bone loss from the bone to implant interface, i.e., the first contact between an implant and the bone determined after implant placement. In this study, there were some cases when smooth cervical parts of MDIs were completely submerged in the bone (due to thin oral mucosa and only one available dimension of the MDI's transmucosal smooth part). The mini-implant marginal bone loss was considered

as bone remodeling until it reached the first thread of the roughened MDI surface. The mini-implant marginal bone loss was measured from that point towards the tip of an MDI.

The 2-factor ANCOVA and the 3-factor ANCOVA, analyzing effects of different factors (such as gender, jaw of insertion, status of antagonistic jaw and age as a continuous covariate) on mini-implant marginal bone loss showed that only patients' age had a significant effect on the rate of marginal bone loss and this loss was more substantial in younger patients, which is in line with the Jemt's study (141). The occlusal loading, gender, and the status of the antagonistic jaw could potentially also affect the rate of mini-implant marginal bone loss, but this was not the case.

Although the mini-implant marginal bone loss was a bit higher in females, especially during the first year, there was no significant gender difference. It is in line with other studies (142,143).

## ***5.2. Oral hygiene outcomes***

Regarding oral hygiene assessment using MPI and MBI indices, the results of this study were not perfect. Most of the patients had at least degree 1 of plaque index, which means that plaque was present at some sites around their MDIs. The median value and the modal value (the most frequent value) equaled to one for the MPI, revealing that almost all patients had at least some plaque. Significantly more plaque and bleeding on probing were present at the clinical exam after two years than after the first year. However, in the second year, the rate of mini-implant marginal bone loss decreased in comparison to the 1<sup>st</sup> year. More plaque in the 2<sup>nd</sup> year after loading did not elicit pronounced marginal bone loss in MDIs inserted in patients participating in this study.

Patients were more motivated in the 1<sup>st</sup> year after MDI insertion to maintain oral hygiene when provided with a thorough explanation of how to do it and how important it is for the mini-implants' health and survival. Over time, patients' enthusiasm towards maintaining perfect oral hygiene was diminished; therefore, it may be an appropriate practice to motivate patients at least once a year about the importance of keeping their implants as clean as possible and keeping healthy surrounding mucosal tissue.

### ***5.3. Prosthodontic maintenance***

All original dentures were functioning at the 2-year observation stage. No denture fractures were observed during the 2-year period, which can be attributed to metal framework reinforcements. In patients who lost MDIs after loading, four original dentures were repaired, and a clasp was added for retention instead of the lost MDI. Most of the O-ring replacements were due to wear. The manufacturer recommends O-ring change once a year, but we changed only 29 O-rings within two years. Only one of the remaining natural teeth (not adjacent to MDI) was lost and was replaced in the respective denture. Only one patient reported transient pain during the second year, which was probably due to the loss of the O-ring; therefore, the RPD might have overloaded peri-implant mucosal tissue. The pain disappeared after the replacement of the lost O-ring.

### ***5.4. Patient-reported outcome measures***

The impact of oral disorders and interventions on individually perceived oral health outcomes has been increasingly recognized as an essential health component. Patient-based reports have been widely incorporated in the assessment of oral health status.

The OHIP has been a widely used instrument for capturing the dimensions of OHRQoL (144,145). It was considered that the long version of the OHIP questionnaire (OHIP 49) comprised seven dimensions of oral health, i.e., Functional Limitations, Physical Pain, Psychological Discomfort, Physical Disability, Psychological Disability, Social Disability, and Handicap (144), but recently it was found out that the long version OHIP (49 questions) comprises only four dimensions of oral health: Oral Function, Orofacial Appearance, Oral Pain and Psychosocial Impact dimensions (145,146,147). Because the long OHIP questionnaire is time-consuming, shorter versions of this dPROM were also developed. The short versions of the OHIP, such as OHIP-TMD and the OHIP-EDENT, were developed for the cohort of patients suffering from temporomandibular dysfunctions or for the edentulous patient population. However, the most commonly used short form of the OHIP is the OHIP-14, a questionnaire consisting of 14 items.

This shortened version, i.e., the OHIP-14, meets most clinical needs and has excellent psychometric properties. Croatian and Albanian language versions of OHIP-14 exist, and they have been both psychometrically tested (93,94).

A recent publication showed that the data obtained by the OHIP-14 are well approximated by a one-factor model (148). Therefore, it was decided to use the OHIP-14 questionnaire in this study to monitor patients' OHRQoL. It is not time-consuming, and most of the patients quickly complete the questionnaire.

We also used two other unidimensional questionnaires: the OES (for patient assessment of self-perceived orofacial esthetics) (97,98) and the CFQ (for evaluation of self-perceived chewing function) (95,96). The OES and the CFQ represented structured unidimensional questionnaires, each capturing only one dimension of orofacial well-being. The structured questionnaires describe much better certain constructs than only a straightforward question that refers to the same construct.

The standardized effect size was calculated to assess the effect of the provided treatment for the MDI-RPD patients using the pretreatment summary scores and the posttreatment summary scores (obtained 15 days to one month after new RPDs delivery and MDI loading) and the pre-treatment standard deviation. It was calculated by subtracting pre-treatment and post-treatment scores, and the difference was divided with the pre-treatment standard deviation. The effect size, according to Cohen, was large for all three questionnaires. The effect size was larger than reported in some other studies for the new conventional RPD treatment, especially for the OES and the CFQ (149).

Improved orofacial esthetics, OHRQoL, and chewing function did not diminish after the 2-year observation period, indicating long-lasting treatment effects. It was reported that for clasp retained RPD wearers, the initial treatment effects soon decreased (97), especially for the domain of orofacial esthetics. Excellent patient-centered outcomes reported already in the previous study (150) for the first 6-month of MDI-RPD wearing remained unchanged over the two years.

Although clinical findings are essential for assessment of treatment outcomes, the most critical measures for patients are patient-reported outcomes because they measure how the self-perceived oral health was impacted by an oral condition, which was, in our case, partial edentulism. Clinical findings and PROMs were in line in this 2-year follow-up clinical cohort study.

### **5.5. Marginal bone loss in mini-implants in Kennedy Class II patients**

Only 14 Kennedy Class II patients were recruited, probably because Kennedy Class II is not a frequent situation, and patients with unilateral posterior tooth loss usually decide to receive implant-retained FPDs. Recruited patients represented those individuals who had narrow ridges and who did not want bone augmentation procedures and/or sinus lift, which was necessary for standard size implant placement for an FPD. No comparison was made for marginal bone loss between male and female patients, or between the mandible and the maxilla, due to the insufficient number of patients in the study, which prevented such statistical analysis.

All patients with Kennedy Class II were available at the one-year and the two-year follow-up examinations. Because of a small number of patients in this cohort group, only descriptive statistics were made. Graphical presentation of mini-implant marginal bone loss together with standard deviation is shown in Figure 43. Paired t-test showed no significant differences between the mesial and the distal MDI sides, nor for the first, neither for the second year ( $p < 0.05$ ).

The obtained mini-implant marginal bone loss was similar, even smaller than in Kennedy Class I patients, which can be attributed to good stabilization of RPDs in these patients. None of the MDIs was lost. Success and survival rates were 100% for both periods of observation. However, as a conclusion, in the Kennedy Class II cohort of patients about mini-implant utilization for an RPD retention and support, more patients should be recruited and observed.

### **5.6. Study limitation**

The limitation of this study is a relatively short observation period (2 years) for a long-term prognosis (10 years). Although the sample size for Kennedy Class I situation was sufficient for the 2-year observation period of this study (we recruited more patients than it was necessary), many patients, unfortunately, did not respond when they were asked to revisit us for a 2-year follow-up examination. One of the critical reason for this is that we have mostly geriatric dental patient population. If the trend continues, the sample size must be increased for a long-term follow-up. However, the effort will be made to motivate patients who did not come for a recall. Although some patients answered a phone and stating they would not do the follow-up visit, as they don't have any problem, the follow-up radiographs are necessary for

the measurement of mini-implant marginal bone loss. The sample size for the Kennedy Class II dental status was too small for comparison between genders and jaw of insertion.

### ***5.7. Final observations***

To overcome problems with a conventional RPD's retention and stability and to prevent adverse effects of an RPD to abutment teeth and tissues of a denture bearing area, MDI insertion in patients with narrow ridges can offer better clinical solution than a conventional RPD. The 2-year clinical outcomes of MDI retained RPDs placed in the first premolar and/or canine sites revealed good clinical results. Moreover, orofacial esthetics, which is one of the dimensions of the patient's OHRQoL (149,151), was not compromised by RPD-clasp visibility in the MDI retained RPDs.

From the cost-effective analysis, it is even less expensive to insert two MDIs than to prepare all remaining teeth for a fixed partial denture with incorporated precision attachments for an RPD retention. The MDI placement also allows keeping slightly mobile teeth, which would not be included in an FPD with incorporated precision attachments. The fact that MDI insertion elicits less pain than the SSI insertion, especially when placed without reflecting a flap (35), favors them even for the oldest patients. This 2-year follow-up study approved MDIs for RPD retention, at least in the short-term outcomes.

Approval of MDI supported RPD is a very important new treatment for the partial edentulous population. Partial edentulism will remain relevant in the following decades on a global level as its prevalence exceeds 10% in adults being 50 years and older (152). Although there is a decline in both complete or partial edentulism in highly industrialized and developed countries, there is also an increase in older population (152).

## 6. CONCLUSIONS



Within the limitations of this 2-year follow-up study, it can be concluded that MDIs inserted in previous canine or first premolar sites (for retention of a free-end saddle RPD) in Kennedy Class I patients showed excellent clinical and radiological outcomes, comparable to those of MDI supported mandibular overdentures. Only patient age influenced the rate of peri-implant marginal bone changes (more pronounced in younger patients), while gender, the jaw of insertion, and the dental status of the antagonistic jaw did not.

The dPROMs, such as the OES, the OHIP-14, and the CFQ, showed a significantly better self-reported chewing function, orofacial appearance, and the overall OHRQoL during two years of observations. Summary scores remained almost unchanged throughout the two years of observation, revealing excellent patient-reported outcomes with this treatment modality of bilateral edentulous cases when all posterior teeth are missing. Prosthodontic maintenance was not demanding, including only minor denture repairs or O-ring changes. Therefore, based on the results of this study, treatment with MDI retained RPDs can be recommended as a good clinical option for Kennedy Class I patients with narrow ridges, at least for a short period. Therefore, more long-lasting prospective studies are needed to assess if the clinical and patient-reported variables change for the Kennedy Class I and Class II patients having the MDIs and the RPDs in use for three years and more.

## 7. REFERENCES

1. Muller F, Heath MR, Ott R. Maximum bite force after the replacement of complete dentures. *Gerontology* 2001;18(1):58-62.
2. Polzer I, Schimmel M, Muller F, Biffar R. Edentulism as part of the general health problems of elderly adults. *Int Dent J.* 2010;60(3):143-55.
3. Cibirka RM, Razzoog M, Lang BR. Critical evaluation of patient responses to dental implant therapy. *J Prosthet Dent.* 1997;78(6):574-81.
4. Thomason JM, Heydecke G, Feine JS, Ellis JS. How do patients perceive the benefit of reconstructive dentistry with regard to oral health–related quality of life and patient satisfaction? A systematic review. *Clin Oral Implants Res.* 2007;18 Suppl 3:168-88.
5. Muller F, Naharro M, Carlsson GE. What are the prevalence and incidence of tooth loss in the adult and elderly population in Europe? *Clin Oral Implants Res.* 2007;18 Suppl 3:2-14.
6. Zitzmann NU, Hagmann E, Weiger R. What is the prevalence of various types of prosthetic dental restorations in Europe? *Clin Oral Implants Res.* 2007;18 Suppl 3:20-33.
7. Mundt T, Polzer I, Samietz S, Grabe HJ, Messerschmidt H, Doren M. Socioeconomic indicators and prosthetic replacement of missing teeth in a working–age population—results of the Study of Health in Pomerania (SHIP) Community Dent Oral Epidemiol. 2009;37(2):104-15.
8. Szentpetery V, Lautenschlager C, Setz JM. Frictional telescopic crowns in severely reduced dentitions: a 5–year clinical outcome study. *Int J Prosthodont.* 2012;25(3):217-20.
9. Mundt T, Polzer I, Samietz S, Grabe HJ, Doren M, Schwarz S. Gender–dependent associations between socioeconomic status and tooth loss in working age people in the Study of Health in Pomerania (SHIP) Germany. *Community Dent Oral Epidemiol.* 2011;39(5):398-408.
10. Kaufmann R, Friedli M, Hug S, Mericske–Stern R. Removable dentures with implant support in strategic positions followed for up to 8 years. *Int J Prosthodont.* 2009;22(3):233-41.

11. Goncalves TM, Campos CH, Garcia RC. Implant retention and support for distal extension partial removable dental prostheses: satisfaction outcomes. *J Prosthet Dent.* 2014;112(2):334-9.
12. Rinke S, Ziebolz D, Ratka-Kruger P, Frisch E. Clinical Outcome of Double Crown–Retained Mandibular Removable Dentures Supported by a Combination of Residual Teeth. *J Prosthodont.* 2015;24(5):358-65.
13. Tallgren A. The continuing reduction of the residual alveolar ridges in complete denture wearers: a mixed–longitudinal study covering 25 years. *J Prosthet Dent.* 1972;27(2):120-32.
14. Petersen PE, Yamamoto T. Improving the oral health of older people: the approach of the WHO Global Oral Health Programme. *Community Dent Oral Epidemiol* 2005;33(2):81-92.
15. Ueno M, Ohara S, Inoue M. Association between education level and dentition status in Japanese adults: Japan public health center-based oral health study. *Community Dent Oral Epidemiol.* 2012;40(6):481-7.
16. Douglass CW, Watson AJ. Future needs for fixed and removable partial dentures in the United States. *J Prosthet Dent.* 2002;87(1):9-14.
17. Anderson D. Mosby's Medical: Nursing & Allied Health Dictionary. St. Louis: Mosby; 2002. 1240 p.
18. Brånemark P–I, Zarb GA, Albrektsson T. Tissue-Integrated Prostheses, Osseointegration in Clinical Dentistry. Chicago: Quintessence Publ. Co. Inc.; 1985.
19. Brånemark PI, Hansson BO, Adell R. Osseointegrated implants in the treatment of the edentulous jaws. Experience from a 10–year period. *Scand J Plast Reconstr Surg.* 1977;16(Suppl 1):11-32.
20. Ghoul WE, Chidiac JJ. Prosthetic requirements for immediate implant loading: a review. *J Prosthodont.* 2012;21(2):141-54.
21. Strub JR, Jurdzik BA, Tuna T. Prognosis of immediately loaded implants and their restorations: a systematic literature review. *J Oral Rehabil.* 2012;39(9):704-17.

22. Brånemark P-I. Osseointegration and its experimental background. *J Prosthet Dent.* 1983;50(3):399.
23. Balkin BE, Steflik DE, Navel F. Mini–dental implant insertion with the auto-advance technique for ongoing applications. *Oral Implantol.* 2001;27(1):32-7.
24. Palmer R, Howe LC, Palmer PJ, Bavisha K, Suleiman M. *Implants in Clinical Dentistry.* London: Informa Healthcare; 2012.
25. Kovacic I, Celebić A, Zlatarić DK, Petricević N, Buković D, Bitanga P, Mikelić B, Tadin A, Mehulić K, Ognjenović M. Decreasing of residual alveolar ridge height in complete denture wearers. A five year follow up study. *Coll Antropol.* 2010;34(3):1051-6.
26. Palac A, Bitanga P, Capkun V, Kovacic I. Association of cephalometric changes after 5 years of complete dentures wearing and oral health-related quality-of-life. *Acta Odontol Scand.* 2013;71(3-4):449-56.
27. Fine JS, Carlsson GE, Awad MA, Chehade A, Duncan WJ, Gizani S. The McGill consensus statement on overdentures. Mandibular two-implant overdentures as first choice standard of care for edentulous patients. *Int J Oral Maxillofac Implants.* 2002;17(4):601-2.
28. Jackson BJ. Fixed partial denture treatment with mini dental implants. *J Oral Implantol.* 2014;40(6):744-50.
29. Flanagan D, Mascolo A. The mini dental implant in fixed and removable prosthetics: a review. *J Oral Implantol.* 2011;37:123-32.
30. Balaji A, Mohamed JB, Kathiresan R. A pilot study of mini implants as a treatment option for prosthetic rehabilitation of ridges with sub-optimal bone volume. *J Maxillofac Oral Surg.* 2010;9(4):334-8.
31. Shatkin TE, Shatkin S, Oppenheimer A. Mini dental implants for the general dentist. *Compend Contin Educ Dent.* 2003;24(11):26-34.
32. Adell R, Lekholm U, Rockler B, Brånemark PI. A 15– year study of osseointegrated implants in the treatment of the edentulous jaw. *Int J Oral Surg.* 1981;10(6):387-416.

33. Hwang D, Wan HL. Medical Contraindication to implant therapy: Part 1: Absolute Contraindications. *Implant Dent.* 2006;15(4):353-8.
34. Marx RE, Johnson RP. Studies in the radiobiology of osteoradionecrosis and their clinical significance. *Oral Surg Oral Med Oral Pathol.* 1987;64(4):379-90.
35. Kovačić I, Peršić S, Kranjčić J, Disha V, Rener–Sitar K, Čelebić A. Short–term Postoperative Pain and Swelling Associated with Mini and Standard–Size Implants in the Same Patients. *Int J Prosthodont.* 2018;31(2):117-9.
36. Achilli A, Tura F, Euwe E. Immediate/early function with tapered implants supporting maxillary and mandibular posterior fixed partial dentures: Preliminary results of a prospective multicenter study. *J Prosthet Dent.* 2007;97(Suppl 6):52-8.
37. Lerner H. Minimal invasive implantology with small diameter implants. *Implant Practice.* 2009;2(1):30-5.
38. Bornstein M, Nawas B, Kuchler U, Tahmaseb A. Consensus statements and recommended clinical procedures regarding contemporary surgical and radiographic techniques in implant dentistry. *Int J Oral Maxillofac Implants.* 2014;29 Suppl 1:78-82.
39. Goiato MC, Sônego MV, Pellizzer EP, Gomes JML, da Silva EVF, Dos Santos DM. Clinical outcome of removable prostheses supported by mini dental implants. A systematic review. *Acta Odontol Scand.* 2018;76(8):628-37.
40. Marcello–Machado RM, Faot F, Schuster AJ, Nascimento GG, Del Bel Cury AA. Mini–implants and narrow diameter implants as mandibular overdenture retainers: A systematic review and meta-analysis of clinical and radiographic outcomes. *J Oral Rehabil.* 2018;45(2):161-83.
41. Park JH, Lee JY, Shin SW. Treatment Outcomes for Mandibular Mini–Implant–Retained Overdentures: A Systematic Review. *Int J Prosthodont.* 2017;30(3):269-76.
42. Lemos CA, Verri FR, Batista VE, Júnior JF, Mello CC, Pellizzer EP. Complete overdentures retained by mini implants: A systematic review. *J Dent.* 2017;57:4-13.
43. Temizel S, Heinemann F, Dirk C. Clinical and radiological investigations of mandibular overdentures supported by conventional or mini–dental implants: a 2–year prospective follow–up study. *J Prosthet Dent.* 2017;117(2):239-46.

44. Elsyad MA, Ghoneem NE, El-Sharkawy H. Marginal bone loss around unsplinted mini-implants supporting maxillary overdentures: a preliminary comparative study between partial and full palatal coverage. *Quintessence Int.* 2013;44(1):45-52.
45. Mangano FG, Caprioglio A, Levrini L. Immediate loading of mandibular overdentures supported by one-piece, direct metal laser sintering mini-implants: a short-term prospective clinical study. *J Periodontol.* 2015;86(2):192-200.
46. Catalán A, Martínez A, Marchesani F, González U. Mandibular Overdentures Retained by Two Mini-Implants: A Seven-Year Retention and Satisfaction Study. *J Prosthodont.* 2016;25(5):364-70.
47. Persic S, Palac A, Vojvodic D. Initial effects of a treatment by fixed partial dentures supported by mini dental implants from a patient's point of view. *Coll Antropol.* 2014;38(1):275-78.
48. Flanagan D. Mini Implants Supporting Fixed Partial Dentures in the Posterior Mandible: A Retrospective. *J Oral Implantol.* 2015;41(4):138-43.
49. Scepanovic M, Todorovic A, Markovic A, Patrnogic V, Milicic B, Moufti AM, et al. Immediately loaded mini dental implants as overdenture retainers: 1-year cohort study of implant stability and peri-implant marginal bone level. *Ann Anat.* 2015;199:85-91.
50. Maryod WH, Ali SM, Shawky AF. Immediate versus early loading of mini implants supporting mandibular overdentures: a preliminary 3-year clinical outcome report. *Int J Prosthodont.* 2014;27(6):553-60.
51. Zygogiannis K, Wismeijer D, Parsa A. A pilot study on mandibular overdentures retained by mini dental implants: marginal bone level changes and patient-based ratings of clinical outcome. *Int J Oral Maxillofac Implants.* 2016;31(5):1171-8.
52. Elsyad MA, Gebreel AA, Fouad MM, Elshoukouki AH. The clinical and radiographic outcome of immediately loaded mini implants supporting a mandibular overdenture. A 3-year prospective study. *J Oral Rehabil.* 2011;38(11):827-34.
53. Jofre J, Cendoya P, Munoz P. Effect of splinting mini-implants on marginal bone loss: a biomechanical model and clinical randomized study with mandibular overdentures. *Int J Oral Maxillofac Implants.* 2010;25(6):1137-44.

54. Mundt T, Al Jaghsi A, Schwahn B, Hilgert J, Lucas C, Biffar R, et al. Immediate versus delayed loading of strategic mini dental implants for the stabilization of partial removable dental prostheses: a patient cluster randomized, parallel-group 3-year trial. *BMC Oral Health*. 2017;17(1):30.
55. Bortolini S, Natali A, Franchi M, Coggiola A, Consolo U. Implant retained removable partial dentures: an 8-year retrospective study. *J Prosthodont*. 2011;20(3):168-72.
56. El Mekawy NH, El-Negoly SA, Grawish Mel-A, El-Hawary YM. Intracoronaral mandibular Kennedy Class I implant-tooth supported removable partial overdenture: a 2-year multicenter prospective study. *Int J Oral Maxillofac Implants*. 2012;27(3):677-83.
57. Eom JW, Lim YJ, Kim MJ, Kwon HB. Three-dimensional finite element analysis of implant-assisted removable partial dentures. *J Prosthet Dent*. 2017;117(6):735-42.
58. Omura AJ, Latthe V, Marin MM, Cagna DR. Implant-assisted removable partial dentures: practical considerations. *Gen Dent*. 2016;64(6):38-45.
59. ELSyad MA, Omran AO, Fouad MM. Strains Around Abutment Teeth with Different Attachments Used for Implant-Assisted Distal Extension Partial Overdentures: An In Vitro Study. *J Prosthodont*. 2017;26(1):42-7.
60. Wismeijer D, Tawse-Smith A, Payne AG. Multicentre prospective evaluation of implant-assisted mandibular bilateral distal extension removable partial dentures: patient satisfaction. *Clin Oral Implants Res*. 2013;24(1):20-7.
61. Payne AG, Tawse-Smith A, Wismeijer D, De Silva RK, Ma S. Multicentre prospective evaluation of implant-assisted mandibular removable partial dentures: surgical and prosthodontic outcomes. *Clin Oral Implants Res*. 2017;28(1):116-25.
62. Jivral SA, Chee WL. Use of a removable partial denture in the management of chronic screw loosening. *J Prosthet Dent*. 2005;93(1):13-16.
63. Halterman SM, Rivers JA, Keith JD, Nelson DR. Implant support for removable partial overdentures: a case report. *Implant Dent*. 1999;8(1):74-8.
64. Senna PM, da Silva-Neto JP, Sanchez-Ayala A, SottoMaior BS. Implants to improve removable partial denture retention. *Dent Today*. 2011;30(2):120-1.



65. Giffin KM. Solving the distal extension removable partial denture dilemma: a clinical report. *J Prosthet Dent.* 1996;76(4):347-49.
66. Asvanund CA, Morgano SM. Restoration of unfavorably positioned implants for a partially edentulous patient by using an overdenture retained with a milled bar and attachments: a clinical report. *J Prosthet Dent.* 2004;91(1):6-10.
67. Kuzmanovic DV, Payne AG, Purton DG. Distal implants to modify the Kennedy classifications of a removable partial denture: a clinical report. *J Prosthet Dent.* 2004;92(1):8-11.
68. Carvalho WR, Barboza EP, Caula AL. Implant–retained removable prosthesis with ball attachments in partially edentulous maxilla. *Implant Dent.* 2001;10(4):280-84.
69. Turkyilmaz I. Use of distal implants to support and increase retention of a removable partial denture: a case report. *J Can Dent Assoc.* 2009;75(9):655-58.
70. Uludag B, Celik G. Fabrication of a maxillary implant-supported removable partial denture: a clinical report. *J Prosthet Dent.* 2006;95(1):19-21.
71. Starr NL. The distal extension case: an alternative restorative design for implant prosthetics. *Int J Periodont Restorative Dent.* 2001;21(1):61-7.
72. Pellecchia M, Pellecchia R, Emtiaz S. Distal extension mandibular removable partial denture connected to an anterior fixed implant-supported prosthesis: a clinical report. *J Prosthet Dent.* 2000;83(6):607-12.
73. Jang Y, Emtiaz S, Tarnow DR. Single implant-supported crown used as an abutment for removable cast partial denture: a case report. *Implant Dent.* 1998;7(3):199-204.
74. Chronopoulos V, Sarafianou A, Kourtis S. The use of dental implants in combination with removable partial dentures: a case report. *J Esthet Restor Dent.* 2008; 20(6):355-64.
75. Krennmair G, Krainhofner M, Waldenberger O, Piehslinger E. Dental implants as strategic supplementary abutments for implant-tooth-supported telescopic crown–retained maxillary dentures: a retrospective follow–up study for up to 9 years. *Int J Prosthodont.* 2007;20(6):617-22.

76. Phoenix RD, Cagna DR, DeFreest CF, Stewart KL. Stewart's Clinical Removable Partial Prosthodontics. Chicago: Quintessence Pub; 2008.
77. Chikunov I, Doan P, Vahidi F. Implant–retained partial overdenture with resilient attachments. *J Prosthet Dent*. 2008;17(2):141-8.
78. Ohkubo C, Kobayashi M, Suzuki Y. Effect of implant support on distal–extension removable partial dentures: in vivo assessment. *Int J Oral Maxillofac Implants*. 2008;23(6):1095-101.
79. Carpenter JF. Implant–assisted unilateral removable partial dentures. *Dent Today*. 2014;33(1):106,108-11.
80. Krol AJ, Jacobson TE, Finzen FC. Removable Partial Denture Design: Outline Syllabus. San Rafael, CA: Indent; 1999.
81. Strassburger C, Kerschbaum T, Heydecke G. Influence of implant and conventional prostheses on satisfaction and quality of life: a literature review. Part 2: Qualitative analysis and evaluation of the studies. *Int J Prosthodont*. 2006;19(4):339-48.
82. Mijiritsky E. Implants in conjunction with removable partial dentures: a literature review. *Implant Dent*. 2007;16(2):146-54.
83. Kaufmann R, Friedli M, Hug S. Removable dentures with implant support in strategic positions followed for up to 8 years. *Int J Prosthodont*. 2009;22(3):233-41.
84. Ohkubo C, Kobayashi M, Suzuki Y. Effect of implant support on distal–extension removable partial dentures: in vivo assessment. *Int J Oral Maxillofac Implants*. 2008;23(6):1095-101.
85. Ohkubo C, Kurihara D, Shimpo H. Effect of implant support on distal extension removable partial dentures: in vitro assessment. *J Oral Rehabil*. 2007;34(1):52-6.
86. Grossmann Y, Levin L, Sadan A. A retrospective case series of implants used to restore partially edentulous patients with implant-supported removable partial dentures: 31–month mean follow–up results. *Quintessence Int*. 2008;39(8):665-71.
87. Aunmeungtong W, Kumchai T, Strietzel FP, Reichart PA, Khongkhunthian P. Comparative Clinical Study of Conventional Dental Implants and Mini Dental

- Implants for Mandibular Overdentures: A Randomized Clinical Trial. *Clin Implant Dent Relat Res*. 2017;19(2):328-40.
88. Zygogiannis K, Aartman IH, Parsa A, Tahmaseb A, Wismeijer D. Implant Mandibular Overdentures Retained by Immediately Loaded Implants: A 1-Year Randomized Trial Comparing the Clinical and Radiographic Outcomes Between Mini Dental Implants and Standard-Sized Implants. *Int J Oral Maxillofac Implants*. 2017;32(6):1377-88.
89. Mombelli A, van Oosten MA, Schurch E, Land NP. The microbiota associated with successful or failing osseointegrated titanium implants. *Oral Microbiol Immunol*. 1987;2(4):145-51.
90. Heckmann SM, Heckmann JG, Linke JJ, Hohenberger W, Mombelli A. Implant therapy following liver transplantation: clinical and microbiological results after 10 years. *J Periodontol*. 2004;75(9):909-13.
91. Yoo RH, Chuang S, Erakat MS, Weed M, Dodson TB. Changes in crestal bone levels for immediately loaded implants. *Int J Oral Maxillofac Implants*. 2006;21(2):253-61.
92. Buser D, Weber HP, Lang NP. Tissue integration of non-submerged implants. 1-year results of a prospective study with 100 ITI hollow-cylinder and hollow-screw implants. *Clin Oral Implants Res*. 1990;1(1):33-40.
93. Renner-Sitar K, Petricevic N, Celebic A, Marion L. Psychometric properties of Croatian and Slovenian short form of oral health impact profile questionnaires. *Croat Med J*. 2008;49(4):536-44.
94. Bimbashi V, Celebić A, Islami A, Asllani-Hoxha F, Petricević N. Psychometric properties of the Albanian language version of the OHIP-ALB 49 Questionnaire in the Republic of Kosovo. *Coll Antropol*. 2012;36(4):1189-95.
95. Persic S, Palac A, Bunjevac T, Celebic A. Development of a new chewing function questionnaire (CFQ) for assessment of a self-perceived chewing function. *Community Dent Oral Epidemiol*. 2013;41(6):565-73.
96. Bimbashi V, Staka G, Čelebić A, Hoxha F, Shala K, Petričević N. Psychometric properties of the Albanian version of chewing-function questionnaire CFQ-ALB. *Health Qual Life Outcomes*. 2016;14:38.

97. Persic S, Milardovic S, Mehulic K, Celebic A. Psychometric properties of the Croatian version of the Orofacial Esthetic Scale and suggestions for modification. *Int J Prosthodont*. 2011;24(6):523-33.
98. Bimbashi V, Čelebić A, Staka G, Hoxha F, Peršić S, Petričević N. Psychometric properties of the Albanian version of the Orofacial Esthetic Scale: OES–ALB. *BMC Oral Health*. 2015;15:97.
99. Waller N, John MT, Feuerstahler L, Baba K, Larsson P, Peršić S, et al. A 7–day recall period for a clinical application of the oral health impact profile questionnaire. *Clin Oral Investig*. 2016;20(1):91-9.
100. Allen PF, McMillan AS, Locker D. An assessment of sensitivity to change of the Oral Health Impact Profile in a clinical trial. *Community Dent Oral Epidemiol*. 2001;29(3):175-82.
101. Cohen J. *Statistical Power Analysis for the Behavioral Sciences*. Hillsdale, NY: Lawrence Erlbaum; 1988.
102. Dhingra K. Oral rehabilitation considerations for partially edentulous periodontal patients. *J Prosthodont*. 2012;21(6):494-513.
103. Budtz–Jorgensen E. Restoration of the partially edentulous mouth--a comparison of overdentures, removable partial dentures, fixed partial dentures and implant treatment. *J Dent*. 1996;24(4):237-44.
104. Wolfart S, Muller F, Gerß J. The randomized shortened dental arch study: oral health–related quality of life. *Clin Oral Investig*. 2014;18(2):525-33.
105. Zitzmann NU, Hagmann E, Weiger R. What is prevalence of various types of prosthetic dental restorations in Europe ? *Clin Oral Implant Res* 2007;18 Suppl 3:20-33.
106. McKenna G, Allen PF, O’Mahony D. The impact of rehabilitation using removable partial dentures and functionally orientated treatment on oral health–related quality of life: a randomised controlled clinical trial. *J Dent* 2015;43(1):66-71.
107. Khan SB, Chikte UM, Omar R. From classroom teaching to clinical practice: experiences of senior dental students regarding the shortened dental arch concept. *J Dent Educ*. 2014;78(6):906-13.

- 108.Kashani H, Hilon J, Rasoul MH, Friberg B. Influence of a single preoperative dose of antibiotics on the early implant failure rate. A randomized clinical trial. *Clin Implant Dent Relat Res.* 2019;21(2):278-83.
- 109.Sato M, Suzuki Y, Kurihara D, Shimpo H, Ohkubo C. Effect of implant support on mandibular distal extension removable partial dentures: relationship between denture supporting area and stress distribution. *J Prosthodont Res.* 2013;57(2):109-12.
- 110.Oh WS, Oh TJ, Park JM. Impact of implant support on mandibular free–end base removable partial denture: theoretical study. *Clin Oral Implants Res.* 2016;27:87-90.
- 111.Cunha LD, Pellizzer EP, Verri FR, Pereira JA. Evaluation of the influence of location of osseointegrated implants associated with mandibular removable partial dentures. *Implant Dent.* 2008;17(3):278-87.
- 112.Jensen C, Speksnijder CM, Raghoobar GM, Kerdijk W, Meijer HJA, Cune MS. Implant-supported mandibular removable partial dentures: Functional clinical and radiographical parameters in relation to implant position. *Clin Implant Dent Relat Res.* 2017;19:432-9.
- 113.Jensen C, Ross J, Feenstra TL, Raghoobar GM, Speksnijder C, Meijer HJA. Cost–effectiveness of implant–supported mandibular removable partial dentures. *Clin Oral Implants Res.* 2017;28(5):594-601.
- 114.Oda K, Kanazawa M, Takeshita S, Minakuchi S. Influence of implant number on the movement of mandibular implant overdentures. *J Prosthet Dent.* 2017;117(3):380-85.
- 115.Peršić S, Čelić R, Vojvodić D, Petričević N, Kranjčić J, Zlatarić DK, et al. Oral Health-Related Quality of Life in Different Types of Mandibular Implant Overdentures in Function Longer than 3 Years. *Int J Prosthodont.* 2016;29(1):28-30.
- 116.Kovacic I, Persic S, Kranjcic J, Lesic N, Celebic A. Rehabilitation of an Extremely Resorbed Edentulous Mandible by Short and Narrow Dental Implants. *Case Rep Dent.* 2018;20:759-851.
- 117.Aunmeungtong W, Kumchai T, Strietzel FP, Reichart PA, Khongkhunthian P. Comparative Clinical Study of Conventional Dental Implants and Mini Dental Implants for Mandibular Overdentures: A Randomized Clinical Trial. *Clin Implant Dent Relat Res.* 2017;19(2):328-40.

118. Marcello–Machado RM, Faot F, Schuster AJ, Bielemann AM, Nascimento GG, Del Bel Cury AA. How fast can treatment with overdentures improve the masticatory function and OHRQoL of atrophic edentulous patients? A 1-year longitudinal clinical study. *Clin Oral Implants Res.* 2018;29(2):215-26.
119. Threeburuth W, Aunmeungtong W, Khongkhunthian P. Comparison of immediate–load mini dental implants and conventional-size dental implants to retain mandibular Kennedy class I removable partial dentures: A randomized clinical trial. *Clin Implant Dent Relat Res.* 2018;20(5):785-92.
120. Elsyad MA, Setta FA, Khirallah AS. Strains around distally inclined implants retaining mandibular overdentures with locator attachments: an in vitro study. *J Adv Prosthodont* 2016;8(2):116-24.
121. Ying Z, Gonda T, Maeda Y. Influence of Attachment Height and Shape on Lateral Force Transmission in Implant Overdenture Treatment. *Int J Prosthodont.* 2017;30(6):586-91.
122. Warin P, Rungsiyakull P, Rungsiyakull C, Khongkhunthian P. Effects of different numbers of mini–dental implants on alveolar ridge strain distribution under mandibular implant-retained overdentures. *J Prosthodont Res.* 2018;62(1):35-43.
123. Liao KY, Kan JY, Rungcharassaeng K, Lozada JL, Herford AS, Goodacre CJ. Immediate loading of two freestanding implants retaining a mandibular overdenture: 1–year pilot prospective study. *Int J Oral Maxillofac Implants.* 2010;25(4):784-90.
124. Roe P, Kan JY, Rungcharassaeng K, Lozada JL, Kleinman A, Goodacre CJ, et al. Immediate loading of unsplinted implants in the anterior mandible for overdentures: a case series. *Int J Oral Maxillofac Implants.* 2010;25(5):1028-35.
125. Morneburg TR, Pröschel PA. Success rates of microimplants in edentulous patients with residual ridge resorption. *Int J Oral Maxillofac Implants.* 2008;23(2):270-6.
126. Enkling N, Haueter M, Worni A, Müller F, Leles CR, Schimmel M. A prospective cohort study on survival and success of one–piece mini-implants with associated changes in oral function: Five–year outcomes. *Clin Oral Implants Res.* 2019;30(6):570-77.

- 127.Moraschini V, Poubel LA, Ferreira VF, Barboza Edos S. Evaluation of survival and success rates of dental implants reported in longitudinal studies with a follow-up period of at least 10 years: a systematic review. *Int J Oral Maxillofac Surg*. 2015;44(3):377-88.
- 128.de Souza RF, Ribeiro AB, Della Vecchia MP, Costa L, Cunha TR, Reis AC, et al. Mini vs. Standard Implants for Mandibular Overdentures: A Randomized Trial. *J Dent Res*. 2015;94(10):1376-84.
- 129.Griffitts TM, Collins CP, Collins PC. Mini dental implants: an adjunct for retention, stability, and comfort for the edentulous patient. *Oral Surg Oral Med Oral Pathol Oral Radiol Endod*. 2005;100(5):e81-4.
- 130.Hasan I, Madarlis C, Keilig L, Dirk C, Weber A, Bourauel C, et al. Changes in biting forces with implant-supported overdenture in the lower jaw: A comparison between conventional and mini implants in a pilot study. *Ann Anat*. 2016;208:116-22.
- 131.Klein MO, Schiegnitz E, Al-Nawas B. Systematic review on success of narrow-diameter dental implants. *Int J Oral Maxillofac Implants*. 2014;29 Suppl 1:43-54.
- 132.Mundt T, Schwahn C, Biffar R, Heinemann F. Changes in Bone Levels Around Mini-Implants in Edentulous Arches. *Int J Oral Maxillofac Implants*. 2015;30(5):1149-55.
- 133.Mundt T, Schwahn C, Stark T, Biffar R. Clinical response of edentulous people treated with mini dental implants in nine dental practices. *Gerodontology*. 2015;32(3):179-87.
- 134.Scepanovic M, Calvo-Guirado JL, Markovic A, Delgado-Ruiz R, Todorovic A, Milicic B, Misic A. 1-year prospective cohort study on mandibular overdentures retained by mini dental implants. *Eur J Oral Implantol*. 2012;5(4):367-79.
- 135.Schiegnitz E, Al-Nawas B. Narrow-diameter implants: A systematic review and meta-analysis. *Clin Oral Implants Res*. 2018;16 Suppl 29:21-40.
- 136.Brocard D, Barthet P, Baysse E, Duffort JF, Eller P, Justumus P, et al. A multicenter report on 1.022 consecutively placed ITI implants: a 7-year longitudinal study. *Int J Oral Maxillofac Implants*. 2000;15(5):691-700.

137. Karoussis IK, Brägger U, Salvi GE, Bürgin W, Lang NP. Effect of implant design on survival and success rates of titanium oral implants: a 10-year prospective cohort study of the ITI Dental Implant System. *Clin Oral Implants Res.* 2004;15(1):8-17.
138. Misch CE, Perel ML, Wang HL, Sammartino G, Galindo-Moreno P, Trisi P, et al. Implant success, survival, and failure: the International Congress of Oral Implantologists (ICOI) Pisa Consensus Conference. *Implant Dent.* 2008;17(1):5-15.
139. Simonis P, Dufour T, Tenenbaum H. Long-term implant survival and success: a 10–16-year follow-up of non-submerged dental implants. *Clin Oral Implants Res.* 2010;21(7):772-7.
140. Zarb GA, Albrektsson T. Towards optimized treatment outcomes for dental implants. *J Prosthet Dent.* 1998;80(6):639-40.
141. Jemt T. Implant failures and age at the time of surgery: A retrospective study on implant treatments in 4585 edentulous jaws. *Clin Implant Dent Relat Res.* 2019;21(4):514-20.
142. Tawil G, Younan R, Azar P, Sleilati G. Conventional and advanced implant treatment in the type II diabetic patient: surgical protocol and long-term clinical results. *Int J Oral Maxillofac Implants.* 2008;23(4):744-52.
143. De la Rosa M, Rodríguez A, Sierra K, Mendoza G, Chambrone L. Predictors of peri-implant bone loss during long-term maintenance of patients treated with 10-mm implants and single crown restorations. *Int J Oral Maxillofac Implants.* 2013;28(3):798-802.
144. Slade GD, Spencer AJ. Development and the evaluation of the Oral Health Impact Profile. *Community Dent Health.* 1994;11(1):3-11.
145. John MT, Reissmann DR, Feuerstahler L, Waller N, Baba K, Larsson P, et al. Exploratory factor analysis of the Oral Health Impact Profile. *J Oral Rehabil.* 2014;41(9):635-43.
146. John MT, Reißmann DR, Feuerstahler L, Waller N, Baba K, Larsson P, et al. Factor analyses of the Oral Health Impact Profile – overview and studied population. *J Prosthodont Res.* 2014;58(1):26-34.



147. John MT, Feuerstahler L, Waller N, Baba K, Larsson P, Celebić A, et al. Confirmatory factor analysis of the Oral Health Impact Profile. *J Oral Rehabil.* 2014;41(9):644-52.
148. Reissmann DR, John MT, Feuerstahler L, Baba K, Szabó G, Čelebić A, et al. Longitudinal measurement invariance in prospective oral health-related quality of life assessment. *Health Qual Life Outcomes.* 2016;14:88.
149. Peršić S, Čelebić A. Influence of different prosthodontic rehabilitation options on oral health-related quality of life, orofacial esthetics and chewing function based on patient reported outcomes. *Qual Life Res.* 2015;24(4):919-26.
150. Disha V, Čelebić A, Rener-Sitar K, Kovačić I, Filipović Zore I, Peršić S. Mini dental implant-retained removable partial dentures: treatment effect size and 6-months follow-up. *Acta Stomatol Croat.* 2018;52(3):184-92.
151. Peršić S, Kranjčić J, Pavičić DK, Mikić VL, Čelebić A. Treatment Outcomes Based on Patients' Self-Reported Measures after Receiving New Clasp or Precision Attachment-Retained Removable Partial Dentures. *J Prosthodont.* 2017;26(2):115-22.
152. Tyrovolas S, Koyanagi A, Panagiotakos DB, Haro JM, Kassebaum NJ, Chrepa V, et al. Population prevalence of edentulism and its association with depression and self-rated health. *Sci Rep.* 2016;6:370-83.

## 8. BIOGRAPHY

Visar Disha was born on September the first 1989 in Prishtina, Republic of Kosovo. He has finished three years of primary school in Retkovec, Zagreb. Then he continued the rest of the primary school in Prishtina. He excelled in biology and chemistry competition, winning first place in the region of Kosovo throughout primary school.

In the year 2006, he won the gold medal in World Olympiad in chemistry and biology in Istanbul, Turkey. He finished high school in Mehmet Akif College, Kosovo, where he was elected valedictorian. In December 2014, he graduated from the University of Medicine, Department of Dentistry in Prishtina, Kosovo, with a GPA of 5.0., winning the University scholarship for attending the highest GPA for six years in a row.

Visar Disha started the specialization in Prosthodontics in May 2017 in Prishtina, Kosovo, and he also started Specialisation in Orthodontics at Aldent University of Albania. He has completed several workshops in esthetics in Belgrade and Albania about the latest methods of skin rejuvenation. Visar Disha is fluent in Turkish, English, and Croatian language. He also speaks Italian and German, and he is learning French language.

Visar Disha is currently working in a private dental office as a dentist and as a teaching assistant at the University of Pristina, where he teaches undergraduate dental students courses of Removable and Fixed Prosthodontics, Gnathology, and Dental Materials.

He won the 3<sup>rd</sup> place award for a poster presentation at the 5<sup>th</sup> Congress of HDSP, held in Panorama Zagreb, on the 14<sup>th</sup> and 15<sup>th</sup> of June, 2019.

## LIST OF PUBLICATIONS

**Disha V.** Čelebić A. Rener-Sitar K. Kovačić I. Filipović-Zore I. Peršić S. Mini Dental Implant-Retained Removable Partial Dentures: Treatment Effect Size and 6-Months Follow-up. *Acta Stomatol Croat.* 2018;52(3):184-192.

Kovačić I, Peršić S, Kranjčić J, **Disha V**, Rener-Sitar K, Čelebić A. Short-term Postoperative Pain and Swelling Associated with Mini and Standard-Size Implants in the Same Patients. *Int J Prosthodont.* 2018;31(2):117-119.

## ABSTRACTS IN BOOKS OF ABSTRACTS

Peršić S, Kovacic I, Kranjcic J, **Disha V**, Celebic A. The 3-years longitudinal study of mini dental implants for retention of removable partial denture in kennedy class 1 patients. *EPA-Sepes Digital natives in prosthodontics.* Madrid, 2018;133-133.

Kovacic I, Vojvodic D, Persic S, **Disha V**, Kranjcic J, Celebic A. Podupiranje i dodatna retencija teleskopskih proteza sa malim brojem zuba nosača pomoću mini implantata . *Acta stomatologica Croatica;* 68-69.

Celebic A, Persic S, Kranjcic J, **Disha V**, Kovacic I. Postoperative pain and swelling after receiving mini and standard implants. *Current concept and paradigm shifts in Prosthodontics.* Bukurešt, 2017; 127-127.

Persic S, **Disha V**, Kovacic I, Kranjcic J, Vojvodic D, Celebic A. Preliminary clinical report of a success of mini dental implants in strategic positions as retention and support for partial removable dentures in patients with linear or almost linear tooth support and low number of remaining teeth. *ITI World Symposium, 2017. Poster Abstract Booklet.* Basel, 2017; 35-35.

Celebic A, Kovacic I, **Disha V**, Topic J, Poljak-Guberina R, Persic S. Mini-implants supported Kennedy Class I removable partial dentures - a 3-year follow-up outcomes. *EPA 2019, Amsterdam. Book of abstracts* 147.

## AWARDS:

The third award for the best poster presented in Zagreb at the 5<sup>th</sup> Conference of the Croatian Prosthodontic Association, 14<sup>th</sup> -15<sup>th</sup> June, 2019., entitled: "Periimplant bone loss and clinical outcomes of mini-dental implants inserted in first premolar or canine sites supporting removable partial dentures in Kennedy Class I patients: A 3-year cohort study", by authors: Visar Disha, Asja Čelebić, Ines Kovačić, Josip Kranjčić, Jolanda Topić and Sanja Peršić