

Evaluation of vision-related quality of life in patients after vitrectomy following idiopathic epiretinal membrane

Bajraktari, Gentian

Doctoral thesis / Disertacija

2023

Degree Grantor / Ustanova koja je dodijelila akademski / stručni stupanj: **University of Zagreb, School of Medicine / Sveučilište u Zagrebu, Medicinski fakultet**

Permanent link / Trajna poveznica: <https://um.nsk.hr/um:nbn:hr:105:705291>

Rights / Prava: [In copyright](#)/[Zaštićeno autorskim pravom.](#)

Download date / Datum preuzimanja: **2024-06-29**



Repository / Repozitorij:

[Dr Med - University of Zagreb School of Medicine Digital Repository](#)



UNIVERSITY OF ZAGREB
SCHOOL OF MEDICINE

Gentian Bajraktari

**Evaluation of vision-related quality of
life in patients after vitrectomy
following idiopathic epiretinal
membrane**

DISSERTATION



Zagreb, 2023.

UNIVERSITY OF ZAGREB
SCHOOL OF MEDICINE

Gentian Bajraktari

**Evaluation of vision-related quality of
life in patients after vitrectomy
following idiopathic epiretinal
membrane**

DISSERTATION

Zagreb, 2023.

This dissertation was made at the Department of Ophthalmology, University Hospital Center Zagreb, Croatia.

Mentor: Assoc. Prof. Tomislav Jukić MD, PhD.

Acknowledgment

I would like to express my sincere gratitude and appreciation to all those who have supported me throughout the journey of completing my dissertation.

First and foremost, I am deeply grateful to my mentor Assoc. Prof. Tomislav Jukić for his invaluable guidance, unwavering support, and expert supervision. I am truly fortunate to have had the opportunity to learn from his expertise and mentorship.

Furthermore, I would like to express my deepest appreciation to my family for their unwavering love, encouragement, and understanding throughout this endeavor. Their continuous support, belief in my abilities, and sacrifices have been the pillars of my strength, enabling me to persevere through challenges and reach the completion of this dissertation.

Lastly, I would like to extend my heartfelt gratitude and appreciation to the director and my colleagues of the Department of Ophthalmology, University Hospital Center Zagreb for their unwavering support and assistance throughout my work.

TABLE OF CONTENTS

1.	INTRODUCTION AND BACKGROUND.....	1
1.1	Overview.....	1
1.2	Definition.....	2
1.3	Anatomy of the Eye.....	2
1.4	Epidemiology.....	4
1.5	Risk factors.....	5
1.6	Etiology.....	6
1.7	Pathophysiology.....	8
1.8	Clinical manifestation.....	10
1.9	Diagnosis.....	12
1.10	Management.....	13
1.11	Predictive factors.....	14
1.12	Pars plana vitrectomy.....	14
1.13	National Eye Institute Visual Functioning Questionnaire – 25.....	16
1.14	Conversion to surgery.....	17
2.	HYPOTHESIS.....	20
3.	AIMS AND PURPOSE.....	21
3.1	Aims of the research.....	21
3.2	Purpose of the research.....	21
4.	MATERIALS AND METHODOLOGY.....	22
4.1	Study population.....	22
4.2	Criteria for the selection of participants.....	22
4.3	Study plan.....	23
4.4	Ethical consideration.....	26
4.5	Statistical analysis.....	26
5.	RESULTS.....	27
6.	DISCUSSION.....	43
6.1	Study limitation.....	51

7.	CONCLUSION.....	52
8.	ABSTRACT IN CROATIAN.....	53
9.	ABSTRACT IN ENGLISH.....	55
10.	REFERENCES.....	56
11.	CURRICULUM VITAE.....	70

LIST OF ABBREVIATIONS

AMD	Age-related macular degeneration
BCVA	Best corrected visual acuity
BDES	Beaver Dam Eye Study
BES	Beijing Eye Study
BMES	Blue Mountains Eye Study
BSS	Balanced salt solution
C2F6	Hexafluoroethane
C3F8	Octafluoropropane
CMT	Central macular thickness
CS	Contrast sensitivity
DORC	Dutch Ophthalmic Research Center
DR	Diabetic retinopathy
ECM	Extracellular matrix
EIFL	Ectopic inner foveal layers
EM	Epiretinal membrane
ETDRS	Treatment diabetic retinopathy study
HES	Handan Eye Study
HRQoL	Health-related quality of life
IEM	Idiopathic epiretinal membrane
ILM	Internal limiting membrane
INL	Inner nuclear layer

IOP	Intraocular pressure
JES	Jiangning Eye Study
KES	Kailuan Eye Study
KNHNES	Korea National Health and Nutrition Eye Study
LLES	Los Angeles Latino Eye Study
LOCS	Lens Opacification Classification System
LogMAR	Logarithm of the minimum angle of resolution
MCCS	Melbourne Collaborative Cohort Study
MH	Macular hole
NEI	National Eye Institute
OAG	Open-angle glaucoma
OCT	Optical coherence tomography
PPV	Pars plana vitrectomy
PVD	Posterior vitreous detachment
PVR	Proliferative vitreoretinopathy
QCS	Questionnaire composite score
QOL	Quality of life
RPE	Retinal pigment epithelium
RRD	Rhegmatogenous retinal detachment
SEEDS	Singapore Epidemiology of Eye Disease study
SEM	Secondary epiretinal membrane
SF6	Sulfur hexafluoride
SIEYS	Singapore Indian Eye Study

SMEYS	Singapore Malay Eye Study
TGF	Transforming growth factor
VA	Visual acuity
VEGF	Vascular endothelial growth factor
VFQ-25	25-Item Visual Function Questionnaire
VMT	Vitreomacular traction
VR-QOL	Vision-related quality of life
YAG	Yttrium-Aluminum-Garnet

1. INTRODUCTION AND BACKGROUND

1.1 Overview

Epiretinal membrane (EM) is a common disease in the worldwide population, with an overall prevalence of 7 %, that affects the inner surface of the retina over the macula. Because of retinal wrinkling, EM is responsible for reduced central visual acuity, visual disturbances, and as well as the impact on quality of life. After diagnosing, the only medical management for EM is surgery respectively pars plana vitrectomy.

The first paper regarding the successful removal of EM was published in 1978 by Machemer (1). After that time, many reports showed favorable visual results postoperatively. Visual acuity, central macular thickness, aniseikonia, and metamorphopsia improve in many patients after successful surgery, even though metamorphopsia may still be present despite improvement of visual acuity even in the successful removal of EM (2).

Visual acuity reduction and metamorphopsia are the most common conditions regarding the deterioration of vision-related quality of life (VR-QOL) in patients with EM. The measuring instrument of VR-QOL is The National Eye Institute 25-Item Visual Function Questionnaire (NEI VFQ-25) which has been designed to evaluate patients' perception of their visual function and QOL (3). NEI VFQ-25 has been widely used for many ocular pathologies such as rhegmatogenous retinal detachment (RRD), age-related macular degeneration (AMD), macular hole (MH), glaucoma, cataract, keratoconus and diabetic retinopathy (DR) (4-11).

Some studies used balanced salt solution (BSS) or air as a tamponade after idiopathic epiretinal membrane (IEM) surgery and compared these two tamponades in terms of best corrected visual acuity (BCVA), intraocular pressure (IOP), metamorphopsia, central macular thickness (CMT), and contrast sensitivity (CS). Also, some studies measured VRQoL after epiretinal membrane surgery regardless of the tamponade that was used. Although, until now no study compared VRQoL between these two tamponades. This is the first study that compares VRQoL between two groups after idiopathic epiretinal membrane surgery.

1.2 Definition

The epiretinal membrane (EM) can be defined as a proliferation of retinal cells such as RPE cells, glial cells, myofibroblasts, hyalocytes, macrophages, etc., in the inner surface of the macula resulting in the formation of a pathological thin tractional membrane responsible for visual disturbances.

EM was first described by Iwanoff in 1865, and since then it has been called by various names, including epimacular membrane, cellophane maculopathy, preretinal macular gliosis, preretinal macular fibrosis, macular pucker, preretinal vitreous membrane, epiretinal astrocytic membrane, surface wrinkling maculopathy, internoretinal fibrosis and silk-screen retinopathy (13).

1.3 Anatomy of the Eye

The human eye is a specialized sensory organ, placed in orbit, that receives visual images and transmits them to the brain.

The eye is made up of three layers: the outermost layer consists of the cornea and sclera, the middle layer consists of the uvea (iris, ciliary body, and choroid), and the innermost layer consists of the retina. The space between the cornea and lens consists of two chambers: anterior and posterior chamber, filled by humor aqueous and separated by the iris and anterior part of the lens. The space between the lens and retina is filled by the vitreous body, a transparent gel that adheres to the retina (Figure 1) (14).

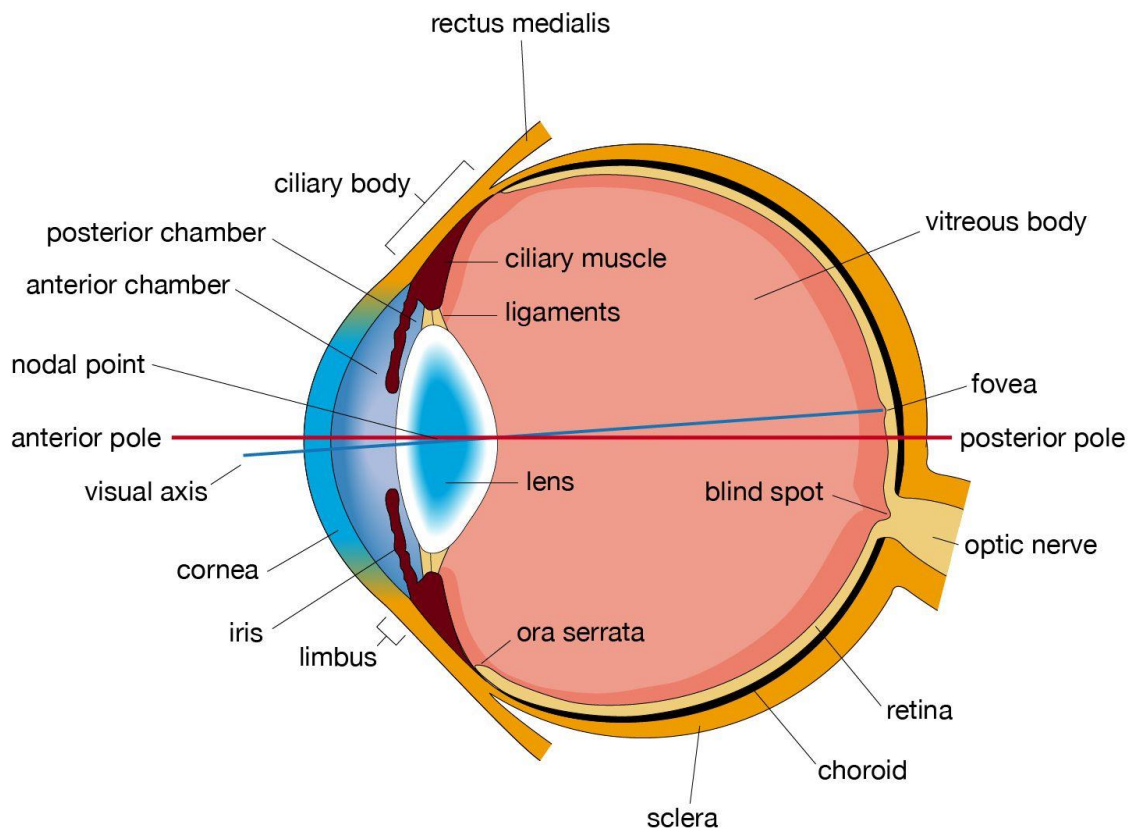


Figure 1. Cross section of the human eye. Adapted from: Perkins ES, Davson H. Human eye. In Encyclopaedia Britannica [internet]. Chicago (IL): Encyclopaedia Britannica; c2023 [cited 2023 May 24]. Available from: <https://www.britannica.com/science/human-eye#/media/1/1688997/100415>. Figure, Cross section of the human eye (14)

The retina is the innermost layer of the eye, which from inside faces the vitreous body and from outside the choroid. Anteriorly continues with the ciliary body and posteriorly forms the optic nerve that connects the eye with the brain. The retina is made of ten layers:

1. Pigment epithelium layer
2. Layer of rods and cones
3. External limiting membrane
4. Outer nuclear layer

5. Outer plexiform layer
6. Inner nuclear layer
7. Inner plexiform layer
8. Ganglion cell layer
9. Optic nerve fiber layer
10. Internal limiting membrane

The epiretinal membrane formation results from the proliferation of the cells on the surface between the internal limiting membrane and the posterior surface of the vitreous body in the macula region (15).

1.4 Epidemiology

Epiretinal membrane (EM) remains a common disease in the worldwide population causing visual distortion and a negative impact on the vision-related quality of life (VRQOL) depending on the stage of the disease. Earlier the epidemiology of EM was derived from population-based studies using ophthalmoscopy or retinal photography. Based on these criteria, the first studies reported a prevalence of idiopathic epiretinal membrane (IEM) of 7% and 11.8% (16,17), with a 5-year cumulative incidence of 5.3% (18). From 19.5% (17) to 31% (16) of IEM was bilateral, where 13.5% was a 5-year incidence involving the second eye (18).

Lately, the usage of Optical Coherence Tomography (OCT) has been widely spread for the detection and determining the prevalence of EM. In the 20-year follow-up study of BDES, using OCT for EM detection, from 1540 participants, 525 of them had EM with a prevalence of 34.1% (19), which is much higher than 11.8% when they used retinal photography (17). According to a meta-analysis of 13 population-based studies, the total prevalence of EM is 9.1% (20).

Unfortunately, until now there is no data on the prevalence of EM in the population of the Republic of Croatia.

1.5 Risk factors

Age: the older population is more likely to develop EM. Postmortem studies suggest a 2% frequency in people over the age of 50 and up to 20% in the population over the age of 75 (13). Based on the BMES study report, increasing age will increase the prevalence of EM from 1.9% under 60 years old, to 7.2% 60-69 years old, to 11.6% 70-79 years old, but after 80 and older, there was a decline to 9.3% (16). The MCCC study has found an increased prevalence of 17% in people over 80 years old, otherwise, other age groups were found to be similar to the BMES study (21).

Ethnicity: The reported frequency of EM varies considerably among different ethnicities and countries. BMES and MCCC studies reported a prevalence of 7% (16) and 8.9% (21) in Australia; BDES and LLES reported 11.8% (17) and 18.7% (22) in the United States; SIEY, SMEY, and SEED reported 7.6% (23), 7.9% (24) and 12.1% (25) in Singapore; BES, HES, JES, and KES reported 1.02% (26), 2.2% (27), 3.4% (28), 7.3% (29) and 7.6% (30) in China; KNHNES study reported a prevalence of 2.9% (31) in the population of Korea.

Race: Some studies reported a prevalence among different racial groups. In 5960 US citizens, EM was found to be much more common among Chinese people (39%) than Hispanics (29.3), whites (27.5%), or blacks (26.2%) (32). When compared to Indians (8.7%) and Malays (7.9%) in the Singapore population, the SEED study found that Chinese people had the highest prevalence (13.0%) (25). The prevalence of EM was more than twice as high in Malays (15.8%) when compared to Caucasians (6.8%) based on the BMES study (24). Otherwise, in the Fungata study, Japanese people had a prevalence of 5.7%, which was equal to Caucasians (33). True ethnic variations in the occurrence of EMs might be related to genetic or lifestyle differences (25), although epidemiologic data for this is currently lacking.

Gender: even though gender does not seem to be any major risk factor, some studies have shown that females have a slightly higher prevalence than males (16,20,24).

Refractive errors: the relationship between EM and refractive errors is not still consistent, where some studies show an association of EM with myopia (28), and some others show it with hyperopia (24).

Smoking: one study has unexpectedly reported that smoking was related to a significantly decreased risk of EM (34).

Others: EM has been also associated with diabetes and hypercholesterolemia (28,32).

1.6 Etiology

EM can be divided into 2 groups based on etiology:

1. Idiopathic Epiretinal Membrane
2. Secondary Epiretinal Membrane

Idiopathic Epiretinal Membrane (IEM) is a condition when no other ocular abnormalities have been found or only posterior vitreous detachment (PVD) is present. Some publications try to further distinguish patients with a PVD by referring to them as having a Primary rather than an IEM (35). PVD is present in 78% to 95% of IEMs (36,37), taking its role in the pathogenesis of IEM.

Secondary Epiretinal Membrane (SEM) is a condition supposed to be caused by a concomitant or previous ocular pathology. SEMs account for 32.3% of all EMs (24), with the most common reasons such as previous cataract surgery (16,17), DR (17), and retinal vein occlusion (16,24). According to one research, 11.2% of eyes without EM, after cataract surgery may develop EM during the next 3 years (39).

Table 1 shows all causes of EM.

Table 1. Etiology of EM

1. Idiopathic
❖ No pathology
❖ PVD
2. Secondary
❖ Iatrogenic
• Cataract surgery
• Vitrectomy surgery
• Retinopexy
❖ Retinal vascular disease
• Diabetic retinopathy
• Retinal vascular occlusive disease
• Coat's disease
• Retinal arteriolar macroaneurysm
• Radiation retinopathy
• Sickle-cell retinopathy
❖ Uveitis
❖ Retinal tears or detachment
❖ Associated with other vitreomacular traction disorders
• Macular hole
• Vitreomacular traction syndrome
❖ Pathological myopia
❖ Trauma
❖ Intraocular tumors
• Retinal (“capillary”) haemangioblastoma
• Vasoproliferative tumor
• Choroidal melanoma
• Combined hamartoma of the retina and retinal pigment epithelium
• Retinal astrocytic hamartoma
❖ Age-related macular degeneration
❖ Retinal dystrophies
• Retinitis pigmentosa
❖ • Neurofibromatosis Type 2

Adapted from: Fung AT, Galvin J, Tran T. Epiretinal membrane: A review. Clin Exp Ophthalmol. 2021;49(3):289-308. Table 1, Aetiology of epiretinal membranes; p. 291 (38).

1.7 Pathophysiology

Even though there is still no exact evidence describing the pathophysiology of EM, all the theories relate to vitreous changes in the formation of EM. Vitreous is a gel-like liquid that fills the posterior inner space of the eye. It contains mostly water, collagen, hyaluronan, and hyalocytes (40). Vitreous mostly is attached to the peripheral retina, optic disc, retinal vessels, and perimacular region. With age, vitreous liquefies and its retinal attaches start to weaken, which leads to the separation of the vitreous from its attachments, causing posterior vitreous detachment (PVD), which has been described especially in IEM as a causative factor up to 95% (37).

Until now, there are three theories describing the initial pathogenesis of EM. One theory was proposed by Foos in 1974 (41). He hypothesized that PVD will cause some cleavage in the internal limiting membrane (ILM), through which retinal glial cells will migrate to the retinal surface (42-44). Because breaks have been found to be relatively uncommon in ILMs related to EMs, somehow this theory has been challenged (45). Another, more widely accepted theory regarding EM formation, involves anomalous PVD occurrence, whereby EM develops from metaplasia and growth of the hyalocytes on the retinal surface (46,47). However, these theories fail to explain why EMs exist in the absence of PVD. And third theory tries to explain why RPE cells are frequently seen in IEM and their migration to the surface of the retina through microdefects (48). With all this information and deficiencies, there is still no general agreement regarding the pathophysiology of EMs. Figure 2 shows the pathogenesis hypothesis of EM (38).

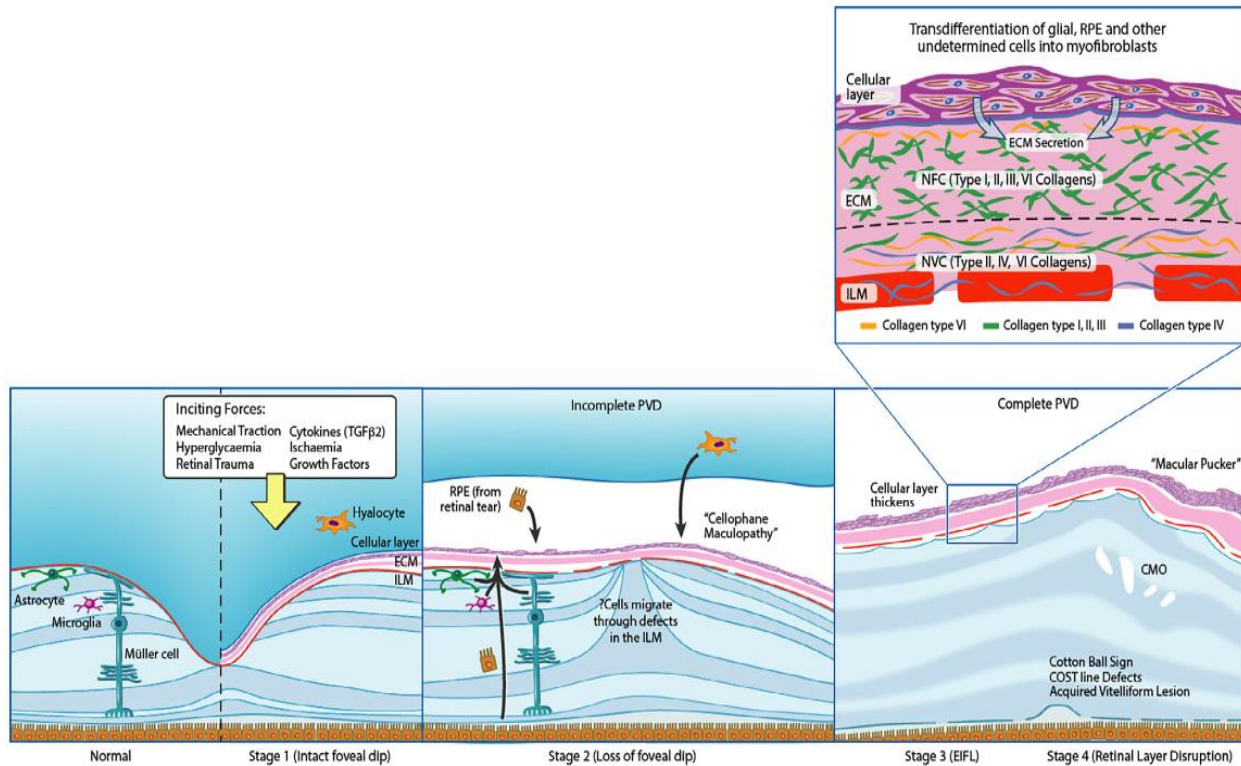


Figure 2. Pathogenesis of EM formation. Adapted from: Fung AT, Galvin J, Tran T. Epiretinal membrane: A review. Clin Exp Ophthalmol. 2021;49(3):289-308. Figure 1, Pathogenesis of epiretinal membrane (EM) formation; p. 292 (38).

It has been documented that, different cells originating from the vitreous and retina are responsible for the formation of EM. The components that have been seen in EM are:

- Cellular components such as glial cells, hyalocytes, RPE cells, macrophages, fibroblasts and myofibroblasts, and TGF-β.
- Extracellular matrix component – secreted and synthesized by myofibroblasts and glial cells.

Glial cells that have been implicated in the formation of EM are microglia, astrocytes, and Muller cells. They are assumed to play a major role in the development of fibroproliferative tissue of EM and proliferative vitreoretinopathy (PVR) after the initial injury (49). They proliferate as a layer on the ILM after migrating onto the retinal surface through defects in the ILM. They are

responsible for extracellular collagen production and differentiation into myofibroblasts (41,50). Glial cells are considered predominant cells in early IEM (51).

Hyalocytes are monocyte/macrophage origin phagocytes, that are in higher concentration at the posterior pole and vitreous base (52). Hyalocytes are most likely derived from cortical vitreous remains after an abnormal PVD. Kohno et al have mentioned that hyalocytes play an important role in contractile properties in EM through the effect of TGF- β 2 in the vitreous fluid (53).

It has been reported that RPE cells are responsible for the formation of SEM (54), and have been not or rarely found in IEM and in traction vitreo-retinopathies (55-60). The migration of RPE on the surface of the retina is still unclear. It has been postulated that they migrate through ILM brakes, and then may undergo transdifferentiations.

The role of macrophages in EM formation is still unclear. Mostly they have been found in SEM, especially after vitreous hemorrhage (51).

Fibroblasts and myofibroblasts through generating collagen, are mentioned to have a role in the pathophysiology of IEM especially the late form of IEM. Myofibroblasts may be responsible for the contractile properties of late IEMs, through the secretion of contractile proteins which induce intracellular contractions (38).

TGF- β is a cytokine that plays a role as a mediator of myofibroblastic transdifferentiating fibrosis in EMs and PVR. It has been reported that TGF- β is activated through mechanical stress (43,61).

The extracellular matrix (ECM) is composed of extracellular collagen fibrils (type I, II, III, IV, and VI) with fragments of ILM (62). It is produced and secreted by glial cells and myofibroblasts in the cellular layer of EM. ECM is mainly responsible for the pathogenesis of IEM.

1.8 Clinical manifestation

Most of the patients are asymptomatic in the early stage of EM and are routinely discovered during a normal ophthalmological evaluation. The severity of symptoms depends on the degree of retinal distortion, the location of the wrinkling, the thickness of the membrane, and the presence of retinal traction or edema (63). The most common symptom is visual blurring. Normally, vision can be affected if the macular or perimacular area is involved. 78-85 % of patients have visual acuity

better than 20/50, 56-67 % better than 20/30, and only 2-5 % have visual acuity worse than 20/200 (13). As EM progresses, metamorphopsia, micropsia or macropsia, photopsia, diplopia, aniseikonia, and binocular interference may develop. The most common symptoms that affect the quality of life in patients with EM are metamorphopsia and binocular interference (64). They usually affect reading, writing, and most daily activities of living. During fundus examination on slit-lamp, EM can be seen as a hyperreflectivity of the macular region with loss of the regular contour and fine surface wrinkles.

The EM classification system based on retinal photography was first developed by Gass, which nowadays is a standard for assessing the clinical severity of EM (65) (Figure 3):

1. Cellophane maculopathy (grade 0) – thin, translucent membrane in macula without distortion or decrease in vision.
2. Crinkled cellophane maculopathy (grade 1) – transparent, thin EM with distortion of the inner retina.
3. Macular pucker (grade 2) – semi-translucent membrane with distortion of the inner retina. In severe cases may show retinal hemorrhage, exudates, macular edema, macular hole, and pseudohole.

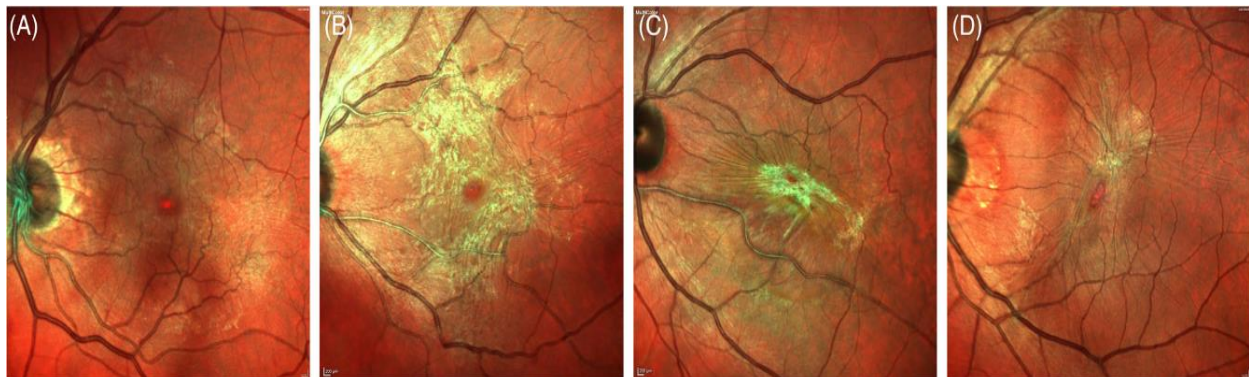

Figure 3. Clinical grading of EM based on the Gass classification: A-stage 0, B-stage 1, C-stage 2, D-pseudohole. Adapted from: Fung AT, Galvin J, Tran T. Epiretinal membrane: A review. Clin Exp Ophthalmol. 2021;49(3):289-308. Figure 3, Clinical grading of epiretinal membrane with synonymous names based on the Gass classification; p. 294 (38).

1.9 Diagnosis

The diagnosis of EM is based on clinical examinations and imaging of the retina (oct, autofluorescence, optical coherence tomography-angiography, fundus fluorescein angiography, and electroretinography).

Optical Coherence Tomography (OCT) – is a highly sensitive method in the investigation of retinal pathologies and is a choice in diagnosing EM and vitreomacular traction (VMT). EM in OCT appears like an irregular hyperreflective layer on the surface of the retina. Nowadays, OCT has been widely used for the classification scheme of EM. Govetto et al have proposed EM classification in four stages, depending on the presence or absence of the foveal pit, ectopic inner foveal layers (EIFL), and disorganization of the retinal layers (66) (Figure 4).

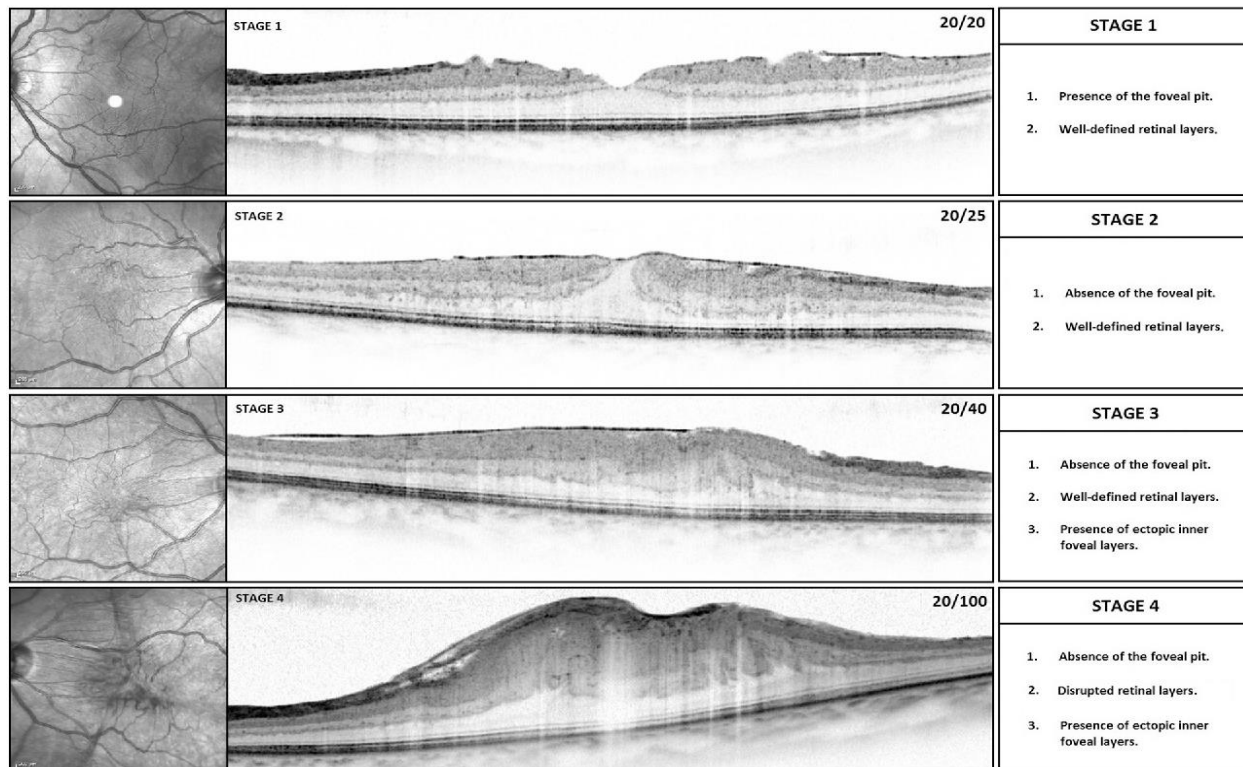


Figure 4. SDOCT staging of EM based on the Govetto et al. classification. Adapted from Govetto A, Lalane RA 3rd, Sarraf D, Figueroa MS, Hubschman JP. Insights Into Epiretinal Membranes: Presence of Ectopic Inner Foveal Layers and a New Optical Coherence Tomography Staging Scheme. *Am J Ophthalmol.* 2017;175:99-113. Figure 3, Proposed optical coherence tomography staging scheme of idiopathic epiretinal membranes; p. 102 (66).

Konidakis et al have divided EM into nine categories, based on retinal morphology with the presence or absence of PVD (67). Stevenson et al have classified EM whether the fovea is involved or not, with the presence or absence of PVD (68). Changes in OCT in EM are widely in use as prognostic markers.

Autofluorescence – can show a tortuosity of retinal vessels.

Fluorescein and OCT-angiography – are only used in the assessment of EM caused by secondary retinal pathologies such as retinal vascular diseases, retinal vasculitis, or vascular tumors (69-71).

Electroretinography (ERG) – many studies have concluded a reduction in ERG response in foveal and parafoveal regions (72-77).

Deep learning – is computer software that has been taught to distinguish the OCT values between normal retina and retina with EM, without the need for professional interpretation. It has a high sensitivity (98.7%) and specificity (98%) (78,79).

1.10 Management

EM is a chronic disease and does not need urgent intervention. Most of the patients with EM only need observation (80). Based on the BMES study over a 5-year follow-up time, most of the eyes remain in stage 0 or 1 and do not progress to pre-macular fibrosis, around 30% have been resolved, and 1 of 10 eyes progress from cellophane maculopathy to macular pucker (18).

Medical management – in IEM there is no medical management, only observing the patients. In SEM, especially in eyes with macular edema, there can be a benefit to using intravitreal anti-VEGF or steroids. In cases of EM with vitreomacular tractions, there is a vitreopharmacolytic agent Ocriplasmin, that is used to resolve vitreomacular traction but has no effect on resolving pre-macular membranes (80).

Surgical management – when the patients complain of reduced visual acuity, metamorphopsia, diplopia, or daily life activities, pars plana vitrectomy should be considered. The purpose of the surgery is to remove the membrane and release the macular traction. In SEM, except for the removal of the membrane, depending on etiology, should also be considered applying retinal laser or cryotherapy, panretinal photocoagulation, intravitreal anti-VEGF, or steroid therapy.

1.11 Predictive factors

Extensive research has been recently reviewed on the factors that can predict postoperative visual functions following EM surgery. The majority of studies have utilized visual acuity (VA) and metamorphopsia as the primary indicators for evaluating the visual outcome after EM peeling surgery. Factors that have been recognized as unfavorable predictors for postoperative VA have been identified as follows: poor preoperative vision, age, long duration of the symptoms, disruption of the ellipsoid zone and cone outer segment, and ectopic inner foveal layer. Noteworthy predictors of postoperative metamorphopsia include a high score for metamorphopsia, high central fovea thickness, disruption of the ellipsoid zone, and increased INL thickness.

1.12 Pars plana vitrectomy

Pars plana vitrectomy (PPV) is a vitreoretinal surgery technique that gives access to the surgeon to the posterior segment of the eye for treating different vitreoretinal pathologies. The name of the technique arises from the removal of the vitreous body from the eye (vitreous + ectomy) and the pars plana of the ciliary body is used to insert instruments into the eye. In 1969, David Kasner first introduced vitrectomy and removal of the vitreous body using the open-sky approach (81). In 1971, the first closed-system vitrectomy was developed by Robert Machemer who used 17-gauge instruments with the pars plana approach, and from that time the technique was known as pars plana vitrectomy (82,83). Nowadays three-port vitrectomy system was introduced by Ralph Heintz and Conor O'Malley in 1974 using 20-gauge instruments. After that, there was continuous innovation in the improvement of surgery such as Robert Machemer and Dyson Hickingbotham introducing the trocar system for the insertion of instruments, Gholam Peyman and Claus Eckardt 23-gauge instrumentation, Gilgo Fuji and Eugene de Juan 25-gauge instrumentation and, in 2010 Yusuke Oshima introduces 27-gauge instrumentation (84-88).

The main indications for PPV are vitreomacular pathologies (macular hole, epiretinal membrane, vitreomacular traction), vitreous hemorrhage, retinal detachment (rhegmatogenous, tractional), vitreous biopsy, endophthalmitis, dislocated intraocular lens, retained lens material, intraocular foreign bodies. The following parts make up the essential elements of a vitrectomy surgery: vitrectomy machine, operating microscope with the wide-angle viewing system, irrigating cannula

(maintaining intraocular pressure by machine), light source, vitreous cutter (vitreous removal, aspiration). Until now, there are known 4 different gauge systems, that represent the diameter of the instruments such as 20-gauge with 0.9 mm diameter, 23-gauge with 0.6 mm diameter, 25-gauge with 0.5 mm diameter, and 27-gauge with 0.4 mm diameter. The most frequently used instruments in PPV are (89): trocar cannulas, endoilluminators, vitreous cutter, forceps, scissors, membrane scrapers, extrusion cannulas, diathermy, endolaser, and fragmatome. To perform surgery safely and effectively, all tissue planes must be well seen, so chromovitrectomy is an essential step in PPV. The most frequently used dyes in vitreoretinal surgeries are:

- Triamcinolone acetonide – called Kenalog, and is mostly used to stain vitreous gel (90)
- Trypan blue – is used to stain the anterior lens capsule during phacoemulsification and EM and ILM during PPV (91)
- Brilliant blue – primarily used to stain ILM with a lower rate of toxicity (92)

The main surgical principles during PPV are removing the vitreous body, relieving the vitreomacular tractions, and restoring the normal anatomical relationships of the retina and retinal pigment epithelium. Membrane peeling is one of the most frequent procedure used during PPV, spatially in epiretinal membranes, macular holes, vitreomacular traction, tractional retinal detachments, and proliferative vitreoretinopathy. After insertion of trocars, core vitrectomy is performed by inducing PVD if it is not already present. After that, a vital dye is instilled to visualize EM and ILM. With forceps, EM and ILM (opposed by some surgeons) are peeled. The most frequently used tamponades to fill the vitreous cavity are BSS, air, sulfur hexafluoride (SF₆), hexafluoroethane (C₂F₆), and octafluoropropane (C₃F₈). The trocars are then removed and suture the sclerotomies if there is a need. The most common complications during and after PPV are (93-95): cataract, glaucoma, endophthalmitis, retinal detachment, retinal tear, hypotony, suprachoroidal effusion, suprachoroidal hemorrhage, vitreous hemorrhage, cystoid macular edema, optic neuropathy, phototoxicity.

In 1978, Machemer was the first author that published a paper that described the successful removal of EM (1). The main surgical principle in EM surgery is restoring the anatomical function of the retina by removing a macular pucker using BSS or air or in some circumstances SF₆ as an intraocular tamponade. Several studies have reported success rates in visual function and anatomical function after removing the macular pucker. Wong et al have reported that 83% of

patients have improved visual acuity and 93% of patients have improved metamorphopsia after PPV (96). Another published paper has claimed that there was an improvement in visual and anatomical functions after surgery but there was no significant difference in terms of visual functions between peeling and not peeling the ILM during surgery (97). Moisseiev et al. have shown that even in elderly patients, membrane peeling is a safe procedure for gaining 2 or more lines of vision in 65.5% of patients (98). Disruption of the photoreceptors caused by EM can also be restored postoperatively (99). Therefore, PPV should be considered in every patient whose reduced visual acuity and metamorphopsia decrease his or her quality of life.

1.13 National Eye Institute Visual Functioning Questionnaire – 25

Health-related quality of life (HRQoL) is a multidimensional concept that includes domains of the general quality of life perception depending on physical, mental, emotional, and social functioning (100). Clinicians and public health employers have measured the effect of chronic illness and treatments in various fields of medicine and health care using HRQoL as an assessment instrument.

Previous studies have demonstrated that ocular illness and possible blindness have a negative influence on HRQoL (101,102). Patients' functional status and physical capabilities are significantly impacted by visual function impairment. Visual impairment may, unfortunately, result in emotional and cognitive problems, social isolation, changes in patients' mental state as well as increased dependency on others (103-107). As a result, ophthalmology has been emphasizing the value of assessing patients' self-reported visual functionality and treatment outcomes for those with visual impairment (108,109).

There is not usually a strong correlation between patients' subjective perception regarding visual impairment and objective measurements such as visual acuity, visual field, and contrast sensitivity because binocular vision and functional ability, which are important for visual functioning, cannot always be measured objectively. This idea defines routine actions that include vision-related procedures (102).

In the measurement of quality of life in patients with ocular diseases, research has shown that vision-related questionnaires are more adaptive than general-related questionnaires (110). National Eye Institute Visual Functioning Questionnaire – 25 (NEI VFQ-25) is one of the widely used

questionnaires for the assessment of the visual function of the quality of life (QoL) which represents an impact of vision impairment on multiple dimensions of HRQoL. The NEI VFQ-25 has been translated, adapted, and validated in Croatian languages as same as in many other languages worldwide (111). The first version of the questionnaire had in total of 51 items, but the newest version NEI VFQ-25 2000 is composed of 25 items that are divided into 12 subscales (3). The first subscale assesses only general health (one item), while 11 others are vision-related subscales such as general vision (one item), ocular pain (two items), near activities (three items), distance activities (three items), social functioning (two items), mental health (four items), role difficulties (two items), dependency (three items), driving (three items), color vision (one item), and peripheral vision (one item). The results are converted to a score between 0 and 100, where the higher score indicates better VRQoL. The NEI VFQ-25 composite score is calculated by simply averaging the vision-target subscale scores, excluding the general health rating question. There are two formats of the questionnaire interviewer format which takes approximately 10 minutes to administer, and the self-administered format which is filled by a patient. The NEI VFQ-25 has been used in many ocular diseases such as cataracts, glaucoma, age-related macular disease, diabetic retinopathy, epiretinal membrane, macular hole, keratoconus, and dry eye (112-119).

Studies suggest that VFQ-25 scores in patients with IEM were improved after PPV showing the role of PPV in epiretinal peeling regardless of intraocular tamponades used during surgery such as BSS, air, and SF6. There is only one study that compared VRQoL between two tamponades air and SF6 (120). Yet until now, there is no definitive data to determine which intraocular tamponade air or BSS provides better results in terms of VRQoL in the short term after PPV in patients with IEM. In this regard, the results from this study will be of particular importance, in order to prove which intraocular tamponade will provide better VRQoL in the short term after surgery.

1.14 Conversion to surgery

While the progression of symptoms or objective signs may seem like obvious reasons to opt for surgery after a period of observation, it is important to note that evidence suggests this is not always the scenario. Baseline features and the persistence of symptoms are indeed significant factors to consider in the decision-making process. Additionally, there is a potential for surgeon bias to

influence the decision to operate, favoring pathologies that they believe are more likely to show surgical improvement or have a higher risk of worsening over time (121).

Luu et al. conducted a retrospective review of 145 eyes that initially had good visual acuity (20/40 or better) and were followed up for a median duration of 3.7 years. According to their findings, the cumulative rates of progression to surgery at year 4 are as follows: 2.9% at year 1, 5.6% at year 2, 12% at year 3, and 21%. Irrespective of functional or anatomical progression, patients who exhibited symptoms of metamorphopsia at baseline were found to be more likely to undergo surgery during the follow-up period. This suggests that the presence of metamorphopsia symptoms played a significant role in the decision to proceed with surgery, regardless of any observed changes in visual function or anatomical factors (122).

Chen et al. conducted a retrospective review of 210 eyes that initially had a visual acuity of 20/40 or better. The results from this study demonstrated that, over a period of 7 years, approximately 13% of eyes with EM and initially good vision progressed to undergo surgery. Furthermore, they indicate a notable pattern in which eyes that had not shown progression by the 4-year mark remained stable without the need for surgery throughout the entire 7-year duration (123).

Kofod et al. conducted a randomized clinical trial involving 53 patients who had symptomatic EM and a best-corrected visual acuity of 20/50 or better at the time of presentation. These patients were randomly assigned to either undergo immediate surgery or to be placed under observation without immediate surgical intervention. Among the patients assigned to this study, a total of eight out of 33 individuals underwent surgery within a 12-month period. The decision for surgical conversion was based on either a significant worsening of visual symptoms or a reduction in visual acuity of two Snellen lines or more (124).

In summary, several preoperative factors have been identified as being associated with the conversion to surgery in individuals with initially good visual acuity. These factors include higher baseline CMT, the presence of external limiting membrane or ellipsoid zone disruption, loss of foveal contour, and the presence of metamorphopsia or other visual symptoms at the time of presentation. These factors indicate a higher likelihood of progressing to surgery in such cases. In general, a range of 10-30% of patients who initially undergo observation without immediate surgery, but present to surgeons with certain conditions, eventually progress to undergo surgical

intervention within a period of 2 to 7 years. This suggests that a notable proportion of patients may experience a progression of their condition that necessitates surgical treatment over time.

2. HYPOTHESIS

- Improvement of vision-related quality of life is better in patients using a balanced salt solution than in patients using air as an intraocular tamponade, in the short time after pars plana vitrectomy

3. AIMS AND PURPOSE

3.1 Aims of the research

General aim:

- To analyze and compare the VRQoL, IOP, BCVA, Amsler test results, CS results, and CMT in three-time points for the air and BSS group.

Specific aims

- To analyze and compare the VRQoL between two groups in three-time points, using air and BSS as an intraocular tamponade, after pars plana vitrectomy.
- To analyze and compare IOP, BCVA, Amsler test results, CS results, and CMT between two groups in three-time points.

3.2 Purpose of the research

The purpose of the research was to determine the satisfaction of the patients diagnosed with EM, in terms of VRQoL in the short-term after surgery. By comparing the operative procedure in regard to the intraocular tamponade that will be used, we evaluated which tamponade provided better VRQoL and visual functions in patients, for a short-term period after the surgery

4. MATERIALS AND METHODOLOGY

4.1 Study population

In this randomized, observer-blind, controlled, cohort study, we included ninety consecutive patients diagnosed with IEM, which were referred for surgery at the University Clinical Center Rebro Zagreb, Department of Ophthalmology, between September 2021 and March 2023. This university hospital is located in the capital city of Croatia.

4.2 Criteria for the selection of participants

Before including in the study, all the patients were evaluated using slit lamp examination, and OCT findings 1-7 days before surgery.

Inclusion criteria:

- a) Patients diagnosed with IEM complaining of visual difficulties and metamorphopsia
- b) Patients with IEM with or without mild cataract based on Lens Opacification Classification System III (LOCS III) reference standards (125): N0, NC, C, P grade 2 or less
- c) Pseudophakic patients with IEM
- d) Patients with IEM who had the capacity to give informed and voluntary consent

Non-inclusion criteria:

- a) Patients diagnosed with glaucoma
- b) Patients diagnosed with AMD
- c) Patients diagnosed with DR
- d) Patients diagnosed with macular hole
- e) Patients with a history of strabismus, amblyopia, or refractive anisometropia
- f) Patients with a history of vitreoretinal surgery
- g) Patients diagnosed with retinal vessel diseases
- h) Patients that have undergone cataract surgery during the last 6 months
- i) Patients diagnosed with any form of uveitis or ocular trauma.

Exclusion criteria:

- a) Patients with any acute eye pathology that might decrease visual acuity or worse metamorphopsia during the study
- b) Patients with any complication during or after surgery such as retinal detachment, vitreous hemorrhage, or any discovered retinal break during surgery that needed laser treatment
- c) Voluntary withdrawal of the patient

In patients who developed posterior capsular opacification after cataract surgery, we performed YAG-laser capsulotomy and waited for three weeks. If there was no post-laser complication then we included patients in the study.

4.3 Study plan

The research began after the written acceptance from the participants in the research. All participants that have reached the inclusion criteria have been equally randomized into two groups. The first group – the Air group, was with 45 participants that vitreous was substituted with air during PPV, and the second group – the Balanced Salt Solution (BSS) group, was with 45 participants that vitreous was substituted with BSS during PPV. To guarantee the randomization effect and to refrain the study from any bias, the placement of participants into the group has been initiated by a coin toss, which was conducted by the same nurse who has also been in possession of a randomization concealment list of groups during all the research. This procedure was done only for the first participant, the upcoming participants have been then divided into groups consecutively.

All patients have undergone detailed examination, evaluating the vision-related quality of life, best corrected visual acuity, intraocular pressure, metamorphopsia, contrast sensitivity, and central macular thickness. All these procedures have been done at three time points: 1-7 days before surgery, 1 month after surgery, and 6 months after surgery.

Vision-related quality of life (VRQOL) was assessed using a self-administered national eye institute 25-item visual function questionnaire (NEI VFQ-25). The questionnaire includes 25 questions (items) in which patients are asked to assess the level of difficulty of particular visual

symptoms or day-to-day activities. Each question is assigned to 1 of 12 subscales, such as general health, general vision, ocular pain, near activities, distance activities, social functioning, mental health, role difficulties, dependency, driving, color vision, and peripheral vision. The subscale scores were then converted to a score between 0 and 100, where 0 represents the lowest capacity or maximal patient impairment and 100 represents the highest capacity or minimal patient impairment. The NEI VFQ-25 composite score was calculated by simply averaging the vision-target subscale scores, excluding the general health rating question (3). The questionnaire was self-administered given and explained by a nurse who provided verbal instructions and assistance when required. No specific qualifications are needed to use the VFQ-25. We used the Croatian version of the VFQ-25, which was modified for use with Croatian people. The reliability and validity of the Croatian VFQ-25 have been reported previously (111).

Best corrected visual acuity (BCVA) was measured in a logarithm of the minimum angle of resolution (LogMAR) score using the early treatment diabetic retinopathy study (ETDRS) chart. LogMAR is an acronym for the base-10 logarithm of the minimum angle resolution and refers to the ability to resolve the elements of an optotype (126). The patient was asked to sit 4 meters in front of the chart, asking to read letters first with the affected eye, after with the fellow eye, and in the end with both eyes using distance correction if needed.

Intraocular pressure (IOP) was measured using the Goldman Applanation Tonometer, which is a non-invasive measurement of IOP that measures the force necessary to flatten an area of the cornea of 3.06 mm in diameter and is based on the Imbert-Flick principle which states that the pressure inside an ideal, dry, thin-walled sphere equals the force necessary to flatten its surface divided by the area of the flattening (127). 1 to 2 drops of tetracaine and fluorescein solutions were applied to the patient's conjunctival sac, and then IOP was measured with values in mmHg.

Metamorphopsia was evaluated using the Amsler grid test, which is a card that contains black grid lines on a white background and a central black dot for fixation. Each eye was tested individually with reading glasses (if needed) at a reading distance. A patient was advised to mark the lines that were precepted distorted while looking in a central black dot. A card had a total of 400 squares and the metamorphopsia score was recorded by the number of distorted squares.

Contrast sensitivity (CS) is a measure of the ability of the visual system to distinguish an object against its background (128). CS was measured using the Pelli-Robson chart. The chart has 8

horizontal lines with letters arranged in groups whose contrast varies from high to low. The patient was asked to sit 1 meter in front of the chart and to read the letters, starting with the highest contrast level, until they were unable to read two or three letters in a single group, first with the affected eye, after with the fellow eye, and in the end with both eyes using refractive correction if needed. The scores were recorded in the Pelli Robson scoring sheet as a logarithm of CS. The higher the score, the patient has better CS, and the lower the score, the patient has worse CS.

Central macular thickness (CMT) was measured using optical coherence tomography (SOCT Copernicus HR, Optopol Technology S.A., Zawiercie-Poland). OCT is a non-invasive, non-contact imaging system providing high micrometer-resolution, cross-sectional images of the ocular tissue. OCT is analogous to B-scan ultrasonography but uses near-infrared light interferometry rather than sound waves, with images created by the analysis of interference between reflected reference waves and those reflected by tissue (129). OCT was performed with the macular thickness map mode covering the macular region 6x6 mm, and CMT values were recorded from the retinal map analysis function.

Pars plana vitrectomy (PPV) was performed only by a single surgeon using a 23-Gauge Constellation surgical vitrectomy system (Alcon Laboratories Inc, Fort Worth, Texas, USA) and surgical microscope Zeiss Lumera 700 with Resight system, under retrobulbar block local anesthesia (5 ml equal mixture of 2% lidocaine and 0.75% bupivacaine) and intravenous sedation with monitored anesthesia care. In all phakic patients, the lens was removed by phacoemulsification and the intraocular lens (Sensor - Johnson and Johnson) was implanted. After the patient was prepared for surgery, the surgeon washed the conjunctiva sac with a solution of povidone-iodine 5%, performed phacoemulsification with intraocular lens implantation in phakic eyes, then inserted cannulas (trocars) at an oblique angle in the inferotemporal, superotemporal, and superonasal quadrants 4 mm to the limbus in phakic patients and 3.5 mm in pseudophakic patients using trocars. A core vitrectomy was performed and PVD induced if it was not already present and then continued with peripheral vitrectomy. To visualize the EM and internal limiting membrane, trypan blue and brilliant blue G dye (Membraneblue – Dual; Dutch Ophthalmic Research Center - DORC, Rotterdam, Netherlands) 0.1 ml were injected and waited 2 minutes to stain. After that, the EM and ILM were peeled using Eckardt ILM forceps (DORC, Rotterdam, Netherlands). The peeling has been started from the temporal side of the macula and extended until

the temporal macular vascular arcades and optic nerve margin. The periphery was inspected for any retinal tear. In the end, depending on group affiliation, fluid-air exchange was performed to complete intravitreal fill, or BSS (Alcon, Fort Worth, Texas) was left in the eye. Trocars then have been removed and sclerotomies have been sutured with 10.0 nylon suture. After surgery, appropriate therapy was given to the patients. 1 day, 3 days, 1 week, and 1 month after surgery, every patient was examined for any post-surgical complication.

4.4 Ethical consideration

The study has been approved by the Ethics Committee of the University Clinical Center Rebro Zagreb and it was carried out in line with the Helsinki Declaration. Before being included in the study, all patients were detailly informed about the aim and safety of the study before signing the informed consent. Also, they have been informed about their right to withdraw at any time.

4.5 Statistical analysis

All statistical analyses have been performed by using IBM SPSS Statistics for Windows, Version 23.0. Armonk, NY: IBM Corp. Categorical variables have been expressed as percentages and continuous variables have been expressed as mean \pm SD.

The BCVA, IOP, CMT, CS, metamorphopsia score, each VFQ-25 subscale, and the composite scores have been compared between each pair of three-time points by using a paired sample t-test. Mean difference values have been compared between the two groups, the air group and the BSS group, by using an independent t-test. In order to see the differences between variables at the baseline, Pearson's chi-square test has been used for categoric variables, and an independent t-test has been used for metric variables. Multiple regression analysis has been applied to evaluate if there were any preoperative factors impacting QCS. P value < 0.05 was considered statistically significant.

5. RESULTS

Among 92 patients diagnosed with EM, only 90 (45 in the air group and 45 in the BSS group) have been included in the study, while 1 patient had a vitreous hemorrhage after 1 week, and 1 patient withdrew willingly from the study. The demographic variables of the participants are presented in Table 2 and within all parameters, there were no significant differences between the two groups. Among these 90 patients, the mean age was 70.74 ± 5.86 years (range 55-84), 51(57%) were women (Figure 5), only 23(25%) were smokers, and in 59(71%) patients PVD was already present before surgery. Sixty-one patients (67%) were phakic and 29(33%) were pseudophakic in the affected eye. Cataract surgery has been performed on all phakic patients. 63(70%) patients were under hypertensive therapy, and 25(28%) were diabetic. 15(17%) patients experienced Myocardial Infarction prior to PPV.

No significant difference has been noted between groups at baseline in QCS, BCVA, IOP, CMT, metamorphopsia, or CS (Table 3).

No intraoperatively or postoperatively complications, such as subretinal hemorrhage, retinal detachment, choroidal detachment, or endophthalmitis, have been observed.

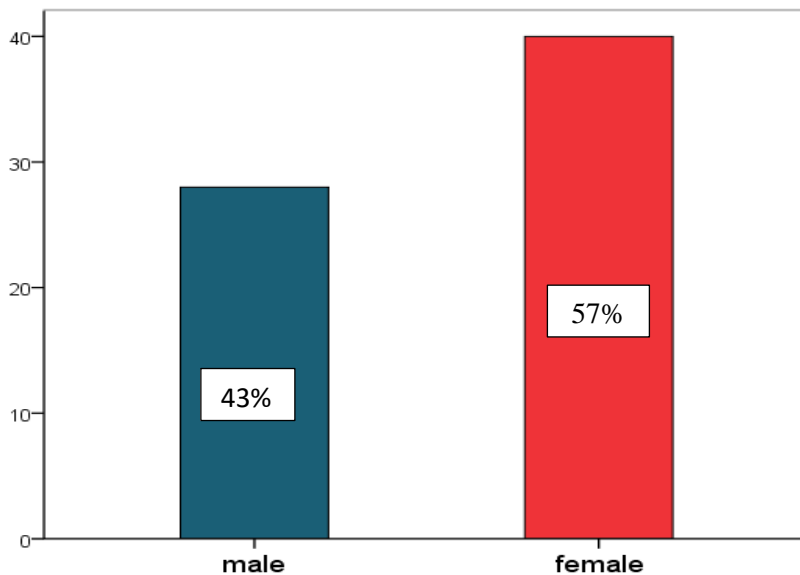


Figure 5. Overall Study Population by Gender.

Table 2. Patients' demographic data.

Parameters	Total (N=90)	AIR (N=45)	BSS (N=45)	P value
Age	70.74±5.86	70.53±6.26	70.94±5.52	0.775†
Sex, male/female	39/51(43%/57%)	16/29(35%/65%)	22/23(49%/51%)	0.139‡
Smoking, yes/no	23/67(25%/75%)	13/32(29%/71%)	10/35(22%/78%)	0.525‡
Operated eye, right/left	47/43(52%/48%)	24/21(53%/47%)	23/22(51%/49%)	1.000‡
PVD presence, yes/no	59/31(71%/29%)	26/19(58%/42%)	32/13(71%/29%)	1.110‡
Lens status, phakic/pseudophakic	61/29(67%/33%)	29/16(64%/36%)	32/13(71%/29%)	0.272‡
Arterial hypertension, yes/no	63/27(70%/30%)	34/11(75%/25%)	29/16(64%/36%)	0.086‡
Diabetes, yes/no	25/65(28%/72%)	16/29(35%/65%)	10/35(22%/78%)	0.072‡
Prior MI, yes/no	15/75(17%/83%)	9/36(20%/80%)	7/38(15%/85%)	0.303‡
Systolic BP	142.01±12.46	141.14±11.99	142.88±13.04	0.570†
Diastolic BP	85.27±9.46	85.14±11.16	85.41±7.58	0.909†
Pulse, mean	76.11±9.25	76.05±8.51	76.17±10.07	0.959†
Blood Glycemia	5.96±1.60	6.06±1.53	5.86±1.68	0.600†

PVD-posterior vitreous detachment, MI-myocardial infarction, BP-blood pressure. Values are presented as n (%) or mean±standard deviation. †p values derived from independent t-test. ‡p values derived from Pearson's chi-square test. p<0.05 was considered statistically significant.

Table 3. Summary of patients' parameters at baseline.

Parameters	Total (N=90)	AIR (N=45)	BSS (N=45)	P value
QCS	80.85±10.96	79.97±10.42	81.73±11.57	0.514
IOP	14.25±2.17	13.94±1.79	14.55±2.48	0.244
BCVA	0.47±0.19	0.50±0.20	0.45±0.18	0.358
CMT	433.72±81.46	425.73±84.80	441.70±78.43	0.423
CS	1.10±0.25	1.14±0.23	1.06±0.27	0.182
Metamorphopsia	216.69±39.88	208.52±40.60	224.85±37.99	0.092

BSS-balanced salt solution, QCS-questionnaire composite score, BCVA-best corrected visual acuity, IOP-intraocular pressure, CMT-central macular thickness, and CS-contrast sensitivity. Values are presented as mean±standard deviation. p values derived from independent t-test. p<0.05 was considered statistically significant.

The BCVA, IOP, CMT, CS, and metamorphopsia scores at each time point are presented in Table 4. All four parameters have improved at month 1 and month 6, compared to the baseline values except IOP but there has been no significant difference between the two groups at each time point (Figure 6).

Table 4. Summary of parameters of the air and BSS group over 6 months.

Parameters		Time Point			P Value†		
		Baseline (mean±SD)	Month 1 (mean±SD)	Month 6 (mean±SD)	B vs M1	M1 vs M6	B vs M6
BCVA	Total	0.47±0.19	0.42±0.21	0.26±0.21	<0.001	<0.001	<0.001
	AIR	0.50±0.20	0.44±0.22	0.30±0.22	0.001	<0.001	<0.001
	BSS	0.45±0.18	0.39±0.20	0.23±0.18	0.032	<0.001	<0.001
	P Value‡	0.358	0.395	0.162			
IOP	Total	14.25±2.17	14.20±1.56	14.08±1.73	0.858	0.546	0.433
	AIR	13.94±1.79	14.05±0.98	13.91±1.35	0.624	0.432	0.891
	BSS	14.55±2.48	14.35±1.98	14.26±2.04	0.637	0.799	0.409
	P Value‡	0.244	0.441	0.405			
CMT	Total	433.20±81.46	414.14±76.13	370.47±58.75	0.001	<0.001	<0.001
	AIR	425.73±82.99	408.20±76.83	374.20±64.87	0.001	<0.001	<0.001
	BSS	441.70±78.43	420.08±76.10	366.73±52.64	0.043	<0.001	<0.001
	P Value‡	0.423	0.524	0.604			
CS	Total	1.10±0.25	1.14±0.23	1.26±0.48	0.056	<0.001	<0.001
	AIR	1.14±0.23	1.16±0.25	1.26±0.18	0.609	<0.001	<0.001
	BSS	1.06±0.27	1.12±0.21	1.27±0.15	0.030	<0.001	<0.001
	P Value‡	0.182	0.586	0.749			
Metamorphopsia	Total	216.38±39.88	198.29±36.97	158.50±24.55	<0.001	<0.001	<0.001
	AIR	208.52±40.60	190.58±34.85	158.05±27.70	<0.001	<0.001	<0.001
	BSS	224.37±37.82	206.00±37.92	158.94±21.18	0.002	<0.001	<0.001
	P Value‡	0.092	0.086	0.883			

BSS-balanced salt solution, BCVA-best corrected visual acuity, IOP-intraocular pressure, CMT-central macular thickness, and CS-contrast sensitivity. B-baseline, M1-month 1, M6-month 6. Values are presented as mean±standard deviation. †p values derived from paired sample t-test. ‡p values derived from independent t-test. p<0.05 was considered statistically significant.

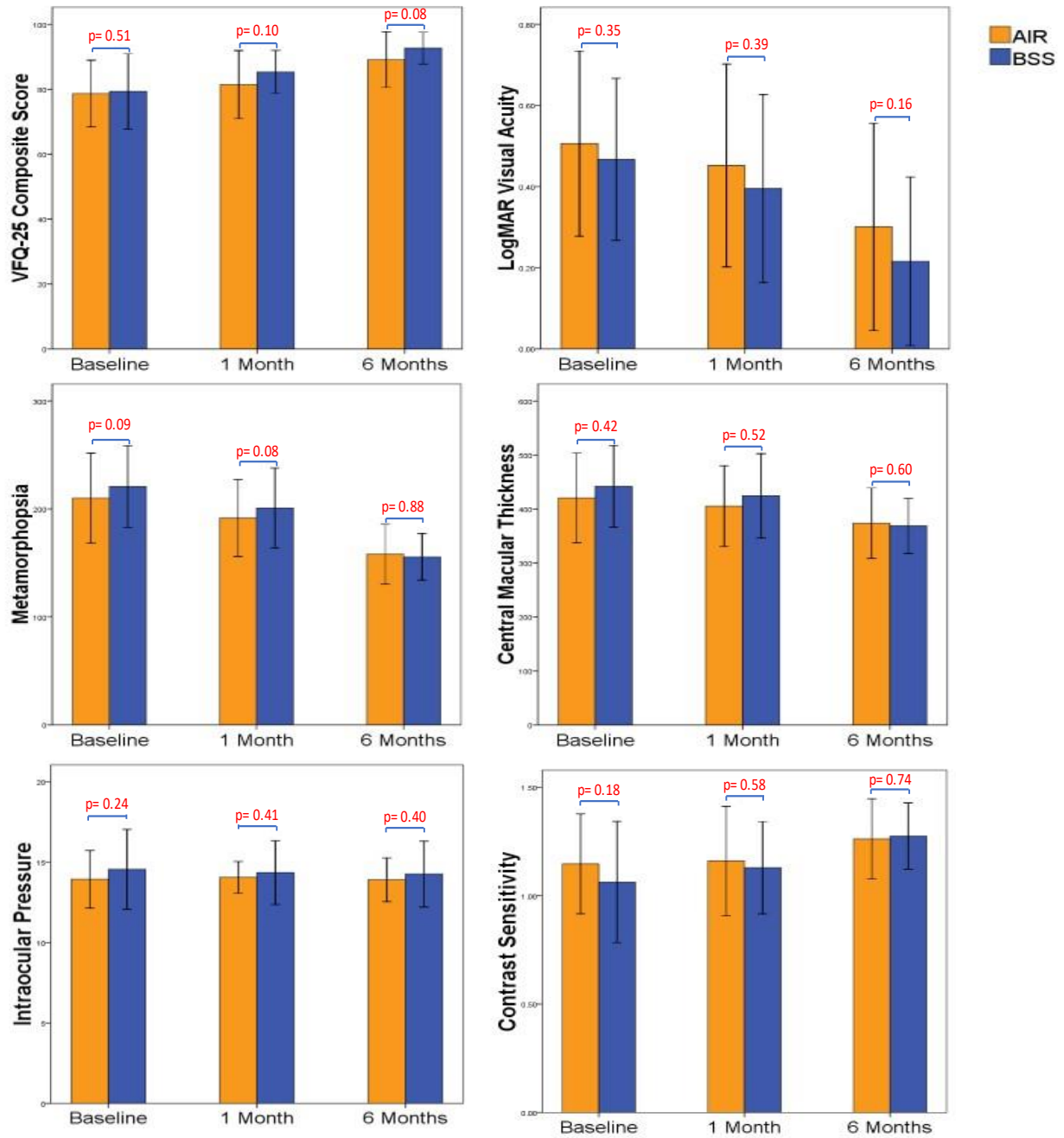


Figure 6. Changes in the mean values in different parameters over 6 months in air and BSS groups. VFQ-visual function questionnaire, BSS-balanced salt solution. $p < 0.05$ was considered statistically significant.

Vitrectomy has improved significantly BCVA between baseline and 1 month (from 0.47 ± 0.19 to 0.42 ± 0.21 , $p < 0.001$), 1 month and 6 months (from 0.42 ± 0.21 to 0.26 ± 0.21 , $p < 0.001$), and baseline and 6 months respectively (from 0.47 ± 0.19 to 0.26 ± 0.21 , $p < 0.001$). In the Air group, BCVA has improved from 0.50 ± 0.20 in baseline, 0.44 ± 0.22 after 1 month ($p = 0.001$), and 0.30 ± 0.22 after 6 months ($p < 0.001$), whereas in the BSS group from 0.45 ± 0.18 baseline, 0.39 ± 0.20 after 1 month ($p = 0.032$) and 0.23 ± 0.18 after 6 months ($p < 0.001$) (Figure 7). BCVA has increased by more than 0.1 logMAR unit in 71 (79%) of 90 patients after 1 month and 83 (91%) of 90 patients after 6 months. Despite the improvement of BCVA at each time point, no significant difference between the two groups after 1 and 6 months has been found.

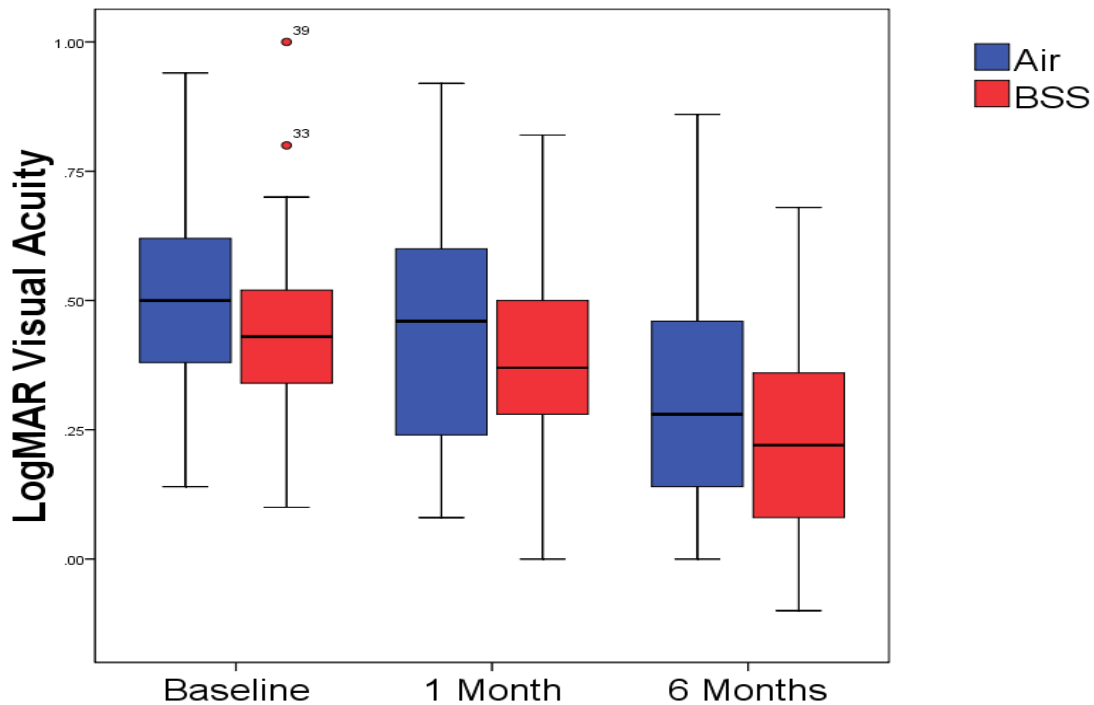


Figure 7. Changes in Visual Acuity over 6 Months.

The preoperative mean of the IOP was 14.25 ± 2.17 , after 1 month 14.20 ± 1.56 , and after 6 months follow-up was 14.08 ± 1.73 (Figure 7). The IOP has not been significantly different between the three-time points in the 2 groups as well as between the two groups.

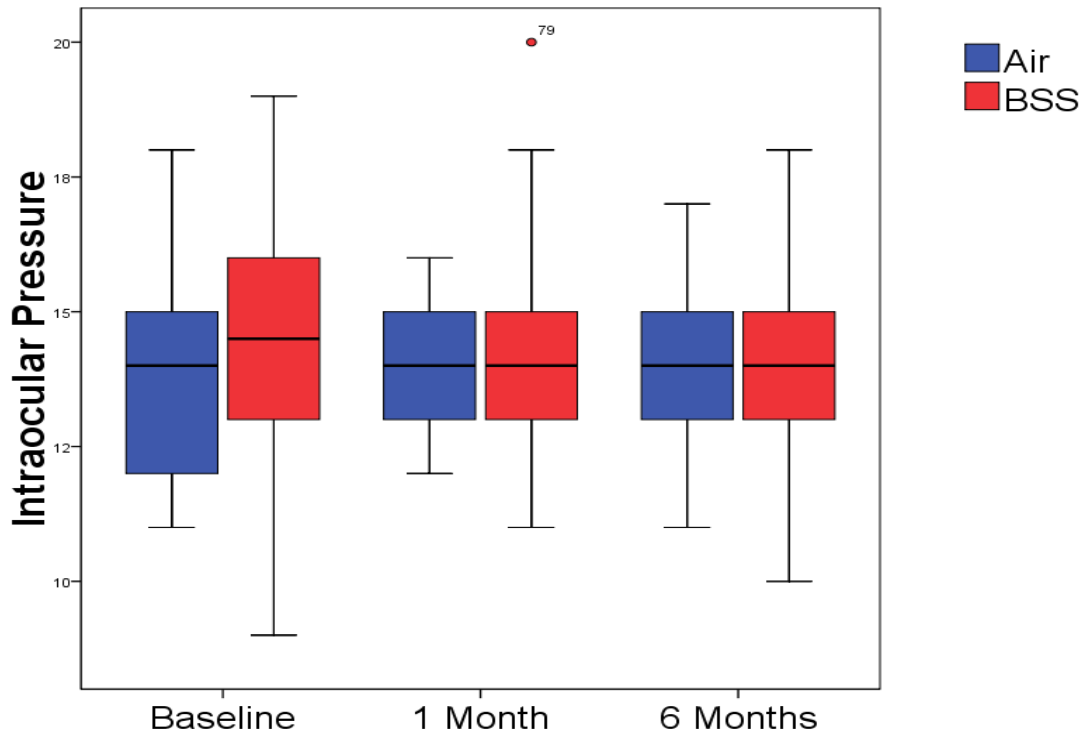


Figure 7. Changes in Intraocular Pressure over 6 Months.

CMT measurements after 6 months of follow-up have shown significant thinning ($p < 0.001$). In the air group, CMT has changed from 425.73 ± 82.99 at baseline to 408.20 ± 76.83 after 1 month ($p = 0.001$) and 374.20 ± 64.87 after 6 months ($p < 0.001$), whereas in the BSS group from 441.70 ± 78.43 at baseline to 420.08 ± 76.10 after 1 month ($p = 0.043$), and 366.73 ± 52.64 after 6 months ($p < 0.001$) (Figure 8).

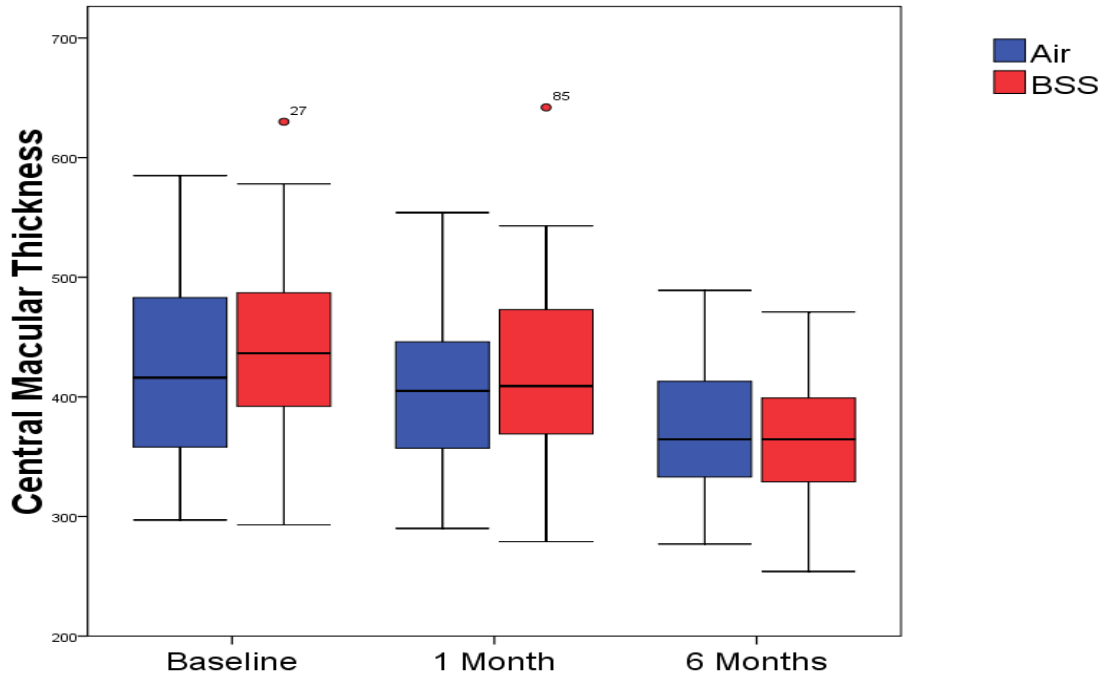


Figure 8. Changes in Central Macular Thickness over 6 Months.

The contrast sensitivity has increased from 1.10 ± 0.25 at baseline to 1.14 ± 0.23 after 1 month and 1.26 ± 0.16 after 6 months. Despite increasing the CS values after 1 month, we did not reach statistical significance ($p=0.056$), but after 6 months there has been a statistically significant improvement ($p<0.001$). The air group in comparison with the BSS group, did not also reach statistical significance ($p=0.609$) after 1 month, but after 6 months both groups had significant improvement (Figure 9). We have not reached statistical differences between the two groups.

The number of distorted squares in metamorphopsia has significantly decreased from 216.38 ± 39.88 at the baseline to 198.29 ± 36.97 after 1 month ($p<0.001$) and 158.50 ± 24.55 after 6 months ($p<0.001$), but no statistical difference has been observed between two groups. In both groups, there was a significant improvement in metamorphopsia over 6 months (Figure 10).

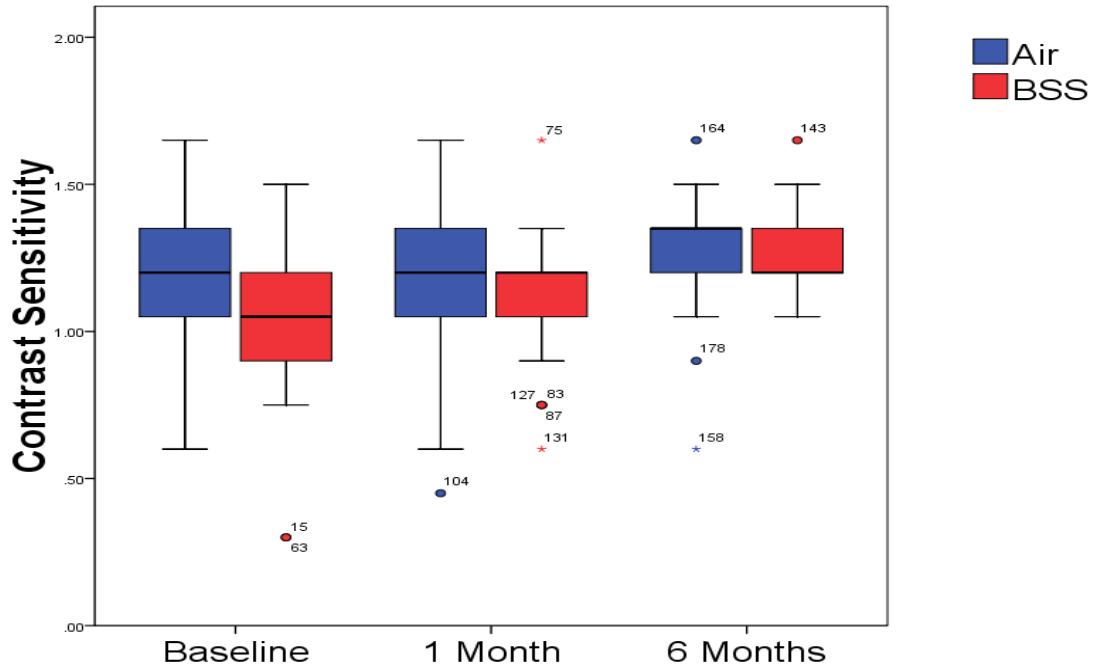


Figure 9. Changes in Contrast Sensitivity over 6 Months.

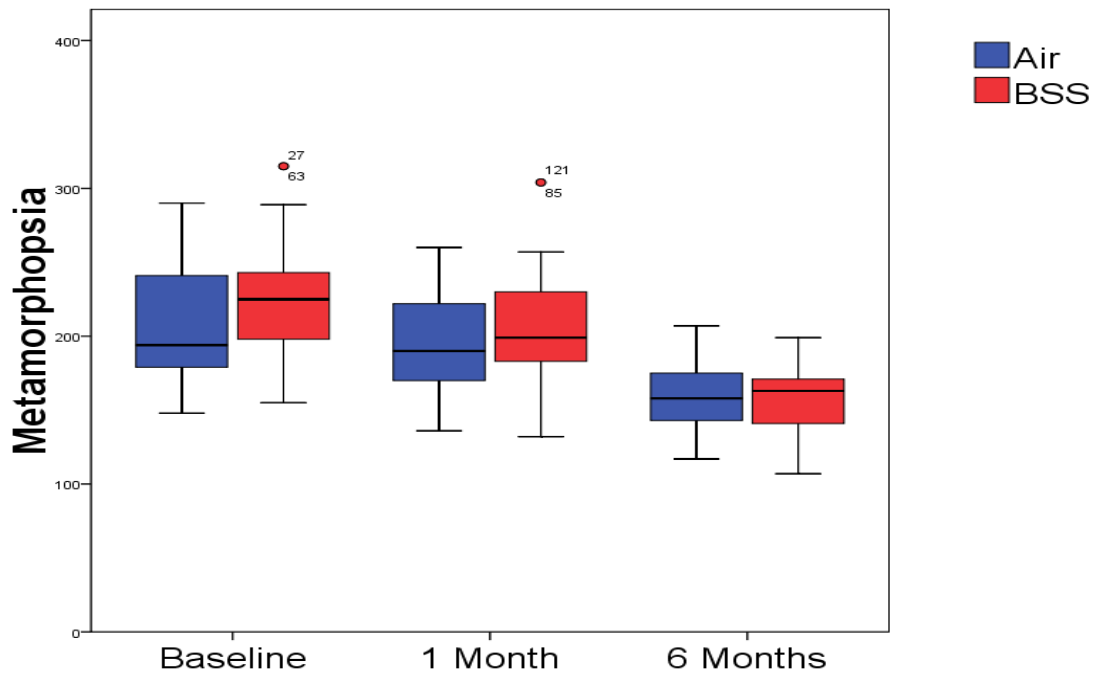


Figure 10. Changes in Metamorphopsia over 6 Months.

VFQ-15 questionnaire results, before and after surgery, are presented in Table 5. VFQ-25 composite score has increased from 80.85 ± 10.96 at baseline to 85.34 ± 8.88 after 1 month ($p=0.001$) and 92.17 ± 6.57 after 6 months ($p<0.001$). In the air group, we did not reach a statistical difference in the VFQ-25 composite score after 1 month ($p=0.087$), but after 6 months there was a statistical difference ($p<0.001$), whereas in the BSS group even after 1 month ($p=0.002$) or 6 months ($p<0.001$), there has been a statistically significant improvement of the score (Figure 11). In the air group, subscales that have not significantly improved after 1 month have been general health ($p=0.064$), ocular pain ($p=0.576$), distance activities ($p=0.066$), social functioning ($p=0.619$), mental health ($p=0.178$), role difficulties ($p=0.122$), dependency ($p=0.278$), driving ($p=0.058$), color vision ($p=0.144$), and peripheral vision ($p=0.535$), whereas after 6 months general health ($p=0.058$), ocular pain ($p=0.066$), social functioning ($p=0.058$), role difficulties ($p=0.052$), dependency ($p=0.669$), driving ($p=0.064$), and color vision ($p=0.498$). In the BSS group, these subscales after 1 month have not reached significant improvement in general health ($p=0.205$), ocular pain ($p=0.632$), near activities ($p=0.078$), social functioning ($p=0.201$), mental health ($p=0.052$), role difficulties ($p=0.062$), and peripheral vision ($p=0.282$), whereas after 6 months general health ($p=0.053$), social functioning ($p=0.199$), and peripheral vision ($p=0.067$) (Figure 11). Patients' quality of life has been improved regardless of the type of tamponade used during surgery, but we did not reach a statistically significant difference between the 2 groups at each time point (Figure 6).

Table 5. Summary of VFQ-25 composite score and 12 sub-categories scores at baseline, 1 month, and 6 months after surgery in air and BSS group.

Parameters	Time Point				P Value†		
		Baseline (mean±SD)	Month 1 (mean±SD)	Month 6 (mean±SD)	B vs M1	M1 vs M6	B vs M6
General health	Total	55.51±19.24	63.23±15.85	68.75±21.75	0.002	0.013	0.012
	AIR	49.26±16.83	60.29±13.92	64.70±21.42	0.064	0.136	0.058
	BSS	61.76±19.69	66.17±17.27	72.79±21.64	0.205	0.058	0.053
	P value‡	0.052	0.059	0.119			
General vision	Total	53.45±17.10	65.44±15.00	78.67±14.34	<0.001	<0.001	<0.001
	AIR	50.70±15.66	65.00±16.00	78.23±13.36	0.003	<0.001	<0.001
	BSS	56.20±17.88	65.88±14.16	79.11±15.44	0.008	0.002	<0.001
	P value‡	0.168	0.127	0.126			
Ocular pain	Total	88.41±18.10	87.04±15.66	96.69±7.36	0.460	<0.001	<0.001
	AIR	70.46±18.70	78.67±16.56	87.49±14.10	0.576	0.002	0.066
	BSS	87.86±18.07	86.76±15.36	97.05±6.19	0.632	<0.001	0.003
	P value‡	0.804	0.886	0.684			
Near activities	Total	73.28±19.65	80.14±16.48	89.88±11.48	0.001	<0.001	<0.001
	AIR	66.49±18.41	74.69±16.50	87.80±13.99	0.005	<0.001	<0.001
	BSS	76.10±20.44	81.61±16.51	92.27±7.54	0.078	<0.001	<0.001
	P value‡	0.240	0.466	0.086			
Distance activities	Total	74.62±20.74	81.00±15.89	89.15±11.83	0.002	<0.001	<0.001
	AIR	72.79±23.05	79.16±17.31	87.37±12.75	0.066	0.002	<0.001
	BSS	76.46±18.31	82.84±14.35	90.93±10.73	0.006	0.001	<0.001
	P value‡	0.469	0.344	0.218			
Social functioning	Total	93.93±11.32	95.40±10.10	97.79±6.45	0.261	0.068	0.013
	AIR	93.75±10.77	94.85±9.78	98.52±5.11	0.619	0.016	0.058
	BSS	94.11±12.01	95.95±10.53	97.05±7.57	0.201	0.609	0.199
	P value‡	0.895	0.656	0.352			
Mental health	Total	76.65±20.84	82.87±15.53	91.26±10.42	0.009	<0.001	<0.001
	AIR	77.02±19.74	81.18±17.77	88.78±12.66	0.178	0.001	0.002
	BSS	76.28±22.17	84.55±12.98	93.75±6.88	0.052	<0.001	<0.001
	P value‡	0.886	0.375	0.049			
Role difficulties	Total	77.75±23.74	84.19±18.14	89.52±17.08	0.012	0.001	<0.001
	AIR	76.10±23.71	81.98±21.80	86.39±20.72	0.122	0.083	0.052
	BSS	79.41±24.01	86.39±13.54	92.64±11.96	0.062	0.004	0.003
	P value‡	0.569	0.320	0.133			
Dependency	Total	91.68±14.47	92.64±14.21	95.21±10.00	0.655	0.034	0.074
	AIR	92.20±14.92	88.47±17.88	93.38±11.92	0.278	0.014	0.669
	BSS	91.17±14.20	96.81±7.40	97.05±7.36	0.024	0.856	0.041
	P value‡	0.772	0.015	0.132			
Driving	Total	66.12±25.04	79.43±18.12	90.94±13.31	<0.001	0.001	<0.001
	AIR	53.84±24.14	69.23±17.39	86.36±17.18	0.058	0.054	0.064
	BSS	75.00±22.27	86.80±15.14	93.75±9.82	0.005	0.004	<0.001
	P value‡	0.018	0.006	0.151			
Color vision	Total	96.54±10.12	97.66±10.03	99.76±5.34	0.433	0.098	0.074
	AIR	99.45±5.00	96.09±12.50	98.00±6.22	0.144	0.165	0.498
	BSS	93.00±13.54	99.89±6.04	100.67±7.45	0.021	0.476	0.019
	P value‡	0.047	0.148	0.156			

Peripheral vision	Total	88.23±20.47	90.80±15.51	95.58±9.60	0.221	0.004	0.003
	AIR	87.50±18.71	88.97±16.50	94.85±10.26	0.535	0.003	0.010
	BSS	88.97±22.35	92.64±14.47	96.32±8.98	0.282	0.169	0.067
	P value‡	0.770	0.332	0.532			
Composite score	Total	80.85±10.96	85.34±8.88	92.17±6.57	0.001	<0.001	<0.001
	AIR	79.97±10.42	83.60±10.24	90.79±7.83	0.087	<0.001	<0.001
	BSS	81.73±11.57	87.08±7.00	93.55±4.75	0.002	<0.001	<0.001
	P value‡	0.514	0.107	0.083			

B-baseline, M1-month 1, M6-month 6. Values are presented as mean±standard deviation. †p values derived from paired sample t-test. ‡p values derived from independent t-test. p<0.05 was considered statistically significant.

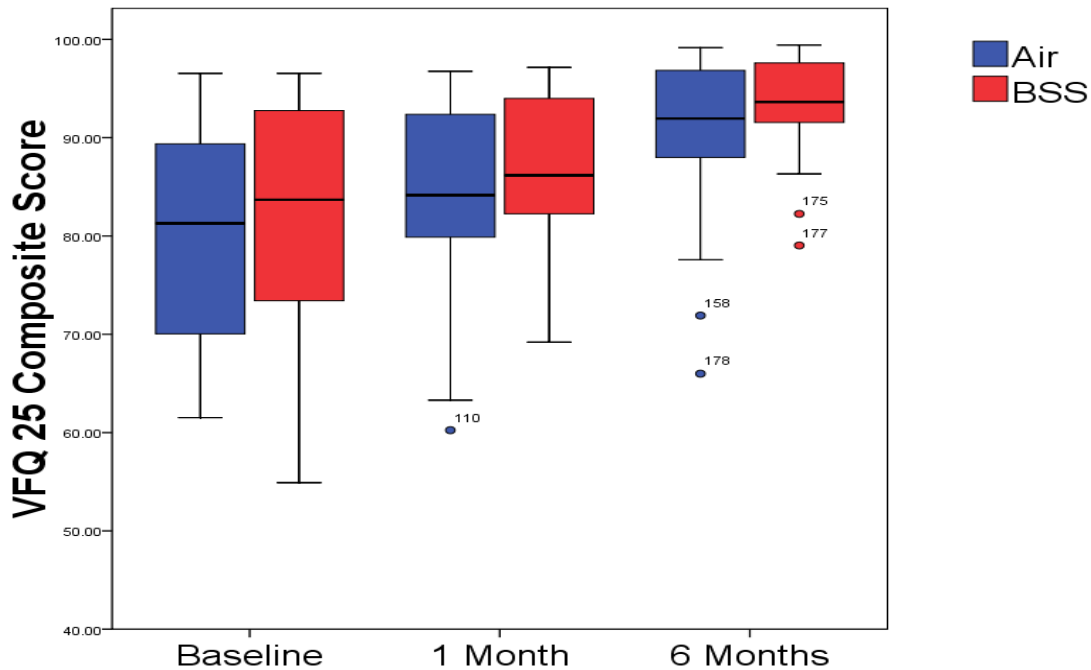


Figure 11. Changes in Questionnaire Composite Score over 6 Months.

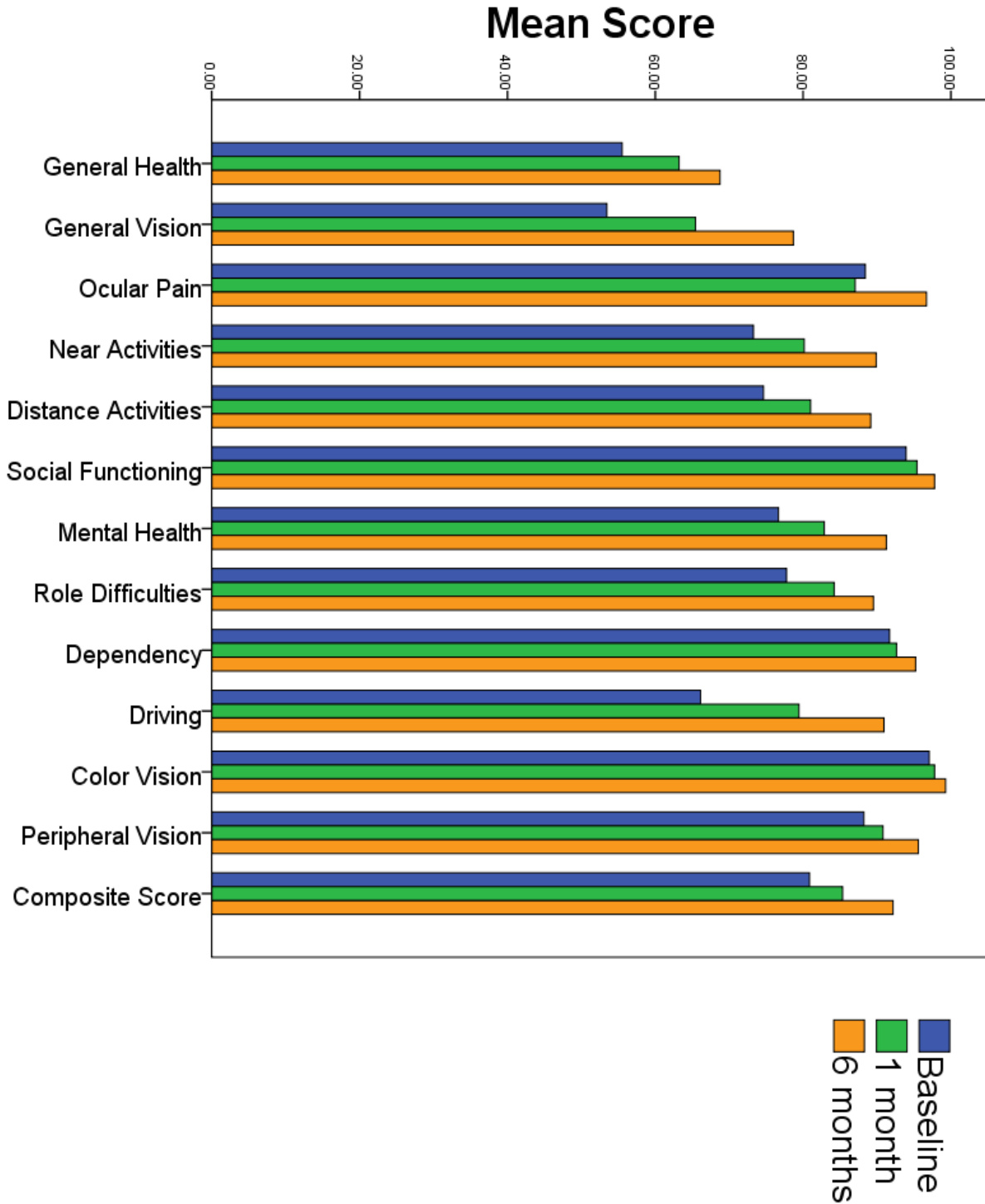


Figure 12. Evolution of the mean values of each sub-category and the composite score of the NEI VFQ-25 preoperatively (baseline), 1-month, and 6-months postoperatively.

Vitrectomy also improved binocular BCVA and CS. At baseline, binocular BCVA was 0.13 ± 0.17 , after 1 month improved at 0.12 ± 0.16 ($p=0.134$), and after 6 months 0.04 ± 0.17 ($p<0.001$) (Figure 13).

Binocular CS at baseline was 1.33 ± 0.18 , after 1 month it improved to 1.35 ± 0.15 ($p=0.203$), and after 6 months 1.40 ± 0.14 ($p<0.001$) (Figure 14).

In both groups, there were improvements in binocular BCVA and CS, but we did not reach a significant difference at each time point (Table 6).

Table 6. Summary of parameters of the Binocular BCVA and CS over 6 months.

Parameters		Time Point			P Value†		
		Baseline (mean±SD)	Month 1 (mean±SD)	Month 6 (mean±SD)	B vs M1	M1 vs M6	B vs M6
Binocular BCVA	Total	0.13±0.17	0.12±0.16	0.04±0.17	0.134	<0.001	<0.001
	AIR	0.09±0.15	0.08±0.14	0.01±0.15	0.450	<0.001	<0.001
	BSS	0.18±0.18	0.16±0.17	0.07±0.18	0.131	0.003	0.002
	P Value‡	0.296	0.213	0.689			
Binocular CS	Total	1.33±0.18	1.35±0.15	1.40±0.14	0.203	<0.001	<0.001
	AIR	1.36±0.12	1.36±0.12	1.40±0.12	0.326	<0.001	0.001
	BSS	1.31±0.22	1.34±0.17	1.39±0.16	0.415	0.006	0.016
	P Value‡	0.262	0.708	0.930			

BSS-balanced salt solution, BCVA-best corrected visual acuity, and CS-contrast sensitivity. B-baseline, M1-month 1, M6-month 6. Values are presented as mean±standard deviation. †p values derived from paired sample t-test. ‡p values derived from independent t-test. $p<0.05$ was considered statistically significant.

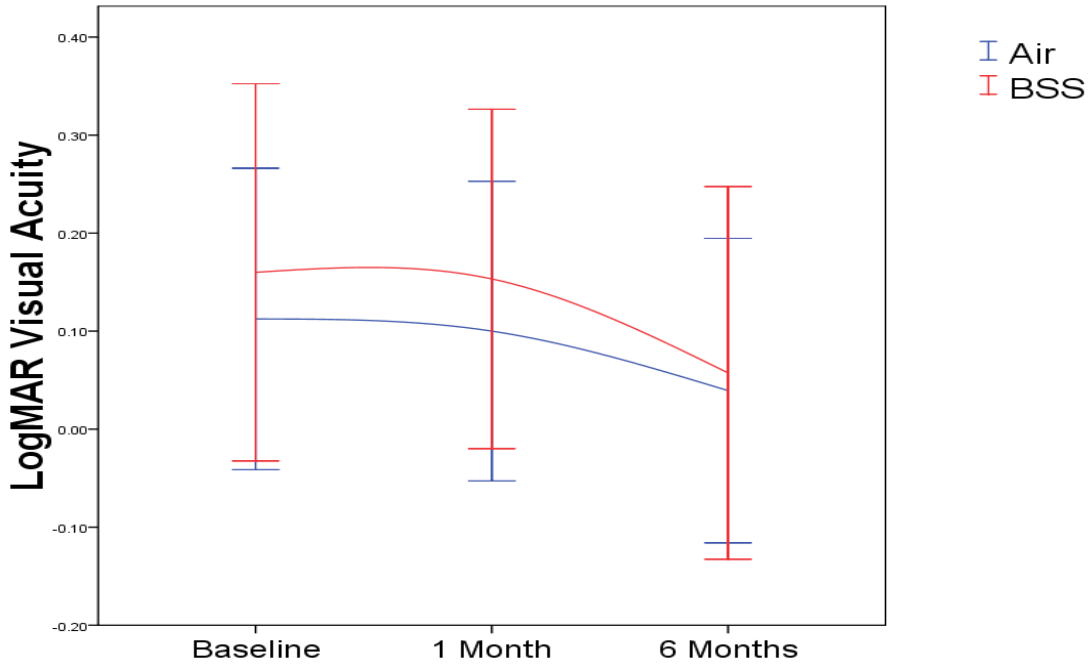


Figure 13. Changes in Binocular Visual Acuity over 6 Months.

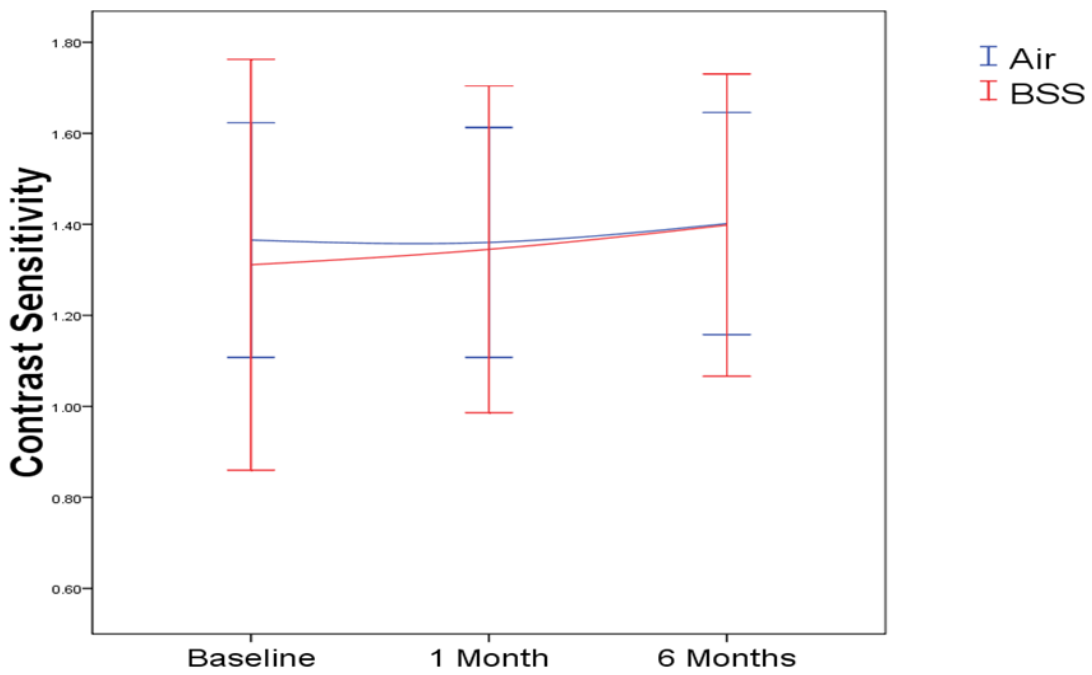


Figure 14. Changes in Binocular Contrast Sensitivity over 6 Months.

QCS in each time point has not been related to other factors such as age, sex, PVD, lens status, hypertension, diabetes, or visual acuity whether we used air or BSS as a tamponade during surgery (Table 7).

Table 7. Parameters affecting QCS in each time point through multiple regression analysis.

Variables		OR (95% CI)	P value
QCS*	Baseline	1.008 (0.962 – 1.055)	0.745
	1 Month	1.043 (0.983 – 1.107)	0.167
	6 Months	1.071 (0.981 – 1.170)	0.125
QCS**	Baseline	0.995 (0.947 – 1.045)	0.835
	1 Month	1.030 (0.968 – 1.097)	0.348
	6 Months	1.064 (0.971 – 1.166)	0.182
QCS***	Baseline	0.995 (0.944 – 1.048)	0.841
	1 Month	1.038 (0.973 – 1.109)	0.259
	6 Months	1.058 (.958 – 1.168)	0.263

QCS-questionnaire composite score, OR-odds ratio, CI-confident interval. * QS, age, sex, ** QS, age, sex, PVD, lens status, *** QS, age, sex, PVD, lens status, HTA, diabetes, VA. p<0.05 was considered statistically significant.

6. DISCUSSION

The present study aimed to assess the impact of vitrectomy on VR-QoL and visual functions in patients who underwent the procedure following IEM. The evaluation of VR-QoL using a standardized questionnaire revealed significant improvements in various domains after vitrectomy. Patients reported enhanced satisfaction with their visual function, reduced visual disturbances, and improved psychological well-being. The observed improvements in vision-related quality of life and visual functions can be attributed to the successful removal of the epiretinal membrane during vitrectomy. By eliminating the tractional forces exerted on the macula, the surgery aims to restore retinal anatomy and optimize visual function. Our findings support the effectiveness of vitrectomy as a viable treatment option for patients with IEM, highlighting its potential for positively impacting patients' lives. Visual function assessments, including visual acuity, contrast sensitivity, and metamorphopsia, demonstrated substantial postoperative enhancements in these parameters.

In this study, we have evaluated the usage of Air tamponade and BSS tamponade after PPV surgery in patients with IEM. We have discovered that parameters such as BCVA, CMT, CS, Metamorphopsia, and VR-QoL composite score have improved gradually in both groups throughout the 6 months after surgery, except IOP. Despite improvements in the observed parameters, there has been no significant difference between the two groups. In the past, four studies have compared the use of Air and BSS tamponade during PPV surgery (130-133). One study compared the foveal contour characteristics and BCVA between the two groups after IEM surgery (130). Another study has compared BCVA between two groups after PPV in patients with lamellar macular hole (131). The third study compared intraretinal and subretinal changes, BCVA, and CMT between two groups after IEM surgery (132). The fourth study compared BCVA, CMT, and RNFL thickness between two groups after IEM surgery (133). To our knowledge, this is the first study that compares VRQoL between two groups after IEM surgery.

Our study included a cohort of patients who underwent vitrectomy for the treatment of IEM. Preoperative and postoperative visual acuity measurements were obtained to assess the impact of the surgery on visual function. The results revealed a significant improvement in BCVA following vitrectomy, indicating the efficacy of the surgical intervention in restoring visual clarity.

Previous studies have provided evidence that BCVA can continue to improve for a duration of 1 month to 2.4 years after the removal of the IEM. These studies have reported that a greater BCVA

compared to the preoperative baseline was achieved in varying proportions of eyes during different time intervals following EM removal. Specifically, improvements in BCVA were observed in 43% of eyes during the 6 to 12-month period, 54% of eyes within 1 to 2 years, and 60% of eyes within 2 to 3 years after EM removal (134,135). In our study, BCVA has increased by more than 0.1 logMAR unit in 71 (79%) of 90 patients after 1 month and 83 (91%) of 90 patients after 6 months. This is in contrast to earlier findings that two logMAR units could increase VA by up to 45% (136). The development of cataract may be associated with the failure of VA improvement, but to minimize the potential impact on postoperative visual acuity, our study specifically included patients with mild cataract. By selecting patients with mild cataract, we aimed to reduce the confounding effect that more advanced cataract could have on visual acuity outcomes following vitrectomy for an idiopathic epiretinal membrane. Our patients' BCVA results at baseline have been within the normal range of other studies (137). Even though after 1 month there have been slightly better results in the BSS group, there has been no statistical difference. This difference in visual acuity between the two groups, particularly at the 1-month postoperative evaluation, can potentially be attributed to the temporary nature of air tamponade. Typically, air tamponade in the vitreous cavity dissipates within a duration of less than 1 month (133). Leitritz et al (130) have reported an improvement in BCVA after 3 months in both groups, but they have not reached a difference between the two groups. Kyuhwan et al (133) have also concluded that they have not found any significant difference in BCVA between the two groups in 2 years of follow-up after the removal of the epiretinal membrane. By analyzing from a professional point of view, we should expect worse vision in the air group immediately after surgery compared with the BSS group. Nevertheless, our findings regarding the use of air tamponade revealed comparable visual acuity outcomes between the two groups at the 1-month postoperative mark. Additionally, throughout the 6-months follow-up period, no statistically significant disparity in visual acuity was observed between the two groups.

In addition to the improvement observed in monocular BCVA, our study also demonstrated a positive impact of the vitrectomy on binocular BCVA. According to the study conducted by Khanna et al., the results demonstrated a significant improvement in distance binocular BCVA following vitrectomy (138). Based on our data analysis, the results indicate that there was no significant improvement in binocular BCVA after one month of intervention in both the air tamponade group ($p=0.450$) and the BSS tamponade group ($p=0.131$). However, after a period of

six months, a notable improvement in binocular BCVA was observed in both groups, with statistically significant results found for the air tamponade group ($p < 0.001$) and the BSS tamponade group ($p = 0.002$). Despite these observed improvements in binocular BCVA, no statistically significant difference was found between the two groups. This implies that the choice of tamponade (air or BSS) did not significantly impact the overall improvement in binocular BCVA. However, it is important to note that even without a statistically significant difference between the groups, the observed improvements in binocular BCVA indicate a positive response to the intervention in both treatment arms.

Some studies suggested a potential association between the development and progression of open-angle glaucoma (OAG) in patients who underwent vitrectomy. They found that the mean IOP in the operated eyes increased significantly compared to the fellow eyes, particularly in cases where the patient had a pseudophakic or aphakic eye. They also postulated that the incidence of OAG following vitrectomy could potentially increase to a range of 15-20%. They proposed that the underlying pathogenesis of this association could be attributed to the elevated partial pressure of oxygen in the vitreous cavity after vitrectomy, leading to oxidative stress on the trabecular meshwork in the anterior chamber. This effect may be particularly pronounced in cases where the patient does not have a crystalline lens (139,140). During the 6-month assessment period, we observed changes in IOP both before and after the vitrectomy. Throughout the assessment period, we closely monitored and measured the preoperative and postoperative IOP levels to evaluate any variations or trends. While there were changes in IOP values throughout the study, indicating the potential impact of the surgical intervention on IOP, these changes did not reach a level of statistical significance pre and postoperatively as well as when comparing the two groups. Jang et al. evaluated IOP over 2 years period. They concluded that after 2 years IOP will be significantly lower in the BSS group than air group. In the study conducted by Jang et al., the researchers conducted an evaluation of IOP over a period of 2 years. Their findings led them to conclude that after 2 years, the IOP in the BSS group was significantly lower compared to the air group (133).

Multiple studies have consistently reported that the CMT decreases in the months following vitrectomy but tends to stabilize thereafter (129,134,141). In our study, we examined the impact of vitrectomy on CMT, a crucial parameter used to evaluate the status of the macula. Preoperative CMT measurements in patients with idiopathic EM often demonstrate an increase due to the

presence of the membrane and associated edema. Therefore, one of the primary objectives of vitrectomy is to reduce CMT by removing the EM and relieving traction on the macula. After 6 months, a noteworthy decrease in CMT was observed in both groups. Although there was a tendency for a greater reduction in CMT in the air group after one month, this difference did not reach statistical significance. However, it is worth noting that the compressive mechanism associated with air tamponade may have contributed to this observed difference (133). Interestingly, after the 6-month mark, a significant improvement in CMT was observed in both groups ($p < 0.001$). These results align with previous research indicating that vitrectomy alone, regardless of the type of tamponade used, leads to a significant decrease in CMT over time. The initial trend towards a greater reduction in CMT in the air group could be attributed to the compressive effect of air tamponade, exerting pressure on the macula and facilitating the resolution of edema. However, as time progresses, it appears that other factors, independent of tamponade contact, contribute to the ongoing reduction in CMT. Although there was an improvement in the results, our study did not find a significant difference between the groups in terms of CMT thickness.

Previous studies have investigated the impact of surgery on visual functions in patients with IEM. In addition to other visual functions, we also focused on evaluating contrast sensitivity in our study. Contrast sensitivity is a measure of the ability to detect differences in shades of gray or distinguish objects with similar tones. It provides important information about the visual system's ability to perceive subtle differences in contrast, which is essential for activities such as reading, driving, and recognizing objects in different lighting conditions. Our findings revealed that contrast sensitivity showed improvement after surgery for EM. These results align with previous studies that have reported positive outcomes in visual function following surgical intervention (142-144). Our study examined the changes in CS following a 6-month observation period after surgery for IEM. The results demonstrated a significant improvement in CS during this timeframe. At the 1-month mark, we observed that the air group did not show a significant improvement in CS compared to the BSS group ($p = 0.609$). However, the BSS group exhibited a statistically significant improvement in CS at this time point ($p = 0.03$). This discrepancy suggests that the use of air tamponade may not have an immediate positive impact on CS, unlike the BSS group. Otherwise, after the 6-month follow-up, both the air group and the BSS group showed a significant improvement in CS ($p < 0.001$). This finding indicates that over a longer period, both tamponade

options led to positive outcomes in terms of CS improvement. The sustained improvement in CS observed in both groups suggests that the visual system continues to adapt and recover postoperatively. Despite the observed improvements in CS, our study did not identify a significant difference between the air and BSS groups at both the 1-month and 6-month time points following surgery. This implies that in terms of CS improvement, both tamponade options yield comparable results within the studied timeframe.

In our study, we not only observed improvements in monocular CS following vitrectomy, but we also found a positive impact on binocular CS. Binocular CS refers to the ability to perceive and discriminate contrasts in visual stimuli when both eyes are working together. According to the study conducted by Dormegny et al., the findings revealed a noteworthy improvement in distance binocular CS after vitrectomy (145). The results of their investigation indicated a significant enhancement in distance binocular BCVA following the surgical procedure. According to our data analysis, the findings suggest that there was no significant improvement in binocular CS after one month of intervention in both the air tamponade group ($p=0.326$) and the BSS tamponade group ($p=0.415$). However, a noteworthy improvement in binocular BCVA was observed after six months in both groups. After six months, statistical significance was found for the air tamponade group ($p=0.001$) and the BSS tamponade group ($p=0.016$), indicating a significant improvement in binocular BCVA compared to baseline measurements. Despite the observed improvements in binocular CS, our study did not reveal a statistically significant difference between the two groups.

Metamorphopsia is recognized as one of the significant symptoms associated with IEM. Various studies have demonstrated a reduction in metamorphopsia using different assessment tools, including the Amsler chart (136,146), M-Charts (147), sine Amsler charts (2), and scanning laser ophthalmoscopy (148). In our study, the baseline mean value of metamorphopsia was recorded as 215.38 ± 39.69 . This value differs from the findings reported in the other two studies (136,146), which measured metamorphopsia by counting the number of distorted squares on the Amsler chart. The discrepancy in these results could be attributed to several factors, such as the stage of IEM before surgery or the subjective nature of patient satisfaction when interpreting the results of the Amsler chart knowing that the Amsler chart is a subjective tool that relies on patients' self-reporting of visual distortion and individual interpretation and perception of visual abnormalities can vary, leading to variations in the reported number of distorted squares. The severity of

metamorphopsia can vary among individuals with IEM, and factors such as the duration of the condition and the extent of retinal distortion may contribute to the differences observed in baseline metamorphopsia values. After one month of observation, we observed a significant improvement in metamorphopsia in both the air tamponade group ($p < 0.001$) and the BSS tamponade group ($p = 0.002$). This improvement suggests that the surgical intervention had a positive impact on reducing visual distortion in patients with IEM. Furthermore, after six months, patients in both groups reported satisfaction with a decrease in metamorphopsia, indicating a sustained and significant improvement ($p < 0.001$). The significant improvement in metamorphopsia after one month and its sustained improvement at the six-month mark indicate the long-term benefits of vitrectomy for patients with IEM. By addressing the underlying epiretinal membrane and restoring retinal architecture, surgical intervention can effectively alleviate the visual distortion experienced by patients. Overall, the results of this study indicate an improvement in metamorphopsia after one and six months from the baseline measurement. However, it is important to note that no statistically significant difference was found between the two groups, both at the one-month and six-month follow-up assessments after surgery. The lack of a significant difference between the air tamponade group and the BSS tamponade group suggests that the choice of tamponade may not significantly influence the outcomes in terms of reducing metamorphopsia.

The impact of IEM on the quality of life can be substantial, as visual disturbances and functional limitations associated with the condition can significantly affect daily activities and overall well-being. However, the positive effects of vitrectomy on quality of life outcomes have been well-documented in the literature. Various studies have consistently reported that vitrectomy in patients with IEM leads to improvements in the quality of life (136,146,147,149,150,151). These improvements are reflected in the composite scores as well as in most of the subscales assessed after surgery. Studies evaluating the quality of life outcomes in patients with IEM have utilized various standardized assessment tools, such as the National Eye Institute Visual Function Questionnaire (NEI-VFQ-25) (3), the 36-Item Short-Form Health Survey questionnaires (SF-36) (152), or disease-specific questionnaires. These tools encompass multiple domains, including visual function, visual symptoms, general health, mental health, and social functioning. Previous studies have indeed examined the impact of vitrectomy on VRQoL in patients with IEM at various time points ranging from 3 months up to 2 years. However, to the best of our knowledge, there is a paucity of research specifically comparing VRQoL outcomes between two groups based on the

choice of intraocular tamponade following IEM surgery. Therefore, this study aimed to address this gap in the literature by evaluating and comparing VRQoL between two groups utilizing different intraocular tamponades after IEM surgery.

In the present study, we assessed the impact of vitrectomy on VRQoL in patients with IEM at various time points. The results revealed a significant improvement in VRQoL scores throughout the study period. At baseline, the mean VRQoL composite score was 80.85 ± 10.96 , indicating the initial level of impairment in patients' quality of life due to IEM. However, after 1 month of observation, a notable improvement was observed, with the VRQoL composite score increasing to 85.34 ± 8.88 . This improvement further continued at the 6-month mark, where the VRQoL composite score reached 92.17 ± 6.57 . When analyzing the individual tamponade groups, interesting patterns emerged. In the air tamponade group, there was no significant improvement in VRQoL after 1 month. However, a significant improvement was observed after 6 months, suggesting a delayed but positive impact on patients' quality of life. On the other hand, the BSS tamponade group showed significant improvements in VRQoL at both 1 and 6 months after surgery, indicating an early and sustained enhancement in quality of life outcomes. In this study, the baseline composite scores of VRQoL differed from those reported in previous studies, such as Ghazi-Nouri et al. (78.4), Matsuoka et al. (73), Okamoto et al. (66.2), Nakashizuka et al. (75.3), and Khanna et al. (84.8). These variations in baseline scores may arise from several factors, including cultural and linguistic variations, as well as the context in which the questionnaire was administered. The VFQ-25 questionnaire, widely used to assess VRQoL, requires translation and adaptation to different languages and cultural settings. These translation processes, although rigorous, can introduce variations in the interpretation and understanding of the questionnaire items. The observed improvement in the composite score of VRQoL after 6 months in our study aligns with findings reported in the existing literature. Although our study demonstrated improvements in the composite score of VRQoL at both 1 and 6 months after surgery, it is important to note that no statistically significant difference was observed between the two groups. Previous studies have consistently reported improvements in various subscales of VRQoL following vitrectomy for the IEM. These improvements have been observed at different time points ranging from 3 months to 2 years post-surgery. Among the subscales, "general vision," "distance activities," "near activities," and "role difficulties" have consistently shown the greatest improvements. In our study, we evaluated the impact of vitrectomy on the VRQoL subscales and

found notable improvements. At 1 month postoperatively, seven out of the twelve subscales (“general vision”, “general vision”, “near activities”, “distance activities”, “mental health”, “role difficulties”, and “driving”) demonstrated statistically significant improvements. These findings suggest that vitrectomy positively influenced these aspects of VRQoL in the early postoperative period. However, after 6 months of follow-up, only two subscales (“dependency” and “color vision”) did not show statistically significant improvements. It is important to note that the lack of significant improvement in these specific subscales does not diminish the overall positive impact of vitrectomy on VRQoL. We observed that in the air tamponade group, there was no significant improvement in several subscales after 1 month compared to the BSS tamponade group. These subscales included “general health”, “ocular pain”, “distance activities”, “social functioning”, “mental health”, “role difficulties”, “dependency”, “driving”, “color vision”, and “peripheral vision”. After 6 months, although there was an overall improvement in VRQoL subscales in both groups, we still did not reach significant improvement in some subscales in the air tamponade group. These subscales included “general health”, “ocular pain”, “social functioning”, “role difficulties”, “dependency”, “driving”, and “color vision”. The lack of significant improvement in these subscales in the air tamponade suggests that the presence of air in the vitreous cavity may have a temporary impact on these aspects of VRQoL (133). The results showed that there was no statistically significant difference between the two groups in almost all subscales, indicating that the choice of tamponade did not have a significant impact on these aspects of VRQoL. However, we did observe a significant difference between the groups in the subscales of dependency and driving after 1 month, as well as in mental health after six months. This suggests that the choice of tamponade may have a potential influence on these specific areas of VRQoL in the short term.

The aim of this study was to investigate the impact of intraocular tamponade choice on the improvement of VRQoL in patients undergoing PPV. Our initial hypothesis proposed that the use of a BSS as an intraocular tamponade would result in a superior improvement of VRQoL compared to the use of air. However, upon careful analysis of the data, our study did not confirm this hypothesis. The findings revealed that our hypothesis was only confirmed at the 1-week mark after surgery. This can be attributed to the duration of the air tamponade within the eye. The temporary presence of air, which typically persists for 7-10 days before being replaced by a liquid, appears to have a notable impact on early visual outcomes. However, as time progressed and the tamponade

transitioned to water, no significant differences were observed between the two groups in 1-month and 6-month follow-up periods.

It is crucial to highlight that while our study did not confirm the initial hypothesis, this does not invalidate the significance of the findings. The similarity in the improvement of VRQoL between the two tamponade groups suggests that both approaches are equally effective in enhancing patients' well-being and visual functioning following pars plana vitrectomy. These results have important implications for clinical practice, as they suggest that the choice of intraocular tamponade may not be a crucial factor in determining the short-term improvement of VRQoL in this particular context.

6.1 Study limitation

Although we randomized all patients and used validated instruments for collecting data, this study has still some limitations. The first factor is the VFQ-25 questionnaire, which should have been answered by patients before and after surgery. They might have wanted to appease the doctor or justify the post-operative discomfort. Consequently, patients may have tended to respond to the questionnaire more favorably following surgery. Although the study design cannot avoid this, there could be a consideration in improving the questionnaire or creating any other questionnaire that might be more specific to the macular syndrome, in this case for patients with EM, knowing that this questionnaire has been validated for patients with ocular hypertension or glaucoma. The second factor is the short post-operative evaluation of only 6 months, realizing that longer time follow-up studies have reported that it takes a minimum 1 year for the macula to recover and in 43% of eyes up to 12 months, in 54% up to 2 years, and 60% up to 3 years visual acuity to restore (151). Despite these limitations, this study's strength is a randomized, cohort design, and it is the first study that prospectively compares VRQoL, BCVA, IOP, CMT, CS, and metamorphopsia between an air tamponade group and BSS tamponade group after surgery in patients with IEM.

7. CONCLUSION

Based on the findings of this study, the following conclusions can be drawn:

1. PPV is an effective procedure for improving visual functions and VRQoL in patients with IEM.
2. There was no significant difference in postoperative VRQoL between the air and BSS tamponade groups. Both tamponade options yielded similar outcomes in terms of VRQoL.
3. There was no significant difference in postoperative BCVA between the air and BSS tamponade groups. Both groups showed improvement in BCVA after surgery.
4. CMT showed significant improvement after surgery in both the air and BSS tamponade groups. However, there was no significant difference in CMT reduction between the two groups.
5. CS improved significantly after surgery in both the air and BSS tamponade groups, with no significant difference observed between the groups.
6. Metamorphopsia, a common symptom of IEM, improved after surgery in both groups, but there was no significant difference between the air and BSS tamponade groups.
7. IOP did not show significant differences between the air and BSS groups at different time points.

In summary, our study demonstrated that both air and BSS tamponade options are effective in improving visual functions and VRQoL in patients with IEM. The choice of tamponade may not have a significant impact on postoperative outcomes in terms of VRQoL, BCVA, CMT, CS, and metamorphopsia. These findings provide valuable insights for clinicians in making informed decisions regarding tamponade selection and highlight the importance of considering other factors in the surgical management of IEM. Further research may be warranted to explore additional variables that could influence postoperative outcomes and optimize patient satisfaction and visual outcomes in IEM surgery.

8. SAŽETAK

Procjena kvalitete života s obzirom na vidnu funkciju u pacijenata nakon vitrektomije izvedene zbog idiopatske epiretinalne membrane

UVOD: Idiopatska epiretinalna membrana (IEM) je fibrocelularna, nevaskularna proliferacija koja se razvija na površini unutarnje granične membrane mrežnice. Cilj operacije je optimizacija vidne oštine, smanjenje metamorfopsije i uspostavljanje binokularnosti ako je ista bila narušena prije operacije. Svrha ovog istraživanja je procjena utjecaja različitih intraokularnih tamponada na kvalitetu života povezanu s vidom nakon operacije IEM i ljuštenja epiretinalne membrane.

METODE: U ovo randomizirano, kontrolirano i prospektivno istraživanje uključeno je 90 pacijenata kojima je učinjena pars plana vitrektomija (PPV) zbog dijagnosticirane IEM na Klinici za očne bolesti, Kliničkog bolničkog centra Zagreb u razdoblju od rujna 2021. do ožujka 2023. Nakon zadovoljenja uključujućih kriterija, pacijenti su razvrstani u skupinu gdje je za tamponadu korišten zrak (zrak) ili u skupinu gdje je korištena balansirana otopina (eng. balanced salt solution – BSS). U svaku skupinu je nasumično razvrstano 45 pacijenata. Podatci koji su prikupljeni preoperativno, jedan mjesec i šest mjeseci nakon operacije jesu: upitnik kvalitete života povezan s vidnom funkcijom (eng. visual-related quality of life – VRQOL), najbolje korigirana vidna oština (best corrected visual acuity – BCVA), intraokularni tlak (IOT), metamorfopsija, kontrastna osjetljivost (eng. contrast sensitivity – CS) i centralna makularna debljina (central macular thickness – CMT). Sve statističke analize učinjene su koristeći IBM SPSS Statistic, verziju 23.0. Najbolje korigirana vidna oština, intraokularni tlak, razina metamorfopsije, kontrastna osjetljivost, centralna makularna debljina i svaka podljestvica VRQOL upitnika uspoređeni su između skupina zrak i BSS u sve tri vremenske točke koristeći parni t-test. Srednje vrijednosti uspoređene su između dvije skupine, zrak i BSS, koristeći t-test za nezavisne uzorke. P-vrijednost <0,05 smatrala se statistički značajnom.

REZULTATI: Od 92 pacijenta, samo ih je 90 uključeno u istraživanje (45 u skupini zrak i 45 u skupini BSS), 1 je pacijent imao vitrealno krvarenje nakon prvog tjedna, a jedan pacijent se dobrovoljno povukao iz istraživanja. Usporedba predoperativnih podataka pokazala je da nema statistički značajne razlike između dvije skupine. Šest mjeseci nakon operacije vidljivo je statistički značajno poboljšanje VRQOL ($p < 0.001$), BCVA ($p < 0.001$), CMT ($p < 0.001$), CS

($p < 0.001$) i metamorfopsije ($p < 0.001$) u usporedbi s preoperativnim podacima, bez statistički značajne razlike između skupina zrak I BSS.

ZAKLJUČAK: Uklanjanje IEM značajno poboljšava vidnu funkciju i kvalitetu života povezanu s vidom. Unatoč poboljšanju, naše istraživanje nije pokazalo postoperativnu razliku u korištenju tamponade zrakom ili BSS-om. Sukladno tome, tamponada zrakom ne pokazuje dodatnu prednost nad tamponadom BSS-om te se ne nameće kao obavezan izbor tamponade u operaciji idiopatske epiretinalne membrane.

Ključne riječi: Idiopatska epiretinalna membrana, intraokularna tamponada, pars plana vitrektomija, kvaliteta života povezana s vidom

9. ABSTRACT IN ENGLISH

Evaluation of vision-related quality of life in patients after vitrectomy following idiopathic epiretinal membrane

Gentian Bajraktari, 2023.

Background: To evaluate the impact of different intraocular tamponades on the vision-related quality of life (VRQOL) after idiopathic epiretinal membrane (IEM) surgery with epiretinal membrane peeling.

Methods: We prospectively enrolled 90 patients diagnosed with IEM who underwent pars plana vitrectomy (PPV). Patients were consecutively assigned to either the air tamponade (air) group (45 patients) or the balanced salt solutions (BSS) tamponade group (45 patients). The following data were collected before and after surgery and compared between two groups: VRQOL, best corrected visual acuity (BCVA), intraocular pressure (IOP), metamorphopsia, contrast sensitivity (CS), and central macular thickness (CMT). The BCVA, IOP, CMT, CS, metamorphopsia score, each VFQ-25 subscale, and the composite scores have been compared between each pair of three-time points by using a paired sample t-test. Mean difference values have been compared between the two groups, the air group and the BSS group, by using an independent t-test. P-value < 0.05 was considered statistically significant.

Results: PPV was performed in 90 eyes. At baseline, there were no significant differences between the two groups. At 6 months postoperatively, VRQOL ($p < 0.001$), BCVA ($p < 0.001$), CMT ($p < 0.001$), CS ($p < 0.001$), and metamorphopsia ($p < 0.001$) improved significantly in comparison to baseline, without significant differences between the air tamponade and BSS groups.

Conclusion: Removing IEM significantly improved visual function and VRQOL. Despite improvements, our study showed no difference postoperatively whether air or BSS tamponade was used during surgery. As a result, air tamponade may not be a mandatory treatment for IEM surgery and provides no additional advantage compared with BSS tamponade.

Keywords: Idiopathic epiretinal membrane, intraocular tamponade, pars plana vitrectomy, vision-related quality of life

10. REFERENCES

1. Machemer R. The surgical removal of epiretinal macular membranes (macular puckers). *Klin Monbl Augenheilkd.* 1978;173(1):36-42.
2. Bouwens MD, Van Meurs JC. Sine Amsler Charts: a new method for the follow-up of metamorphopsia in patients undergoing macular pucker surgery. *Graefes Arch Clin Exp Ophthalmol.* 2003;241(2):89-93.
3. Mangione CM, Lee PP, Gutierrez PR, Spritzer K, Berry S, Hays RD. National Eye Institute Visual Function Questionnaire Field Test Investigators. Development of the 25-item National Eye Institute Visual Function Questionnaire. *Arch Ophthalmol.* 2001;119(7):1050-8.
4. Cusick M, SanGiovanni JP, Chew EY, Csaky KG, Hall-Shimel K, Reed GF, et al. Central visual function and the NEI-VFQ-25 near and distance activities subscale scores in people with type 1 and 2 diabetes. *Am J Ophthalmol.* 2005;139(6):1042-50.
5. Berdeaux GH, Nordmann JP, Colin E, Arnould B. Vision-related quality of life in patients suffering from age-related macular degeneration. *Am J Ophthalmol.* 2005;139(2):271-9.
6. Cahill MT, Banks AD, Stinnett SS, Toth CA. Vision-related quality of life in patients with bilateral severe age-related macular degeneration. *Ophthalmology.* 2005;112(1):152-8.
7. Cahill MT, Stinnett SS, Banks AD, Freedman SF, Toth CA. Quality of life after macular translocation with 360 degrees peripheral retinectomy for age-related macular degeneration. *Ophthalmology.* 2005;112(1):144-51.
8. Tranos PG, Ghazi-Nouri SM, Rubin GS, Adams ZC, Charteris DG. Visual function and subjective perception of visual ability after macular hole surgery. *Am J Ophthalmol.* 2004;138(6):995-1002.
9. Kymes SM, Walline JJ, Zadnik K, Gordon MO; Collaborative Longitudinal Evaluation of Keratoconus study group. Quality of life in keratoconus. *Am J Ophthalmol.* 2004;138(4):527-35.
10. Okamoto F, Okamoto Y, Fukuda S, Hiraoka T, Oshika T. Vision-related quality of life and visual function following vitrectomy for proliferative diabetic retinopathy. *Am J Ophthalmol.* 2008;145(6):1031-36.
11. Okamoto F, Okamoto Y, Hiraoka T, Oshika T. Vision-related quality of life and visual function after retinal detachment surgery. *Am J Ophthalmol.* 2008;146(1):85-90.

12. Hyman LG, Komaroff E, Heijl A, Bengtsson B, Leske MC; Early Manifest Glaucoma Trial Group. Treatment and vision-related quality of life in the early manifest glaucoma trial. *Ophthalmology*. 2005;112(9):1505-13.
13. Bovey EH, Uffer S. Tearing and folding of the retinal internal limiting membrane associated with macular epiretinal membrane. *Retina*. 2008;28(3):433-40.
14. Perkins ES, Davson H. Human eye. In *Encyclopaedia Britannica* [internet]. Chicago (IL): Encyclopaedia Britannica; c2023 [updated 2023 Apr 19; cited 2023 May 24]. Available from: <https://www.britannica.com/science/human-eye>.
15. da Silva RA, Roda VMP, Matsuda M, Siqueira PV, Lustoza-Costa GJ, Wu DC, et al. Cellular components of the idiopathic epiretinal membrane. *Graefes Arch Clin Exp Ophthalmol*. 2022;260(5):1435-44.
16. Mitchell P, Smith W, Chey T, Wang JJ, Chang A. Prevalence and associations of epiretinal membranes. The Blue Mountains Eye Study, Australia. *Ophthalmology*. 1997;104(6):1033-40.
17. Klein R, Klein BE, Wang Q, Moss SE. The epidemiology of epiretinal membranes. *Trans Am Ophthalmol Soc*. 1994;92:403-25.
18. Fraser-Bell S, Guzowski M, Rohtchina E, Wang JJ, Mitchell P. Five-year cumulative incidence and progression of epiretinal membranes: the Blue Mountains Eye Study. *Ophthalmology*. 2003;110(1):34-40.
19. Meuer SM, Myers CE, Klein BE, Swift MK, Huang Y, Gangaputra S, et al. The epidemiology of vitreoretinal interface abnormalities as detected by spectral-domain optical coherence tomography: the beaver dam eye study. *Ophthalmology*. 2015;122(4):787-95.
20. Xiao W, Chen X, Yan W, Zhu Z, He M. Prevalence and risk factors of epiretinal membranes: a systematic review and meta-analysis of population-based studies. *BMJ Open*. 2017;7(9):e014644.
21. Aung KZ, Makeyeva G, Adams MK, Chong EW, Busija L, Giles GG, et al. The prevalence and risk factors of epiretinal membranes: the Melbourne Collaborative Cohort Study. *Retina*. 2013;33(5):1026-34.
22. Fraser-Bell S, Ying-Lai M, Klein R, Varma R; Los Angeles Latino Eye Study. Prevalence and associations of epiretinal membranes in latinos: the Los Angeles Latino Eye Study. *Invest Ophthalmol Vis Sci*. 2004;45(6):1732-6.

23. Koh V, Cheung CY, Wong WL, Cheung CM, Wang JJ, Mitchell P, et al. Prevalence and risk factors of epiretinal membrane in Asian Indians. *Invest Ophthalmol Vis Sci.* 2012;53(2):1018-22.
24. Kawasaki R, Wang JJ, Mitchell P, Aung T, Saw SM, Wong TY, et al. Racial difference in the prevalence of epiretinal membrane between Caucasians and Asians. *Br J Ophthalmol.* 2008;92(10):1320-4.
25. Cheung N, Tan SP, Lee SY, Cheung GCM, Tan G, Kumar N, Cheng CY, et al. Prevalence and risk factors for epiretinal membrane: the Singapore Epidemiology of Eye Disease study. *Br J Ophthalmol.* 2017;101(3):371-6.
26. hu XF, Peng JJ, Zou HD, Fu J, Wang WW, Xu X, et al. Prevalence and risk factors of idiopathic epiretinal membranes in Beixinjing blocks, Shanghai, China. *PLoS One.* 2012;7(12):e51445.
27. You Q, Xu L, Jonas JB. Prevalence and associations of epiretinal membranes in adult Chinese: the Beijing eye study. *Eye.* 2008;22(7):874-9.
28. Duan XR, Liang YB, Friedman DS, Sun LP, Wei WB, Wang JJ, et al. Prevalence and associations of epiretinal membranes in a rural Chinese adult population: the Handan Eye Study. *Invest Ophthalmol Vis Sci.* 2009;50(5):2018-23.
29. Ye H, Zhang Q, Liu X, Cai X, Yu W, Yu S, et al. Prevalence and associations of epiretinal membrane in an elderly urban Chinese population in China: the Jiangning Eye Study. *Br J Ophthalmol.* 2015;99(12):1594-7.
30. Zhu XB, Yang MC, Wang YX, Qian W, Yan YN, Yang JY, et al. Prevalence and Risk Factors of Epiretinal Membranes in a Chinese Population: The Kailuan Eye Study. *Invest Ophthalmol Vis Sci.* 2020;61(11):37.
31. Ye H, Zhang Q, Liu X, Cai X, Yu W, Yu S, et al. Prevalence and associations of epiretinal membrane in an elderly urban Chinese population in China: the Jiangning Eye Study. *Br J Ophthalmol.* 2015;99(12):1594-7.
32. Ng CH, Cheung N, Wang JJ, Islam AF, Kawasaki R, Meuer SM, et al. Prevalence and risk factors for epiretinal membranes in a multi-ethnic United States population. *Ophthalmology.* 2011;118(4):694-9.

33. Kawasaki R, Wang JJ, Sato H, Mitchell P, Kato T, Kawata S, et al. Prevalence and associations of epiretinal membranes in an adult Japanese population: the Funagata study. *Eye*. 2009;23(5):1045-51.
34. Wang SZ, Tong QH, Wang HY, Lu QK, Xu YF. The association between smoking and epiretinal membrane. *Sci Rep*. 2016;6(1):1-7.
35. Stevenson W, Prospero Ponce CM, Agarwal DR, Gelman R, Christoforidis JB. Epiretinal membrane: optical coherence tomography-based diagnosis and classification. *Clin Ophthalmol*. 2016:527-34.
36. Hirokawa H, Jalkh AE, Takahashi M, Takahashi M, Trempe CL, Schepens CL. Role of the vitreous in idiopathic preretinal macular fibrosis. *Am J Ophthalmol*. 1986;101(2):166-9.
37. Wiznia RA. Posterior vitreous detachment and idiopathic preretinal macular gliosis. *Am J Ophthalmol*. 1986;102(2):196-8.
38. Fung AT, Galvin J, Tran T. Epiretinal membrane: A review. *Clin Exp Ophthalmol*. 2021;49(3):289-308.
39. Fong CS, Mitchell P, Rohtchina E, Hong T, de Loryn T, Wang JJ. Incidence and progression of epiretinal membranes in eyes after cataract surgery. *Am J Ophthalmol*. 2013;156(2):312-8.
40. Tsotridou E, Loukovitis E, Zapsalis K, Pentara I, Asteriadis S, Tranos P, et al. A review of last decade developments on epiretinal membrane pathogenesis. *Med Hypothesis Discov Innov Ophthalmol*. 2020;9(2):91.
41. Foos RY. Vitreoretinal juncture—simple epiretinal membranes. *Albrecht Von Graefes Arch Klin Exp Ophthalmol*. 1974;189(4):231-50.
42. Snead DR, James S, Snead MP. Pathological changes in the vitreoretinal junction 1: epiretinal membrane formation. *Eye*. 2008;22(10):1310-7.
43. Bu SC, Kuijjer R, van der Worp RJ, Huiskamp EA, De Lavalette VW, Li XR, et al. Glial cells and collagens in epiretinal membranes associated with idiopathic macular holes. *Retina*. 2014;34(5):897-906.
44. Bellhorn MB, Friedman AH, Wise GN, Henkind P. Ultrastructure and clinicopathologic correlation of idiopathic preretinal macular fibrosis. *Am J Ophthalmol*. 1975;79(3):366-73.
45. Gandorfer A, Schumann R, Scheler R, Haritoglou C, Kampik A. Pores of the inner limiting membrane in flat-mounted surgical specimens. *Retina*. 2011;31(5):977-81.

46. Kampik A. Pathology of epiretinal membrane, idiopathic macular hole, and vitreomacular traction syndrome. *Retina*. 2012;32(Suppl 2):S194-8.
47. Sebag J. Die vitreoretinale Grenzfläche und ihre Rolle in der Pathogenese vitreomakulärer Erkrankungen. *Ophthalmologe*. 2015;112(1):10-9.
48. Smiddy WE, Maguire AM, Green WR, Michels RG, De La Cruz Z, Enger C, et al. Idiopathic epiretinal membranes: ultrastructural characteristics and clinicopathologic correlation. *Ophthalmology*. 1989;96(6):811-21.
49. Kampik A, Green WR, Michels RG, Nase PK. Ultrastructural features of progressive idiopathic epiretinal membrane removed by vitreous surgery. *Am J Ophthalmol*. 1980;90(6):797-809.
50. Hiscott PS, Grierson I, Trombetta CJ, Rahi AH, Marshall J, McLeod D. Retinal and epiretinal glia--an immunohistochemical study. *Br J Ophthalmol*. 1984;68(10):698-707.
51. Bringmann A, Wiedemann P. Involvement of Müller glial cells in epiretinal membrane formation. *Graefes Arch Clin Exp Ophthalmol*. 2009;247(7):865-83.
52. Hamburg A. Some investigations on the cells of the vitreous body. *Ophthalmologica*. 1959;138:81-107.
53. Kohno RI, Hata Y, Kawahara S, Kita T, Arita R, Mochizuki Y, et al. Possible contribution of hyalocytes to idiopathic epiretinal membrane formation and its contraction. *Br J Ophthalmol*. 2009;93(8):1020-6.
54. Gandorfer A, Rohleder M, Kampik A. Epiretinal pathology of vitreomacular traction syndrome. *Br J Ophthalmol*. 2002;86(8):902-9.
55. Guenther SR, Schumann RG, Hagenau F, Wolf A, Priglinger SG, Vogt D. Comparison of Surgically Excised Premacular Membranes in Eyes with Macular Pucker and Proliferative Vitreoretinopathy. *Curr Eye Res*. 2019;44(3):341-49.
56. Vogt D, Vielmuth F, Wertheimer C, Hagenau F, Guenther SR, Wolf A, et al. Premacular membranes in tissue culture. *Graefes Arch Clin Exp Ophthalmol*. 2018;256(9):1589-97.
57. Schumann RG, Gandorfer A, Kampik A, Haritoglou C. Clinicopathological correlations at the vitreoretinal interface. *Ophthalmologe*. 2015;112(1):20-8.
58. Yokota R, Hirakata A, Hayashi N, Hirota K, Rii T, Itoh Y, et al. Ultrastructural analyses of internal limiting membrane excised from highly myopic eyes with myopic traction maculopathy. *Jpn J Ophthalmol*. 2018;62(1):84-91.

59. Wertheimer C, Eibl-Lindner KH, Compera D, Kueres A, Wolf A, Docheva D, et al. A cell culture technique for human epiretinal membranes to describe cell behavior and membrane contraction in vitro. *Graefes Arch Clin Exp Ophthalmol*. 2017;255(11):2147-2155.
60. Oberstein SY, Byun J, Herrera D, Chapin EA, Fisher SK, Lewis GP. Cell proliferation in human epiretinal membranes: characterization of cell types and correlation with disease condition and duration. *Mol Vis*. 2011;17(5):1794-805.
61. Hinz B. It has to be the α v: myofibroblast integrins activate latent TGF- β 1. *Nat Med*. 2013;19(12):1567-8.
62. Jerdan JA, Pepose JS, Michels RG, Hayashi H, de Bustros S, Sebag M, et al. Proliferative vitreoretinopathy membranes. An immunohistochemical study. *Ophthalmology*. 1989;96(6):801-10.
63. Karacorlu M, Ozdemir H, Senturk F, Karacorlu SA, Uysal O. Correlation of retinal sensitivity with visual acuity and macular thickness in eyes with idiopathic epimacular membrane. *Int Ophthalmol*. 2010;30(3):285-90.
64. Hatt SR, Leske DA, Iezzi R Jr, Holmes JM. Binocular Interference vs Diplopia in Patients With Epiretinal Membrane. *JAMA Ophthalmol*. 2020;138(11):1121-27.
65. Lane C. Stereoscopic atlas of macular diseases: diagnosis and treatment. *Br J Ophthalmol*. 1988;72(9):720.
66. Govetto A, Lalane RA 3rd, Sarraf D, Figueroa MS, Hubschman JP. Insights Into Epiretinal Membranes: Presence of Ectopic Inner Foveal Layers and a New Optical Coherence Tomography Staging Scheme. *Am J Ophthalmol*. 2017;175:99-113.
67. Konidaris V, Androudi S, Alexandridis A, Dastiridou A, Brazitikos P. Optical coherence tomography-guided classification of epiretinal membranes. *Int Ophthalmol*. 2015;35(4):495-501.
68. Hirokawa H, Jalkh AE, Takahashi M, Takahashi M, Trempe CL, Schepens CL. Role of the vitreous in idiopathic preretinal macular fibrosis. *Am J Ophthalmol*. 1986;101(2):166-9.
69. Mastropasqua R, D'Aloisio R, Viggiano P, Borrelli E, Iafigliola C, Di Nicola M, et al. Early retinal flow changes after vitreoretinal surgery in idiopathic epiretinal membrane using swept source optical coherence tomography angiography. *J Clin Med*. 2019;8(12):2067.
70. Mao J, Lao J, Liu C, Zhang C, Chen Y, Tao J, et al. A study analyzing macular microvasculature features after vitrectomy using OCT angiography in patients with idiopathic macular epiretinal membrane. *BMC Ophthalmol*. 2020;20(1):165.

71. Kim YJ, Kim S, Lee JY, Kim JG, Yoon YH. Macular capillary plexuses after epiretinal membrane surgery: an optical coherence tomography angiography study. *Br J Ophthalmol*. 2018;102(8):1086-91.
72. Moschos M, Apostolopoulos M, Ladas J, Theodossiadis P, Malias J, Moschos M, et al. Assessment of macular function by multifocal electroretinogram before and after epimacular membrane surgery. *Retina*. 2001;21(6):590-5.
73. Tari SR, Vidne-Hay O, Greenstein VC, Barile GR, Hood DC, Chang S. Functional and structural measurements for the assessment of internal limiting membrane peeling in idiopathic macular pucker. *Retina*. 2007;27(5):567-72.
74. Ruberto G, Parisi V, Vandelli G, Falcione A, Manzoni F, Riva I, et al. Surgery for Idiopathic Epimacular Membrane: Morpho-Functional Outcomes Based on the Preoperative Macular Integrity of the Photoreceptor Junction. A Prospective Pilot Study. *Adv Ther*. 2020;37(1):566-77.
75. Parisi V, Coppè AM, Gallinaro G, Stirpe M. Assessment of macular function by focal electroretinogram and pattern electroretinogram before and after epimacular membrane surgery. *Retina*. 2007;27(3):312-20.
76. Lubiński W, Gosławski W, Krzystolik K, Mularczyk M, Kuprjanowicz L, Post M. Assessment of macular function, structure and predictive value of pattern electroretinogram parameters for postoperative visual acuity in patients with idiopathic epimacular membrane. *Doc Ophthalmol*. 2016;133(1):21-30.
77. Shimada Y, Sakurai S, Naito K, Sugino T, Kojima Y, Hori K, Horiguchi M. Multifocal electroretinogram and optical coherent tomography: prediction of visual outcome after epiretinal membrane removal. *Clin Exp Optom*. 2011;94(3):296-301.
78. Lo YC, Lin KH, Bair H, Sheu WH, Chang CS, Shen YC, et al. Epiretinal Membrane Detection at the Ophthalmologist Level using Deep Learning of Optical Coherence Tomography. *Sci Rep*. 2020;10(1):8424.
79. Sonobe T, Tabuchi H, Ohsugi H, Masumoto H, Ishitobi N, Morita S, et al. Comparison between support vector machine and deep learning, machine-learning technologies for detecting epiretinal membrane using 3D-OCT. *Int Ophthalmol*. 2019;39(8):1871-77.

80. Folk JC, Adelman RA, Flaxel CJ, Hyman L, Pulido JS, Olsen TW. Idiopathic Epiretinal Membrane and Vitreomacular Traction Preferred Practice Pattern(®) Guidelines. *Ophthalmology*. 2016;123(1):152-81.
81. Kasner D. Vitrectomy: a new approach to management of vitreous. *Highlights Ophthalmol*. 1969;11:304.
82. Machemer R, Buettner H, Norton EW, Parel JM. Vitrectomy: a pars plana approach. *Trans Am Acad Ophthalmol Otolaryngol*. 1971;75(4):813-20.
83. Machemer R, Parel JM, Norton EW. Vitrectomy: a pars plana approach. Technical improvements and further results. *Trans Am Acad Ophthalmol Otolaryngol*. 1972;76(2):462-6.
84. Machemer R, Hickingbotham D. The three-port microcannular system for closed vitrectomy. *Am J Ophthalmol*. 1985;100(4):590-2.
85. de Juan E Jr, Machemer R, Charles ST, Hirose T, Tasman WS, Trese MT. Surgery for stage 5 retinopathy of prematurity. *Arch Ophthalmol*. 1987;105(1):21.
86. Peyman GA. A pneumovitrector for the diagnostic biopsy of the vitreous. *Ophthalmic Surg Lasers*. 1996;27(3):246-7.
87. Fujii GY, De Juan E Jr, Humayun MS, Pieramici DJ, Chang TS, Awh C, et al. A new 25-gauge instrument system for transconjunctival sutureless vitrectomy surgery. *Ophthalmology*. 2002;109(10):1807-12.
88. Oshima Y, Wakabayashi T, Sato T, Ohji M, Tano Y. A 27-gauge instrument system for transconjunctival sutureless microincision vitrectomy surgery. *Ophthalmology*. 2010;117(1):93-102.
89. Villegas VM, Murray TG. Know your retinal surgery toolbox. *Retinal Physician*. 2018;15(4):24-9.
90. Bracha P, Ciulla TA, Baumal CR. Vital Dyes in Vitreomacular Surgery. *Ophthalmic Surg Lasers Imaging Retina*. 2018;49(10):788-98.
91. Maia M, Penha F, Rodrigues EB, Príncipe A, Dib E, Meyer CH, et al. Effects of subretinal injection of patent blue and trypan blue in rabbits. *Curr Eye Res*. 2007;32(4):309-17.
92. Malerbi FK, Maia M, Farah ME, Rodrigues EB. Subretinal brilliant blue G migration during internal limiting membrane peeling. *Br J Ophthalmol*. 2009;93(12):1687.
93. Stein JD, Zacks DN, Grossman D, Grabe H, Johnson MW, Sloan FA. Adverse events after pars plana vitrectomy among medicare beneficiaries. *Arch Ophthalmol*. 2009;127(12):1656-63.

94. Day S, Grossman DS, Mruthyunjaya P, Sloan FA, Lee PP. One-year outcomes after retinal detachment surgery among medicare beneficiaries. *Am J Ophthalmol.* 2010;150(3):338-45.
95. Chang S. LXII Edward Jackson lecture: open angle glaucoma after vitrectomy. *Am J Ophthalmol.* 2006;141(6):1033-43.
96. Wong JG, Sachdev N, Beaumont PE, Chang AA. Visual outcomes following vitrectomy and peeling of epiretinal membrane. *Clin Exp Ophthalmol.* 2005;33(4):373-8.
97. Pournaras CJ, Emarah A, Petropoulos IK. Idiopathic macular epiretinal membrane surgery and ILM peeling: anatomical and functional outcomes. *Semin Ophthalmol.* 2011;26(2):42-6.
98. Moisseiev E, Davidovitch Z, Kinori M, Loewenstein A, Moisseiev J, Barak A. Vitrectomy for idiopathic epiretinal membrane in elderly patients: surgical outcomes and visual prognosis. *Curr Eye Res.* 2012;37(1):50-4.
99. Kim HJ, Kang JW, Chung H, Kim HC. Correlation of foveal photoreceptor integrity with visual outcome in idiopathic epiretinal membrane. *Curr Eye Res.* 2014;39(6):626-33.
100. Guyatt GH, Feeny DH, Patrick DL. Measuring health-related quality of life. *Ann. Intern. Med.* 1993;118(8):622-9.
101. Sahel JA, Bandello F, Augustin A, Maurel F, Negrini C, Berdeaux GH, et al. Health-related quality of life and utility in patients with age-related macular degeneration. *Arch Ophthalmol.* 2007;125(7):945-51.
102. Margolis MK, Coyne K, Kennedy-Martin T, Baker T, Schein O, Revicki DA. Vision-specific instruments for the assessment of health-related quality of life and visual functioning: a literature review. *Pharmacoeconomics.* 2002;20(12):791-812.
103. Mangione CM, Gutierrez PR, Lowe G, Orav EJ, Seddon JM. Influence of age-related maculopathy on visual functioning and health-related quality of life. *Am J Ophthalmol.* 1999;128(1):45-53.
104. West SK, Munoz B, Rubin GS, Schein OD, Bandeen-Roche K, Zeger S, et al. Function and visual impairment in a population-based study of older adults. The SEE project. Salisbury Eye Evaluation. *Invest Ophthalmol Vis Sci.* 1997;38(1):72-82.
105. Scott IU, Smiddy WE, Schiffman J, Feuer WJ, Pappas CJ. Quality of life of low-vision patients and the impact of low-vision services. *Am J Ophthalmol.* 1999;128(1):54-62.
106. Wood J, Chaparro A, Anstey K, Lacherez P, Chidgey A, Eisemann J, et al. Simulated visual impairment leads to cognitive slowing in older adults. *Optom Vis Sci.* 2010;87(12):1037-43.

107. O'Donnell C. The greatest generation meets its greatest challenge: vision loss and depression in older adults. *J. vis. impair. blind.* 2005;99(4):197-208.
108. Massof RW, Rubin GS. Visual function assessment questionnaires. *Surv Ophthalmol.* 2001;45(6):531-48.
109. Lundström M, Pesudovs K. Questionnaires for measuring cataract surgery outcomes. *J Cataract Refract Surg.* 2011;37(5):945-59.
110. Scott IU, Smiddy WE, Schiffman J, Feuer WJ, Pappas CJ. Quality of life of low-vision patients and the impact of low-vision services. *Am J Ophthalmol.* 1999;128(1):54-62.
111. Lešin Gaćina D, Škegro B, Jandroković S, Škegro I, Bešlić I, Bukvić M. Psychometric properties of the Croatian version of the 25-item National Eye Institute Visual Function Questionnaire (NEI VFQ-25). *Int Ophthalmol.* 2021;41(12):4025-36.
112. Akpolat C, Demir M, Cevher S, Ozturk SZ, Yesiltas S. The impact of phacoemulsification surgery on vision-related quality of life in senile cataract patients. *Ther Adv Ophthalmol.* 2022;14:25158414211063293.
113. Zhang Q, Zhou W, Song D, Xie Y, Lin H, Liang Y, et al. Vision-related quality of life in patients with glaucoma: the role of illness perceptions. *Health Qual Life Outcomes.* 2022;20(1):78.
114. Cahill MT, Banks AD, Stinnett SS, Toth CA. Vision-related quality of life in patients with bilateral severe age-related macular degeneration. *Ophthalmology.* 2005;112(1):152-8.
115. Fukuda S, Okamoto F, Yuasa M, Kunikata T, Okamoto Y, Hiraoka T, et al. Vision-related quality of life and visual function in patients undergoing vitrectomy, gas tamponade and cataract surgery for macular hole. *Br J Ophthalmol.* 2009;93(12):1595-9.
116. Hirneiss C, Neubauer AS, Gass CA, Reiniger IW, Priglinger SG, Kampik A, et al. Visual quality of life after macular hole surgery: outcome and predictive factors. *Br J Ophthalmol.* 2007;91(4):481-4.
117. an JCK, Nguyen V, Fenwick E, Ferdi A, Dinh A, Watson SL. Vision-Related Quality of Life in Keratoconus: A Save Sight Keratoconus Registry Study. *Cornea.* 2019;38(5):600-4.
118. Miljanović B, Dana R, Sullivan DA, Schaumberg DA. Impact of dry eye syndrome on vision-related quality of life. *Am J Ophthalmol.* 2007;143(3):409-15.
119. Tranos PG, Topouzis F, Stangos NT, Dimitrakos S, Economidis P, Harris M, et al. Effect of laser photocoagulation treatment for diabetic macular oedema on patient's vision-related quality of life. *Curr Eye Res.* 2004;29(1):41-9.

120. Chabot G, Bourgault S, Cinq-Mars B, Tourville É, Caissie M. Effect of air and sulfur hexafluoride (SF₆) tamponade on visual acuity after epiretinal membrane surgery: a pilot study. *Can J Ophthalmol*. 2017;52(3):269-72.
121. Chua PY, Sandinha MT, Steel DH. Idiopathic epiretinal membrane: progression and timing of surgery. *Eye (Lond)*. 2022;36(3):495-503.
122. Luu KY, Koenigsaecker T, Yazdanyar A, Mukkamala L, Durbin-Johnson BP, Morse LS, et al. Long-term natural history of idiopathic epiretinal membranes with good visual acuity. *Eye*. 2019;33(5):714-23.
123. Chen X, Klein KA, Shah CP, Heier JS. Progression to Surgery for Patients With Idiopathic Epiretinal Membranes and Good Vision. *Ophthalmic Surg Lasers Imaging Retina*. 2018;49(10):18-22.
124. Kofod M, Christensen UC, la Cour M. Deferral of surgery for epiretinal membranes: Is it safe? Results of a randomised controlled trial. *Br J Ophthalmol*. 2016;100(5):688-92.
125. Chylack LT Jr, Wolfe JK, Singer DM, Leske MC, Bullimore MA, Bailey IL, et al. The Lens Opacities Classification System III. The Longitudinal Study of Cataract Study Group. *Arch Ophthalmol*. 1993;111(6):831-6.
126. Rosser DA, Cousens SN, Murdoch IE, Fitzke FW, Laidlaw DA. How sensitive to clinical change are ETDRS logMAR visual acuity measurements? *Invest Ophthalmol Vis Sci*. 2003;44(8):3278-81.
127. Rosentreter A, Hoerster R, Schick T, Eter N, Dietlein TS, Fauser S. Rebound tonometry after vitreoretinal surgery. *Ophthalmologe*. 2015;112(11):917-22.
128. Arden GB. The importance of measuring contrast sensitivity in cases of visual disturbance. *Br J Ophthalmol*. 1978;62(4):198-209.
129. Massin P, Allouch C, Haouchine B, Metge F, Paques M, Tangui L, et al. Optical coherence tomography of idiopathic macular epiretinal membranes before and after surgery. *Am J Ophthalmol*. 2000;130(6):732-9.
130. Leitritz MA, Ziemssen F, Voykov B, Dimopoulos S, Zobor D, Bartz-Schmidt KU, et al. Early postoperative changes of the foveal surface in epiretinal membranes: comparison of 23-gauge macular surgery with air vs. balanced salt solution. *Graefes Arch Clin Exp Ophthalmol*. 2014;252(8):1213-9.

131. Sato T, Emi K, Bando H, Ikeda T. Retrospective comparisons of vitrectomy with and without air tamponade to repair lamellar macular hole. *Ophthalmic Surg Lasers Imaging Retina*. 2015;46(1):38-43.
132. Leisser C, Hirnschall N, Döllner B, Varsits R, Ullrich M, Kefer K, et al. Effect of Air Tamponade on Postoperative Visual Acuity and Intraretinal Cystoid Changes after Peeling of Idiopathic Epiretinal Membranes in Pseudophakic Patients. *Ophthalmologica*. 2020;243(1):37-42.
133. Jang K, Hwang DD, Ahn J, Son G, Park JI, Sohn J. Comparison of the effect of air tamponade versus no tamponade after pars plana vitrectomy for idiopathic epiretinal membrane. *Sci Rep*. 2021;11(1):5082.
134. Sayegh RG, Georgopoulos M, Geitzenauer W, Simader C, Kiss C, Schmidt-Erfurth U. High-resolution optical coherence tomography after surgery for vitreomacular traction: a 2-year follow-up. *Ophthalmology*. 2010;117(10):2010-7.
135. Thompson JT. Epiretinal membrane removal in eyes with good visual acuities. *Retina*. 2005;25(7):875-82.
136. Ghazi-Nouri SM, Tranos PG, Rubin GS, Adams ZC, Charteris DG. Visual function and quality of life following vitrectomy and epiretinal membrane peel surgery. *Br J Ophthalmol*. 2006;90(5):559-62.
137. Almony A, Nudleman E, Shah GK, Blinder KJ, Elliott DB, Mitra RA, et al. Techniques, rationale, and outcomes of internal limiting membrane peeling. *Retina*. 2012;32(5):877-91.
138. Khanna RK, Pichard T, Pasco J, Dorvault M, Cook AR, Pisella PJ, et al. Monocular and binocular visual parameters associated to vision-related quality of life in patients with epiretinal membrane: a prospective cohort. *Graefes Arch Clin Exp Ophthalmol*. 2021;259(7):1723-30.
139. Chang S. LXII Edward Jackson lecture: open angle glaucoma after vitrectomy. *Am J Ophthalmol*. 2006 ;141(6):1033-43.
140. Luk FO, Kwok AK, Lai TY, Lam DS. Presence of crystalline lens as a protective factor for the late development of open angle glaucoma after vitrectomy. *Retina*. 2009;29(2):218-24.
141. Chen L, Liu M, Xie AM, Liu Y. A study on change of macular retinal thickness and its relationship with vision before and after operation to idiopathic macular epiretinal membranes. *Int J Clin Exp Med*. 2015;8(10):18571-80.

142. Keane PA, Patel PJ, Ouyang Y, Chen FK, Ikeji F, Walsh AC, et al. Effects of retinal morphology on contrast sensitivity and reading ability in neovascular age-related macular degeneration. *Invest Ophthalmol Vis Sci.* 2010;51(11):5431-7.
143. Ortiz C, Jiménez JR, Pérez-Ocón F, Castro JJ, González-Anera R. Retinal-image quality and contrast-sensitivity function in age-related macular degeneration. *Curr Eye Res.* 2010;35(8):757-61.
144. Okamoto F, Sugiura Y, Okamoto Y, Hiraoka T, Oshika T. Changes in contrast sensitivity after surgery for macula-on rhegmatogenous retinal detachment. *Am J Ophthalmol.* 2013;156(4):667-72.
145. Dormegny L, Foch M, Messerlin A, Bourcier T, Sauer A, Gaucher D. Binocular visual function improvement after pars plana vitrectomy for epiretinal membrane. *Acta Ophthalmol.* 2023 Apr 24. doi: 10.1111/aos.15669. [Epub ahead of print].
146. Matsuoka Y, Tanito M, Takai Y, Koyama Y, Nonoyama S, Ohira A. Visual function and vision-related quality of life after vitrectomy for epiretinal membranes: a 12-month follow-up study. *Invest Ophthalmol Vis Sci.* 2012;53(6):3054-8.
147. Okamoto F, Okamoto Y, Hiraoka T, Oshika T. Effect of vitrectomy for epiretinal membrane on visual function and vision-related quality of life. *Am J Ophthalmol.* 2009;147(5):869-74.
148. Arndt C, Rebollo O, Séguinet S, Debruyne P, Caputo G. Quantification of metamorphopsia in patients with epiretinal membranes before and after surgery. *Graefes Arch Clin Exp Ophthalmol.* 2007;245(8):1123-9.
149. Okamoto F, Okamoto Y, Fukuda S, Hiraoka T, Oshika T. Vision-related quality of life and visual function after vitrectomy for various vitreoretinal disorders. *Invest Ophthalmol Vis Sci.* 2010;51(2):744-51.
150. Nakashizuka H, Kitagawa Y, Wakatsuki Y, Tanaka K, Furuya K, Hattori T, et al. Prospective study of vitrectomy for epiretinal membranes in patients with good best-corrected visual acuity. *BMC Ophthalmol.* 2019;19(1):183.
151. Pesin SR, Olk RJ, Grand MG, Boniuk I, Arribas NP, Thomas MA, et al. Vitrectomy for premacular fibroplasia. Prognostic factors, long-term follow-up, and time course of visual improvement. *Ophthalmology.* 1991;98(7):1109-14.

152. Ware JE Jr, Sherbourne CD. The MOS 36-item short-form health survey (SF-36). I. Conceptual framework and item selection. *Med Care*. 1992;30(6):473-83.

11. CURRICULUM VITAE

Gentian Bajraktari was born on August 1st, 1986 in Gjakova, Kosova. He graduated from the Medical Faculty, the University of Prishtina in 2011. He completed his residency in Ophthalmology at the University Clinical Center of Kosova, Kosova, 2019.

He is currently working as a specialist in ophthalmology at the University Clinical Center of Kosovo in Prishtina, Clinic of Ophthalmology. He has actively participated in several local, regional, and international conferences, and published an article and several abstracts related to PHD thesis.